

Oculopharyngodistal myopathy in three unrelated Korean patients: Early distal limb weakness is a characteristic finding in oculopharyngodistal myopathy

¹Sun-Young Kim, ²Jeong-Keun Lim, ³Young-Eun Park, ^{4,5}Chang-Hoon Lee, ⁵Hyang-Sook Kim, ^{4,5}Dae-Seong Kim

¹Department of Neurology, Ulsan University Hospital, College of Medicine, Ulsan; ²Department of Neurology, Kei-Myung University Hospital, Daegu; ³Department of Neurology and ⁴Pathology, ⁵Medical Research Institute, Pusan National University School of Medicine, Busan, Korea

Abstract

Objectives: To determine the clinical characteristics of Korean patients with sporadic oculopharyngodistal myopathy. **Methods:** Three consecutive unrelated Korean patients with sporadic oculopharyngodistal myopathy participated in this study. Stepwise approaches were performed including careful clinical examination, electrophysiological study, pathology evaluation and genetic study. The literature on oculopharyngodistal myopathy was reviewed. **Results:** Clinically, our patients showed consistent features of initial distal limb weakness with variable ophthalmoplegia, bulbar weakness or proximal weakness. All the patients showed rimmed vacuoles and myopathic changes.

Conclusion: Through the literature review and this study, we believe that initial distal limb weakness is a characteristic finding in patients with oculopharyngodistal myopathy in some ethnic groups.

INTRODUCTION

Oculopharyngodistal myopathy (OPDM; MIM 164310) is a rare muscle disease that is inherited in both autosomal dominant (AD) and autosomal recessive (AR) manners.¹⁻³ Typical features of OPDM include late-onset progressive ptosis, external ophthalmoplegia, dysphagia, and distal muscle weakness. Myopathic changes with vacuole formation (rimmed vacuoles) have been observed in muscle biopsies.¹ Since OPDM has features that overlap markedly with oculopharyngeal muscular dystrophy (MIM 164300) such as late-onset oculobulbar weakness and rimmed vacuoles in the muscle biopsy, it is not clear whether OPDM is a distinct disease entity or a variant of oculopharyngeal muscular dystrophy.³ However, previous studies using genetic or electron microscopy examinations showed that OPDM is a distinct disease with unknown genetic defect.^{2,4}

In this paper, we analyzed the clinical, pathological, and genetic features of three unrelated Korean OPDM patients with sporadic onset. We also briefly reviewed the clinical and pathological features of our patients and compared them with previously reported cases of OPDM.

METHODS

Three Korean patients with OPDM were included in the study. All of them were seen, evaluated, and followed by one of the authors. The clinical analysis consisted of a detailed history taking focusing on developmental and familial histories, and the onset of ptosis, dysphagia, dysarthria, and distal muscle weakness. A physical examination was performed including a standard neurological examination. For the identification of distribution and degree of muscle weakness, muscle power examination was performed in all skeletal muscle groups involving major joint movement and was graded according to the modified Medical Research Council (MRC) grade. Complete blood counts, erythrocyte sedimentation rates, liver, renal, and thyroid function tests, blood glucose, serum electrolyte, creatine kinase, and lactate/pyruvate levels, electrocardiograms, and chest roentgenogram were obtained for all patients.

Muscle biopsy was performed on mildly affected skeletal muscles, snap frozen and stored at -70°C until used. Serial 8- μ m frozen sections were stained with hematoxylin and eosin, Gomori trichrome, and a battery of histochemical methods, including ATPase at pH 9.4, 4.6 and 4.3, NADH-

tetrazolium reductase, succinate dehydrogenase (SDH), cytochrome *c* oxidase (COX), periodic acid Schiff, acid phosphatase and oil red O. For electron microscopy, the samples were fixed with 2% glutaraldehyde and embedded in epoxy resin. Semi-thin 1 μ m thick resin sections were stained with toluidine blue for light microscopy, and ultrathin (60-nm-thick) sections were cut with diamond knives on an ultramicrotome (REICHERT SUPERNOVA™, Leica, Germany), double stained with uranyl acetate and lead citrate, and examined under an electron microscope (GEM1200EX-2™, JEOL, Japan).

All patients provided informed consent for the DNA analysis, and this study was reviewed and approved by the Pusan National University Institutional Review Board. Genomic DNA was extracted from peripheral leukocytes as described.⁵ PCR for the amplification of exon 1 of *PABPN1* and all coding exons of *GNE* was carried out as described previously.^{6,7} The PCR composition and reaction conditions are available upon request. The PCR products were electrophoresed, stained, and sequenced directly using a BigDye terminator cycle sequencing kit (Applied Biosystems, Foster City, USA.) and 3730xl DNA analyzer (Applied Biosystems).

RESULTS

Clinical features of the patients (Table 1)

Patient 1

She was a 50-year-old lady when she first visited our clinic with progressive bilateral ptosis and swallowing difficulty. At the age of 40, she started to notice her shoes slipping due to ankle weakness. Progressive hand weakness, drooping of the upper eyelids, diplopia and swallowing difficulty followed. Finally she developed a nasal voice and severe hoarseness in her speech. She denied any family history of similar symptoms.

The neurological examination revealed weakened eye closure power and limited elevation of the soft palates bilaterally. Extraocular movement was limited completely in all six cardinal directions. Motor weakness was present in both ankles and great toes with a modified Medical Research Council (MRC) of 5-. The deep tendon reflexes were lost in all extremities.

The laboratory findings were unremarkable except for serum creatine kinase of 285 IU/L (upper normal limit: 195 IU/L). The electrophysiological evaluation showed normal nerve conduction and myopathic needle electromyographic findings

including abnormal spontaneous activity and small amplitude, short duration motor unit potentials, and rapid recruitment patterns in the deltoid, biceps and gastrocnemius muscles.

Patient 2

A 43-year-old female visited our clinic with easy fatigability, bilateral ptosis and swallowing difficulty. At the age of 39 she started to experience toe weakness, followed by drooping of the upper eyelids. Finally, she developed nasal regurgitation while swallowing and a faint, husky twiggy voice. She denied any family history of similar symptoms.

The neurological examination revealed weak eye closure and dysarthria, but the extraocular motions in all six cardinal directions were full. We also observed motor weakness with modified Medical Research Council (MRC) grade 4+ for the bilateral upper extremities, worse distally, 4 for neck flexion, and 4 for bilateral ankle and great toe dorsiflexion. The deep tendon reflexes were lost in all extremities.

The laboratory findings were unremarkable except for a serum creatine kinase level of 305 IU/L (upper normal limit; 195 IU/L). The electrophysiological evaluation showed normal nerve conduction and myopathic needle electromyographic changes.

Patient 3

The patient was 54 years old when he visited our clinic with progressive weakness and muscular wasting in his face, both hands and forearms. At the age of 52, he first noticed bilateral hand weakness. He had neither diplopia nor swallowing difficulty. He denied any family history of similar symptoms.

The neurological examination revealed mild bilateral ptosis, and weakened eye closing power, but with full eyeball movement. His buccal muscle was weak and wasted. Motor weakness was present in the hand grip with a modified MRC grade of 5-. The deep tendon reflexes were decreased in all extremities. His sensory tests revealed no abnormal findings.

The laboratory findings were unremarkable except for a serum creatine kinase level of 610 IU/L (upper normal limit; 195 IU/L). The electrophysiological evaluation showed normal nerve conduction and myopathic needle electromyographic changes.

Table 1: Summary of clinical, laboratory, electrophysiological, and pathological findings of the three study patients.

	Patient 1	Patient 2	Patient 3
Sex	Female	Female	Male
Onset age in years	40	39	52
Initial symptom	Ankle weakness	Toe weakness	Hand weakness
Duration of disease (years)	10	4	2
Muscle involvement			
Ptosis	+	+	+
Extraocular	+	-	-
Masseter	+	-	+
Facial	+	+	+
Bulbar	+	+	-
Proximal limb	-	+	-
Distal limb	+	++	+
Other neurological findings	Areflexia	Areflexia	Hyporeflexia
Creatine kinase	285	305	610
EMG	SASD MUAPs	SASD MUAPs	SASD MUAPs
Muscle biopsy	Rimmed vacuoles	Rimmed vacuoles	Rimmed vacuoles
GNE mutation	Negative	Negative	Not tested
PABPN1 mutation	Normal	Normal	Not tested

SASD MUAP: Small amplitude short duration motor unit action potential

Muscle pathology and molecular genetic study

In all patients, muscle biopsy showed the presence of scattered rimmed vacuoles in atrophic fibers. (Figure 1) On electron microscopy, no intranuclear inclusions typical of oculopharyngeal muscular dystrophy were seen in any of our patients. (Figure 2) In the molecular genetic study, no mutation was found in *PABPN1* and *GNE* in Patients 1 & 2. In Patient 3, neither *PABPN1* nor *GNE* could be sequenced due to a lack of DNA .

DISCUSSION

In 1977, Satoyoshi and Kinoshita reported on four Japanese families with an autosomal dominant hereditary myopathy characterized by slowly progressive ptosis and extraocular palsy; weakness of the masseter, facial and bulbar muscles; and distal involvement of the limbs starting at around 40 years of age or later.¹ They proposed the term oculopharyngodistal myopathy (OPDM) to distinguish the disease from oculopharyngeal muscular dystrophy. Since then,

most cases of OPDM have been reported from Japan, and the prominent distal limb weakness was considered to be a useful clinical marker for differentiating OPDM from oculopharyngeal muscular dystrophy.^{1,2,8}

However, it soon became clear that distal muscle involvement also constitutes a feature of oculopharyngeal muscular dystrophy, because several French-Canadian patients with oculopharyngeal muscular dystrophy and patients from other ethnic groups also showed distal muscle weakness.^{9,10} Furthermore, a case of hereditary inclusion body myopathy/distal myopathy with rimmed vacuoles (HIBM/DMRV) featuring facial weakness and ptosis was also reported.¹¹ Consequently, it is now widely accepted that a genetic study is important for differentiating between these closely related disorders. In oculopharyngeal muscular dystrophy, the expanded (GCG) repeat in exon 1 of *PABPN1* plays a causative role⁶, and is thought to produce the intranuclear accumulation of its transcripts.¹² *GNE*, which encodes UDP-N-acetylmannosamine kinase, is the only gene known to be associated

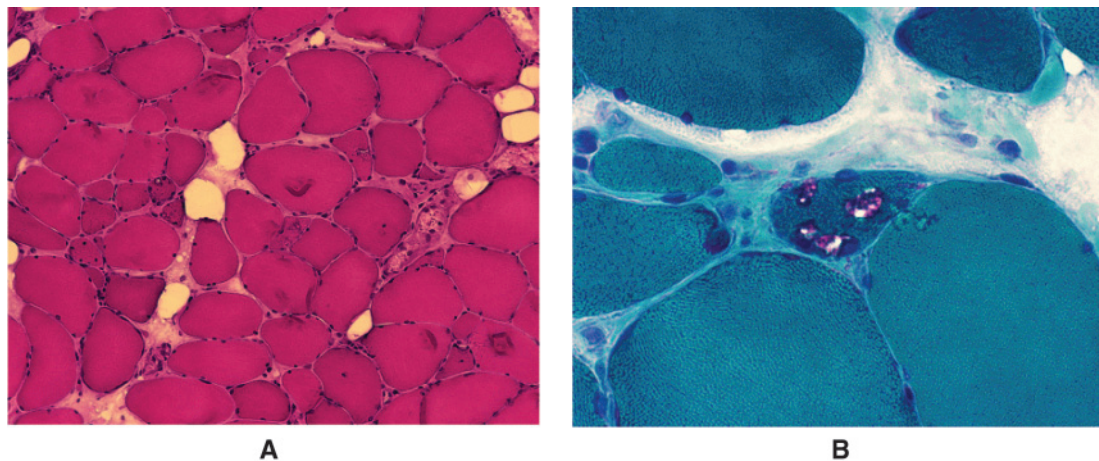


Figure 1. Muscle biopsy findings from biceps muscle of Patient 2. A. Chronic myopathic changes are observed, including increased fiber size variations, with atrophied and angulated fibers. (hematoxylin and eosin stain, original magnification X 200) B. Rimmed vacuoles are seen at an angulated fiber (modified Gomori-trichrome stain, original magnification X 400)

with HIBM/DRMV.⁷ By contrast, the genetic loci of OPDM remain unknown. Ultrastructural study is another important investigation to help in the differential diagnosis. Although rimmed vacuoles have been commonly observed in OPDM, oculopharyngeal muscular dystrophy, and HIBM/DMRV; 8.5 nm intranuclear tubulofilamentous inclusions are unique to oculopharyngeal muscular dystrophy.⁴ In this regard, all of our patients had OPDM rather than oculopharyngeal muscular dystrophy or HIBM/DMRV, because they had

neither *PABPN1* nor *GNE* mutations and showed no intranuclear inclusions on electron microscopic examination.

Clinically, our three patients showed consistent features with middle age of disease onset, distal muscle weakness as the earliest symptom, and the presence of ptosis and facial weakness. They also showed variable ophthalmoplegia, masseter weakness, dysphagia, and proximal muscle weakness (Table 1). The variable features may be related to the duration of the disease in the

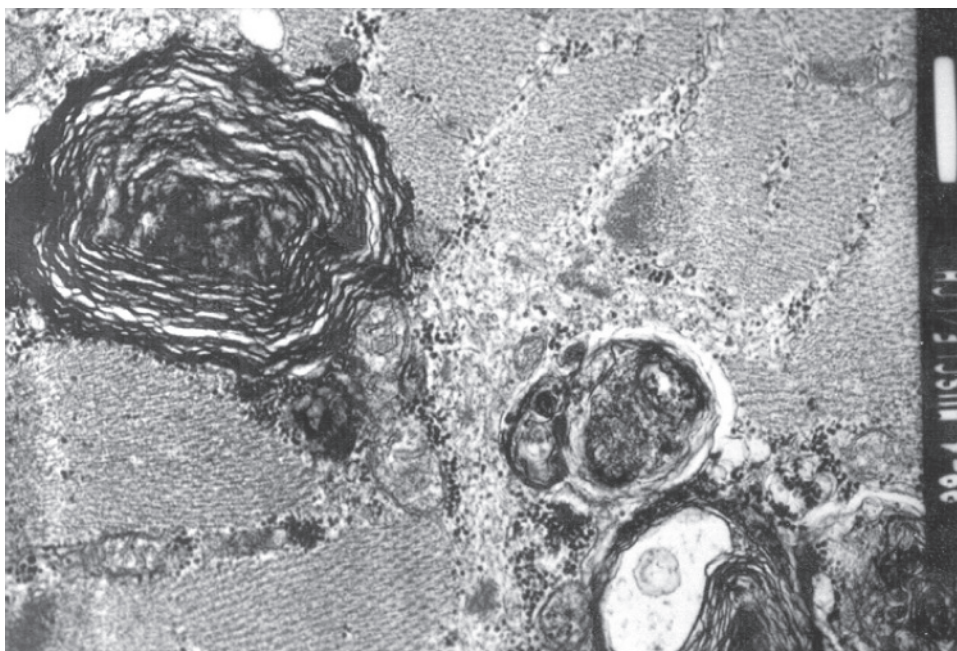


Figure 2. Electron microscopy of biopsied biceps muscle from patient 1. No intranuclear inclusion was found.

individual patients. While Patient 3 (disease duration of 2 years) had milder symptoms of ptosis, distal weakness, and facial weakness, Patient 1 (disease duration of 10 years) showed the full-blown features of OPDM (*i.e.*, ptosis, external ophthalmoplegia, facial and bulbar weakness, and distal dominant limb weakness). Patient 2 (disease duration of 4 years) showed intermediate features. None of our patients had an affected family member and no parental DNA was available for analysis. Therefore, we could not determine whether our cases resulted

from autosomal recessive mutations or *de novo* mutations with autosomal dominant inheritance. Based on a literature review, we summarized the clinical manifestations of AD-, AR- and sporadic OPDM. (Table 2) AD- and AR-OPDM share similar clinical features, although AR-OPDM generally shows a more severe clinical phenotype than the AD-. Oculopharyngeal muscular dystrophy has an earlier age of onset and more severe weakness in the oculofacial, and distal limb muscles.^{3,8,13}

Despite the wide range of clinical features,

Table 2: Summary of previous literature on OPDM and findings of present study

Disease	OPDM							
	Present study (N = 3)	Satoyoshi et al ¹ (N = 6)	Uyama et al ⁴ (N = 2)	Van der et al ¹³ (N = 2)	Minami et al ² (N = 5)	Witoonpanich et al ¹⁴ (N = 2)	Lu H et al ¹⁵ (N = 6)	Durmus H et al ¹⁶ (N = 47)
Onset age in years	>40	>40	35,40	10,20	>40	33,35	>20	21.9 ± 8.8 (mean)
Inheritance pattern	Sporadic,	AD	AR	AR	AD, Sporadic uncertain	AD	AR(?)	AD,AR, undetermined
Duration of disease (years)	2–10	5–12	11–13	19–25	Not described	8, 2	2–17	1–41
Initial muscular involvement								
Ptosis		5/6		1/2	4/5†	2/2		36/47
Extraocular								0/47
Nasal speech								2/47
Facial								2/47
Bulbar							1/6	6/47
Distal limb	3/3*	1/6	2/2		2/5†		5/6	1/47
Severity of disease (MRC grade or severity)								
Proximal	4 (neck flexor)	Affected late, milder than distal	Not affected	Affected late 3–4	Not affected	Not affected	4–5	Usually, affected lately, 4/47 patients showed proximal dominant pattern
Distal	4–5	Severely affected (foot drop)	Affected, severity not described by MRC score	1–2	Affected, severity not described by MRC score	Affected, severity described as 'mild'	3–4	35/47 showed distal dominant weakness

* N1/N2; number of patients who have symptom/number of patients who enrolled in study

† one of five patient showed simultaneous ptosis and distal limb weakness at the initial stage

distal weakness or ptosis is a consistent initial manifestation of both AD- and AR-OPDM. Ptosis was the initial presenting symptom in 11 of the 13 patients with AD-OPDM reported by Satoyoshi and Kinoshita¹, Minami *et al.*², and Witoonpanich *et al.*¹⁴ By contrast, three of the four patients with AR-OPDM reported by Uyama³ *et al.* and Van der Sluijs *et al.*¹³ presented with distal limb weakness as an early manifestation (Table 2). These findings suggest that distal limb weakness is a more frequent initial symptom in patients with AR- or sporadic OPDM^{8,13}, whereas ptosis is more frequent in AD-OPDM.^{1,14} On the other hand, a recent attempt to group the inheritance patterns in a large sample of patients based on clinical manifestations failed. The report on 47 Turkish patients with AD-, AR-, or undetermined OPDM showed that the most common initial symptoms was ptosis, followed by oropharyngeal symptoms and distal weakness, which started 5 years after disease onset. Thirty-six patients had droopy eyelids, whereas, only one patient had distal limb weakness as an initial symptom. They also found that the patients from AD and AR families did not differ significantly in terms of age at onset, clinical presentation, disease severity, or laboratory findings.¹⁶ This is different from findings of our study, as all of our patients initially developed gait disturbance or hand weakness due to the involvement of the distal musculature; followed by progressive ptosis and dysarthria/ dysphagia. This may be due to a different genetic defect causing the OPDM phenotype and ethnic differences. Based on our patients and a literature review, we found that the OPDM phenotype is more variable than previously thought. Remarkable intrafamilial phenotypic variability in AD-¹⁶ and AR-³ OPDM constituted additional evidence of this variable clinical spectrum.

It seems clear that OPDM remains as underdiagnosed entity, and can be confused with other diseases, such as oculopharyngeal muscular dystrophy, DMRV/HIBM, and mitochondrial myopathy. Although a careful clinical and pathological evaluation is helpful, the exclusion of responsible gene mutations is an essential step for making a definite diagnosis of OPDM until the causative gene is discovered.

In summary, we reported on three Korean patients with sporadic OPDM who presented with early distal limb weakness, in whom the diagnosis was established on the basis of ultrastructural and molecular genetic studies. We postulate that initial distal limb weakness is a characteristic finding in OPDM in certain ethnic groups as compared with other known muscular dystrophies.

REFERENCES

1. Satoyoshi E, Kinoshita M. Oculopharyngodistal myopathy. *Arch Neurol* 1977; 34:89-92.
2. Minami N, Ikezoe K, Kuroda H, Nakabayashi H, Satoyoshi E, Nonaka I. Oculopharyngodistal myopathy is genetically heterogeneous and most cases are distinct from oculopharyngeal muscular dystrophy. *Neuromuscul Disord* 2001; 11:699-702.
3. Uyama E, Uchino M, Chateau D, Tome FM. Autosomal recessive oculopharyngodistal myopathy in light of distal myopathy with rimmed vacuoles and oculopharyngeal muscular dystrophy. *Neuromuscul Disord* 1998; 8:119-25.
4. Tome FM, Chateau D, Helbling-Leclerc A, Fardeau M. Morphological changes in muscle fibers in oculopharyngeal muscular dystrophy. *Neuromuscul Disord* 1997; 7 (Suppl 1):S63-9.
5. Miller SA, Dykes DD, Polesky HF. A simple salting out procedure for extracting DNA from human nucleated cells. *Nucleic Acids Res* 1988; 16:1215.
6. Brais B, Bouchard JP, Xie YG, *et al.* Short GCG expansions in the PABP2 gene cause oculopharyngeal muscular dystrophy. *Nat Genet* 1998; 18:164-7.
7. Eisenberg I, Avidan N, Potikha T, *et al.* The UDP-N-acetylglucosamine 2-epimerase/N-acetylmannosamine kinase gene is mutated in recessive hereditary inclusion body myopathy. *Nat Genet* 2001; 29:83-7.
8. Uyama E, Nohira O, Chateau D, *et al.* Oculopharyngeal muscular dystrophy in two unrelated Japanese families. *Neurology* 1996; 46:773-8.
9. Bouchard JP, Brais B, Brunet D, Gould PV, Rouleau GA. Recent studies on oculopharyngeal muscular dystrophy in Quebec. *Neuromuscul Disord* 1997; 7 (Suppl 1):S22-9.
10. Vita G, Dattola R, Santoro M, Messina C. Familial oculopharyngeal muscular dystrophy with distal spread. *J Neurol* 1983; 230:57-64.
11. Argov Z, Sadeh M, Eisenberg I, Karpati G, Mitrani-Rosenbaum S. Facial weakness in hereditary inclusion body myopathies. *Neurology* 1998; 50:1925-6.
12. Uyama E, Tsukahara T, Goto K, *et al.* Nuclear accumulation of expanded PABP2 gene product in oculopharyngeal muscular dystrophy. *Muscle Nerve* 2000; 23:1549-54.
13. van der Sluijs BM, ter Laak HJ, Scheffer H, van der Maarel SM, van Engelen BG. Autosomal recessive oculopharyngodistal myopathy: a distinct phenotypical, histological, and genetic entity. *J Neurol Neurosurg Psychiatry* 2004; 75:1499-501.
14. Witoonpanich R, Phankhian S, Sura T, Lertrit P, Phudhichareonrat S. Oculopharyngodistal myopathy in a Thai family. *J Med Assoc Thai* 2004; 87:1518-21.
15. Lu H, Luan X, Yuan Y, Dong M, Sun W, Yan C. Oculopharyngodistal myopathy is a distinct entity: clinical and genetic features of 47 patients. *Neuropathology*. 2008; 28(6):599-603.
16. Durmus H, Laval SH, Deymeer F, *et al.* Oculopharyngodistal myopathy is a distinct entity: clinical and genetic features of 47 patients. *Neurology* 2011; 76:227-35.