

## 가

- 
- 

## Stone Basket

1

2

3

: 가  
 (stone basket)  
 : 2004 3 2005 6 가  
 30 36 ( 16 ,  
 20 ). (urokinase) (10 - 20 unit), (6 mm ,  
 4 cm ), 가  
 (maceration)  
 가 14 stone basket  
 Kaplan - Meier method  
 Fisher 's exact test Log - rank test  
 : 36 30 가 83%  
 29 81%  
 . 94% 70%  
 (p=0.104). Stone basket  
 93% (13/14) . 3 , 6 , 12 78%,  
 61%, 51%  
 (p=0.871).  
 : 가  
 stone basket

(1).

가  
가  
가

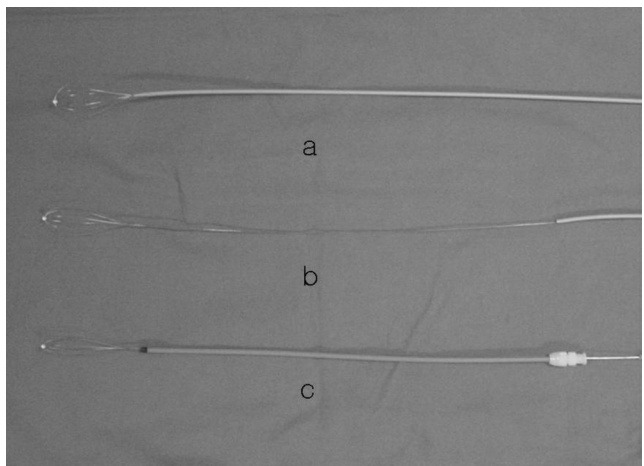
(2). 가

(3 - 5)

Arrow - Trerotola, Amplatz, Hydrolyser, Mini - pig - tail catheter, (pulse spray), (aspiration thrombectomy), (clot maceration) (6 - 13).

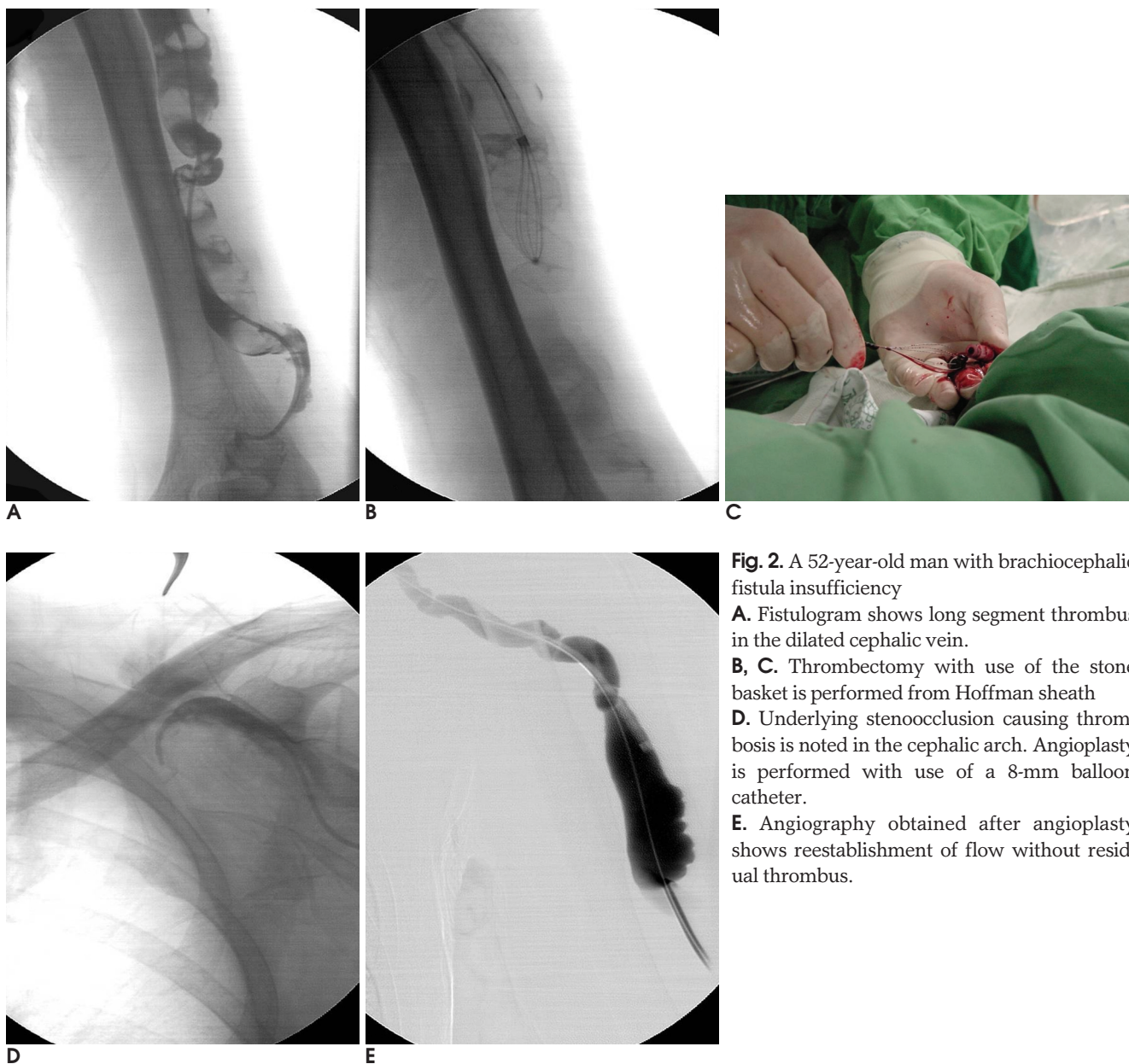
clot maceration, 가, 가, 가, stone basket

2004 3 2005 6 가 30 36 (brachiocephalic fistula)가 16 (radiocephalic fistula)가 20 23 5 cm 13 5 cm . 18 (cephalic vein) (aneurysmal dilatation) 15 가 .



**Fig. 1.** The picture of Wittich nitinol stone basket (a). The outer shaft of basket made from polyethylene is pared off with surgical blade and is left inner nitinol wire shaft behind (b). Stone basket is inserted into dialysis fistula through Hoffman sheath (c). Thrombus is fragmentated by mechanical action of rotating stone basket. Rotating is performed by twisting the basket shaft manually.

: 가 (juxtaanastomotic cephalic vein) 1 , (multifocal cephalic vein stenosis) 6 (cephalic arch stenosis) 가 4 , (distal cephalic vein stenosis) 3 9 , 8 , 가 2 , 1 urokinase (Green Cross, Seoul, Korea) clot maceration, urokinase 10 - 20 unit 7 - F 8 - F (Hoffman sheath, Cook, Bloomington, IN) 12 stone basket 1 stone basket . Stone basket Wittich nitinol stone basket (Cook, Bloomington, IN) (poly - ethylene) (shaft) Hoffman sheath (Fig. 1) Hoffman sheath (Fig. 2A - 2C). stone basket sheath stone basket sheath sheath stone basket (Fig. 2D). 가 30% (technical success) (Fig. 2E) 1 (clinical success) (completion angiography) Kaplan - Meier method Fischer's exact test Log - rank test .



**Fig. 2.** A 52-year-old man with brachiocephalic fistula insufficiency

**A.** Fistulogram shows long segment thrombus in the dilated cephalic vein.

**B, C.** Thrombectomy with use of the stone basket is performed from Hoffman sheath

**D.** Underlying stenooclusion causing thrombosis is noted in the cephalic arch. Angioplasty is performed with use of a 8-mm balloon catheter.

**E.** Angiography obtained after angioplasty shows reestablishment of flow without residual thrombus.

sheath가

. 1

36 30  
83%

가

. Stone basket  
93% (13/14)

29  
81%

. 1

16 15  
94%

가

14

20  
70%

1

( $p=0.104$ ). 6  
5

stone basket

(organized thrombus)

15 13

가

2

(angulation)

Hoffman

가

472

basket sheath	sheath				(randomized
			control study)	가	
			가		가
. Stone basket				stone basket	
가					
basket					
		가			
stone basket			가		
stone basket		1			
6					
			가	가	
					(20 - 24).
Turmel - Rodrigues	(8)				
12		93%, 76%	3, 6,		
가		89%, 70%, 49%	36%, 18%, 9%		
	Rajan	(2)		가	
			16	15	
		94%			
20	14			70%	
가			(8)		
가		가			
Hoffman sheath	가				
가					
		stone basket			

- Schwab SJ. Assessing the adequacy of vascular access and its relationship to patient outcome. *Am J Kidney Dis* 1994;24:316-320
- Rajan DK, Clark TW, Simons ME, Kachura JR, Sniderman K. Procedural success and patency after percutaneous treatment of thrombosed autogenous arteriovenous dialysis fistulas. *J Vasc Interv Radiol* 2002;13:1211-1218
- Minar E, Zazgornik J, Marosi L. Local low-dose streptokinase thrombolysis of a thrombosed arteriovenous fistula. *Am J Nephrol* 1984;4:66-67
- Matuszkiewicz-Rowinska J, Billip-Tomecka Z, Rowinski W, Sicinski A. Systemic streptokinase infusion for declotting of hemodialysis arteriovenous fistulas. *Nephron* 1994;66:67-70
- Mangiarotti G, Canavese C, Thea A, Segoloni GP, Stratta P, Salomone M, et al. Urokinase treatment for arteriovenous fistulae declotting in dialyzed patients. *Nephron* 1984;36:60-64
- Schon D, Mishler R. Pharmacomechanical thrombolysis of natural vein fistulas: reduced dose of TPA and long-term follow-up. *Semin Dial* 2003;16:272-275
- Turmel-Rodrigues L, Pengloan J, Rodrigue H, Brillet G, Lataste A, Pierre D, et al. Treatment of failed native arteriovenous fistulae for hemodialysis by interventional radiology. *Kidney Int* 2000;57:1124-1140
- Rocek M, Peregrin JH, Lasovickova J, Krajickova D, Slaviokova M. Mechanical thrombolysis of thrombosed hemodialysis native fistulas with use of the Arrow-Trerotola percutaneous thrombolytic device: our preliminary experience. *J Vasc Interv Radiol* 2000;11:1153-1158
- Overbosch EH, Pattynama PM, Aarts HJ, Schultze Kool LJ, Hermans J, Reekers JA. Occluded hemodialysis shunts: dutch multicenter experience with the Hydrolyser catheter. *Radiology* 1996;201:485-458
- Haage P, Vorwerk D, Wildberger JE, Piroth W, Schurmann K, Gunther RW. Percutaneous treatment of thrombosed primary arteriovenous hemodialysis access fistulae. *Kidney Int* 2000;57:1169-1175
- Schmitz-Rode T, Wildberger JE, Hubner D, Wein B, Schurmann K, Gunther RW. Recanalization of thrombosed dialysis access with use of a rotating mini-pigtail catheter: follow-up study. *J Vasc Interv Radiol* 2000;11:721-727
- Liang HL, Pan HB, Chung HM, Ger LP, Fang HC, Wu TH, et al. Restoration of thrombosed Brescia-Cimino dialysis fistulas by using percutaneous transluminal angioplasty. *Radiology* 2002;223:339-344
- Poulain F, Raynaud A, Bourquelot P, Knight C, Rovani X, Gaux JC. Local thrombolysis and thromboaspiration in the treatment of acutely thrombosed arteriovenous hemodialysis fistulas. *Cardiovasc Intervent Radiol* 1991;14:98-101
- Hunter DW, So SK. Dialysis access: radiologic evaluation and

- management. *Radiol Clin North Am* 1987;25:249-260
15. Saeed M, Newman GE, McCann RL, Sussman SK, Braun SD, Dunnick NR. Stenoses in dialysis fistulas: treatment with percutaneous angioplasty. *Radiology* 1987;164:693-697
  16. Bone GE, Pomajzi MJ. Management of dialysis fistula thrombosis. *Am J Surg* 1979;138:901-906
  17. Schwartz CI, McBrayer CV, Sloan JH, Meneses P, Ennis WJ. Thrombosed dialysis grafts: comparison of treatment with transluminal angioplasty and surgical revision. *Radiology* 1995;194:337-341
  18. Gelbfish GA. Surgery versus percutaneous treatment of thrombosed dialysis access grafts: is there a best method?. *J Vasc Interv Radiol* 1998;9:875-877
  19. Aruny JE, Lewis CA, Cardella JF, Cole PE, Davis A, Drooze AT, et al. Quality improvement guidelines for percutaneous management of the thrombosed or dysfunctional dialysis access. *J Vasc Interv Radiol* 1999;10:491-498
  20. Turmel-Rodrigues L, Pengloan J, Baudin S, Testou D, Abaza M, Dahdah G, et al. Treatment of stenosis and thrombosis in haemodialysis fistulas and grafts by interventional radiology. *Nephrol Dial Transplant* 2000;15:2029-2036
  21. Sivanesan S, How TV, Bakran A. Sites of stenosis in AV fistulae for haemodialysis access. *Nephrol Dial Transplant* 1999;14:118-120
  22. Lay JP, Ashleigh RJ, Tranconi L, Ackrill P, Al-Khaffaf H. Result of angioplasty of Brescia-Cimino haemodialysis fistulae: medium-term follow-up. *Clin Radiol* 1998;53:608-611
  23. Hunter DW, Castaneda-Zuniga WR, Coleman CC, Young AT, Salomonowitz E, Mercado S, et al. Failing arteriovenous dialysis fistulas: evaluation and treatment. *Radiology* 1984;152:631-635
  24. Cada E, Karnel F, Mayer G, Langle F, Schurawitzki H, Graf H. Percutaneous transluminal angioplasty of failing arteriovenous dialysis fistulae. *Nephrol Dial Transplant* 1989;4:57-61

## Percutaneous Treatment of Thrombosed Native Arteriovenous Dialysis Fistula Insufficiency: Efficacy of Mechanical Thrombectomy with Using the Stone Basket<sup>1</sup>

Young Hwan Kim, M.D., Sung Min Ko, M.D., Mi Jung Kim, M.D., Jung Hyeok Kwon, M.D.,  
Cheol Ho Sohn, M.D., Jin Soo Choi, M.D., Kyung Sik Park, M.D.<sup>2</sup>, Yong Joo Kim, M.D.<sup>3</sup>

<sup>1</sup>Department of Diagnostic Radiology, Dongsan Medical Center, Keimyung University College of Medicine

<sup>2</sup>Department of internal medicine, Dongsan Medical Center, Keimyung University College of Medicine

<sup>3</sup>Department of Diagnostic Radiology, Andong General Hospital

**Purpose:** We wanted to evaluate the procedural success after percutaneous treatment of thrombosed native arteriovenous dialysis fistula insufficiency and the efficacy of performing mechanical thrombectomy with using the stone basket.

**Materials and Methods:** From March 2004 to June 2005, 36 thrombosed native hemodialysis access shunts in the upper limbs (brachiocephalic fistulas: 16 and radiocephalic fistulas: 20) were percutaneously treated in 30 patients. Dec clotting procedures were performed with using urokinase (100,000 - 200,000 unit) and manual catheter-directed thrombo-aspiration in all the patients. Angioplasty (6 mm in diameter and 4 cm in length) was performed at the identified area of the stenosis and/or with maceration of the thrombus. In 14 cases with massive thrombosis that was refractory to the above mentioned dec clotting procedures, mechanical thrombectomy with using a Wittich nitinol stone basket (Cook, Bloomington, IN) was performed. Data regarding the procedural success rate and the patency rate were analyzed by means of Fischer's exact test, and the Kaplan-Meier method with the Log-rank test was used for statistical inter-group comparisons between the brachiocephalic and radiocephalic fistulas.

**Results:** Successful dec clotting and restoration of thrill were achieved in 30 of 36 procedures (83%). Reestablishment of normal dialysis for at least one session was achieved in 29 of 36 procedures (81%). The procedural success rate for the brachiocephalic fistulas was 94% compared with 70% for the radiocephalic fistulas, but the difference was not statistically significant ( $p=0.104$ ). In the cases with performing mechanical thrombectomy and using the stone basket, procedural success was achieved in 93% (13/14). The expected patency rates at 3, 6 and 12 months were 78%, 61% and 51%, respectively. The patency rates after dec clotting procedures were not significantly different between the brachiocephalic and radiocephalic fistulas ( $p=0.871$ ).

**Conclusion:** Percutaneous treatment of thrombosed native arteriovenous dialysis fistula insufficiency showed an excellent success rate and patency rate, and especially performing mechanical thrombectomy with using the stone basket could increase the procedural success rate.

**Index words :** Dialysis, shunts  
Thrombectomy  
Thrombolysis

Address reprint requests to : Young Hwan Kim, M.D., Department of Diagnostic Radiology, Dongsan Medical Center, Keimyung University College of Medicine, 194 Dongsan-dong, Jung-gu, Taegu 700-712, Korea.  
Tel. 82-53-250-7770 Fax. 82-53-250-7766 E-mail: yhkim68@dsmc.or.kr