

# The Effectiveness of a Snake Liver Retractor during Needlescopic Grasper Assisted Single-Incision Laparoscopic Cholecystectomy in the Aspect of Securing a Critical View of Safety

Myung-Guen Cha, M.D., Tae-Seok Kim, M.D., Kee-Hwan Kim, M.D., Ph.D.,  
Chang-Hyeok An, M.D., Ph.D., Jeong-Soo Kim, M.D., Ph.D.

*Department of Surgery, Uijeongbu St. Mary's Hospital, College of Medicine,  
The Catholic University of Korea, Uijeongbu, Korea*

**Purpose:** Limited traction has been an obstacle in the advancement of single incision laparoscopic cholecystectomy (SILC). Adequate retraction is necessary for safe performance of a cholecystectomy. In this study, we introduce our method for securing CVS for prevention of bile duct injury during performance of SILC and evaluated the effectiveness of the snake liver retractor.

**Methods:** A total of 148 patients who underwent needle-scopically assisted SILC (nSILC) from February 2011 to February 2012 at Uijeongbu St. Mary's Hospital, Uijeongbu, Korea were analyzed. Patients were categorized into two groups: Group I consisted of patients who underwent nSILC without use of a snake liver retractor from February 2011 to October 2011 (n=51) and group II consisted of patients who underwent nSILC using a snake liver retractor from October 2011 to February 2012 (n=97). Patient characteristics and operative outcomes were compared between groups in order to evaluate the effectiveness of use of a snake liver retractor during per-

formance of SILC.

**Results:** There were no differences in age, sex, BMI, and history of previous abdominal surgery. However, more difficult surgeries for acute cholecystitis were performed in group II. Nevertheless, no differences in operative outcomes, such as operative time, rate of bile spillage, open conversion rate, intraoperative complication, and postoperative hospital stay were observed between groups. In addition, CVS identification time was rather shorter in group II, compared with group I.

**Conclusion:** Results of this study showed that nSILC using a snake liver retractor can allow for achievement of CVS safely and for expansion of indication for SILC through improvement of exposure and obtaining adequate traction.

**Key words:** Single incision laparoscopic cholecystectomy, Liver retractor, Critical view of safety

## INTRODUCTION

Laparoscopic cholecystectomy has become the gold standard treatment for benign gallbladder disease since its introduction in 1985.<sup>1,2</sup> Minimal invasive technique has proven effective in reducing surgical trauma, thereby improving patient recovery and length of hospital stay compared to a conventional surgery.<sup>3</sup> For such reasons, more minimally invasive surgical techniques in order to enhance the advantages of laparoscopy have been attempted, and single-incision laparoscopic cholecystectomy (SILC) was described in 1997 by Navarra et

al.<sup>4</sup> However, this technique has spread slowly until more recent years due to operative difficulties and concern about its safety.<sup>5</sup>

Iatrogenic bile duct injury is the most common severe complication of cholecystectomy and increasing rate of bile duct injury is one of the major concerns of SILC. Traditionally, bile duct injury rate for open cholecystectomy has been reported as approximately 0.2%.<sup>6</sup> During the "learning curve" while laparoscopic cholecystectomy was being introduced on a global scale, early reports suggested dramatic increase in the incidence of bile duct injuries as high as 0.74% to 2.8%.<sup>7</sup> Over time, the rate of bile duct injuries settled to a new plateau, albeit at a higher level of approximately 0.4% to 0.5%.<sup>8-10</sup> Similarly in conventional laparoscopic cholecystectomy, during the "learning curve of SILC", increased incidence of bile duct injuries was the major concern and many researchers have been trying to find the way to prevent bile duct injury during SILC.

The "critical view of safety (CVS)" initially introduced by Strasberg et al.<sup>11</sup> in 1995 has become the gold standard method for safe laparoscopic cholecystectomy. This technique is de-

Received July 16, 2013, Revised August 14, 2013,  
Accepted August 20, 2013

\* Corresponding author : Kee-Hwan Kim

Department of Surgery, Uijeongbu St. Mary's Hospital, College of  
Medicine, The Catholic University of Korea, 271 Cheonbo-ro,  
Uijeongbu 480-717, Korea

Tel : +82-31-820-3562, Fax : +82-31-847-2717

E-mail : keehwan@catholic.ac.kr

fined by clear visualization of the cholecystic hilar structures and is made possible by the simultaneous retraction of the gallbladder in two opposing vectors, cephalad and lateral.<sup>12</sup> However, adequate retraction of gallbladder in each direction for securing CVS is very difficult in SILC due to repeated conflicts between operating instruments vying for space at the single-access site. Thus, snake liver retractor for cephalad retraction of gallbladder and additional needlescopic instrument (Minilap Grasper, Stryker, San Jose, CA) for lateral retraction have been used during SILC (needlescopic grasper assisted SILC, nSILC) in our center since October 2011.

In this study, we introduce our method securing CVS for prevention of bile duct injury during SILC and evaluated the effectiveness of snake liver retractor by reviewing the needlescopic grasper assisted SILC (nSILC) performed in our center with or without using snake retractor.

## MATERIALS AND METHODS

From February 2011 to February 2012, 148 patients underwent nSILC using needlescopic instrument for benign gallbladder disease at Uijeongbu St. Mary's Hospital, Uijeongbu, Korea. Snake liver retractor was not used during nSILC before October 2011, however snake liver retractor has been used for clear visualization of Calot's triangle by cephalad traction of hepatic hilum since October 2011. According to the use of snake liver retractor, the patients were categorized into 2 groups: Group I consisted of patients underwent nSILC without snake liver retractor from February 2011 to October 2011 (n=51) and group II consisted of patients underwent nSILC with snake liver retractor from October 2011 to February 2012 (n=97). Thirty cases of nSILC performed before February 2011 were excluded in this study for eliminating learning curve effect. These patients were retrospectively reviewed to investigate the patients' characteristics and operative outcomes such as operating time, CVS identification time, intraoperative complication, bile spillage, conversion to open surgery, postoperative complication, and the length of hospital stay. The patients' characteristics and surgical outcomes were compared between groups. To estimate the difficulty of operation, operation records and video files were reviewed and operations were scored according to the pericholecystic adhesion, wall thickening and distension of gallbladder. The difficulty of operation was divided into four grades (easy, moderate, hard, very hard) according to the scoring.

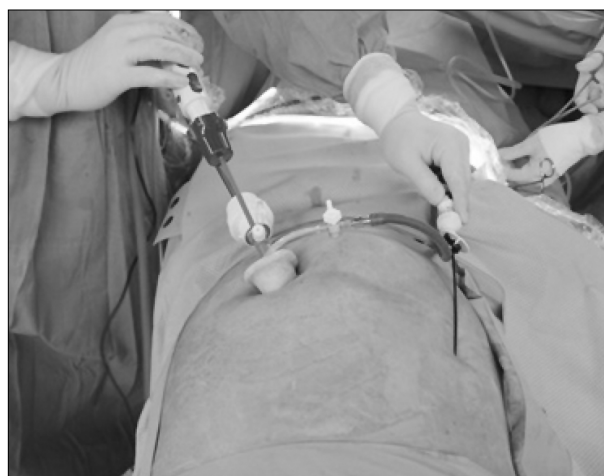Chi-square tests (or Fisher's exact test, when necessary) were used to compare categorical variables and t-tests (or Mann-

Whitney U test, when necessary) for continuous variables. All analyses were done with IBM SPSS Statistics version 18.0 program. Results were considered to be significant when p-values were less than 0.05.

### 1) Surgical techniques

The operations were performed under general anesthesia with the supine position in a reverse Trendelenburg and tilted to the left. A 25-mm transumbilical incision was made longitudinally and the natural umbilical defect was used to access the peritoneum. The peritoneum was opened under direct visualization and the SILS Port (Covidien) was inserted under direct vision into the peritoneal cavity. Pneumoperitoneum was induced and maintained at 12 mmHg with carbon dioxide during operation, and a 12-mm trocar for laparoscope and a 5-mm trocar for working instrument were inserted. In cases of nSILC using snake liver retractor, one more 5-mm trocar was inserted. For lateral retraction of gallbladder, needlescopic grasper (Minilap Grasper, Stryker, San Jose, CA) was additionally inserted through direct puncture on right abdomen (Fig. 1). Dissection was performed meticulously using a monopolar electro-cautery hook and CVS was achieved in almost cases. After achieving CVS, 5-mm hemlock clips were used to ligate the duct and artery, which were transected using laparoscopic scissors. After dissection of the gallbladder from liver bed, it was removed using endobag through umbilicus. Finally abdominal wall was closed with absorbable suture and the umbilicus was restored to its physiologic position.

All patients were treated by the same surgeon.



**Fig. 1.** External view of needlescopic grasper assisted SILC (nSILC) procedure.

**Table 1.** Characteristics of patients undergoing nSILC

	Group I (n=51)	Group II (n=97)	Total (n=148)	<i>p</i>
Age (yrs)	48.8±13.8	49.8±15.3	49.5±14.8	0.703
Sex				
Female	33 (65%)	66 (68%)	99 (67%)	0.682
Male	18 (35%)	31 (32%)	49 (33%)	
BMI (kg/m <sup>2</sup> )	25.6±3.7	25.8±4.2	25.7±4.1	0.756
Difficulty				
Easy	45 (88%)	67 (69%)	112 (75%)	0.010
Moderate	6 (12%)	14 (14%)	20 (14%)	
Hard	0	7 (7%)	7 (5%)	
Very hard	0	9 (10%)	9 (6%)	
Diagnosis				
Chronic cholecystitis	46 (90%)	77 (79%)	123 (83%)	0.001
Acute cholecystitis	0	16 (16%)	16 (11%)	
Other benign disease	4 (8%)	4 (5%)	8 (5%)	
Gallbladder cancer	1 (2%)	0	1 (1%)	
Previous lower abdominal surgery	14 (27%)	25 (26%)	39 (26%)	0.826

**Table 2.** Comparison of surgical outcomes between group I and group II

	Group I (n=51)	Group II (n=97)	<i>p</i>
Operative time (min)	66.3±26.6	63.6±41.3	0.670
CVS* identification time (min)	36.6±20.4	27.8±21.2	0.017
Bile spillage	7 (14%)	14 (14%)	0.907
Conversion to open surgery	0	2 (2%)	0.545
Intraop. Complication			
Bile duct injury	0	0	0.545
Massive bleeding	0	2 (2%)	
Postop. Hospital stay (day)	2.2±0.5	2.4±1.2	0.059

\*Critical view of safety.

## RESULTS

### 1) Patient characteristics

The characteristics of patients included in this study are shown in Table 1. The age and body mass index (BMI) were similar between the groups. The proportion of female patients was also similar between groups (65% vs 68%,  $p=0.682$ ). However, there were significant differences between groups in difficulty of operation ( $p=0.010$ ) and pathologic diagnosis ( $p=0.001$ ). All operations in group I (nSILC not using snake liver retractor) were easy or moderate level, whereas 17% of operations in group II (nSILC using snake liver retractor) were hard or very hard level. There was no patients diagnosed with acute cholecystitis in group I, however 16% of patients in group II were diagnosed with acute cholecystitis. One patient in group

I was incidentally diagnosed with gallbladder cancer after surgery. There was no significant difference in history of lower abdominal surgery between groups.

### 2) Operative outcomes

Perioperative surgical outcomes in both groups are shown in Table 2. The mean operative time was 66.3 minute in group I and 63.6 minute in group II. There was no statistical difference in mean operative time. However, mean CVS identification time was significantly shorter in group II than group I (36.6 min vs 27.8 min,  $p=0.017$ ). The episodes of bile spillage during nSILC were occurred similarly in both groups. (about 14% in both groups,  $p=0.907$ ). There was no episode of bile duct injury in both groups, however 2 patients in group II required the conversion to open surgery owing to severe bleeding. There were technical difficulty in 2 patients due to severe adhe-

sion and wall thickening resulting from common bile duct stone and inflammation. Although 2 patients required the conversion to open surgery in group II, there was no statistical difference in intraoperative complication. There was also no statistical difference in the length of postoperative hospital stay (2.2 days vs 2.4 days,  $p=0.059$ ).

## DISCUSSION

Since the introduction of minimal invasive surgery, the techniques of minimally invasive surgery have evolved continuously for a less invasive and more cosmetic results with an emphasis on decreasing the number or size of the trocars. Although applied in a variety of general surgery cases including appendectomy,<sup>13</sup> sleeve gastrectomy,<sup>14</sup> splenectomy,<sup>15</sup> and colectomy,<sup>16</sup> its test bed is cholecystectomy.<sup>5</sup> The first SILC was performed by Navarra et al. in late 1990's in order to further reduce abdominal wall surgical trauma, since then, many authors have published different approaches to this procedure. However this procedure has not accepted as standard treatment for benign gallbladder disease yet due to one of the main problems, concern about its safety. Many groups have applied Critical View of Safety (CVS) technique described by Strasberg and Helton<sup>17</sup> for preventing bile duct injury during laparoscopic cholecystectomy. For this technique, adequate retraction on gallbladder fundus and/or infundibulum was needed and various methods such as transabdominal suture, use of articulating instruments and internal grasper retractors have been applied.<sup>18,19</sup> Nevertheless, none of the reported technical notes has become a standard yet.

Multiple instruments through a single port tend to conflict each other and make crossed-over instruments, resulting in inadequate tractions, difficult exposure of structures and unergonomic position of the surgeon.<sup>20,21</sup> Although articulated/curved instruments were introduced to overcome these problems, the impact of these instruments has been limited. In our center, we preferred to use additional direct puncture needlescopic grasper (Minilap Grasper, Stryker, San Jose, CA) during SILC (Fig. 1). This technique can make improving exposure and obtaining adequate tractions in achieving CVS due to a wider angle between the two operative instruments as well as obtaining similar cosmetic effect with SILC. Furthermore, in case of an incidental gallbladder cancer, this technique can prevent potential neoplastic cells seeding caused by bile spillage through the holes of the retracting sutures, using in transabdominal gallbladder retraction suture technique. However, this technique has also limitation on cephalad traction and ex-

posure of Calot's triangle when the liver droop down and cover hepatic hilum. For better visualization and secure dissection of Calot's triangle, we have used snake liver retractor for cephalad traction of hepatic hilum through single port since October 2011 (Fig. 2). With this technique, better visualization of Calot's triangle was obtained and CVS was achieved safely.

In this study, we compared the clinical features and operative outcomes of the patients undergoing nSILC before and after October 2011 when the snake liver retractor used first, and focused on improving the aid procedure with liver retraction on hilum portion using snake liver retractor. Most clinical features and operative outcomes were not different significantly between groups, however there were significant difference in pathologic diagnosis, operation difficulty and CVS identification time between groups. Among the patients in group II (nSILC using snake liver retractor), 16% of patients were diagnosed with acute cholecystitis and difficult operations (hard or very hard level) were performed in 17% of patients, whereas there was no patients with acute cholecystitis and underwent difficult operation in group I (nSILC not using snake liver retractor). Nevertheless, mean CVS identification time was rather shorter in group II than group I and there was no significant difference in complication rate and open conversion rate between groups. These results demonstrate that snake liver retractor can help to make clear exposure of the Calot's triangle and secure dissection during achieving CVS. As a result, snake liver retractor can assist shortening of CVS identification time. Furthermore, nSILC using snake liver retractor can be performed not only in the selective patients but also the patients with acute cholecystitis or difficult case.

Although open conversion surgery needed in 2 patients un-

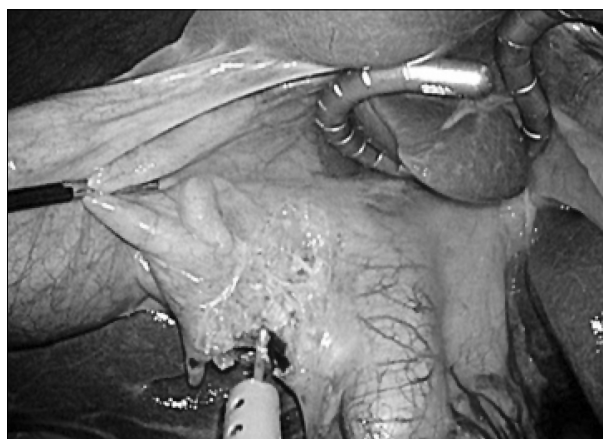


Fig. 2. Internal view of needlescopic grasper assisted SILC (nSILC) procedure using snake liver retractor.

derwent nSILC using snake liver retractor due to bleeding, there was no statistically significant difference in open conversion rate between groups and the operation difficulty in these 2 patients were very hard due to severe inflammation and adhesion caused by acute cholecystitis.

As previously mentioned, nSILC (SILC with additional needlescopic grasper) can overcome the problem of SILC, inadequate retraction caused by struggle between instruments within single port. Our experience, even if related to small series of patients, shows the effectiveness of snake liver retractor during achieving CVS.

### CONCLUSION

In conclusion, even with the limitation of the small series of patients, nSILC with the usage of snake liver retractor seems to assist achieving CVS safely and expansion of indication for SILC through improving exposure and obtaining adequate traction. However, to confirm this result, further studies with a large sample size are required.

### REFERENCES

- 1) Solomon D, Bell RL, Duffy AJ, Roberts KE. Single-port cholecystectomy: small scar, short learning curve. *Surg Endosc* 2010;24:2954-2957.
- 2) Pan MX, Jiang ZS, Cheng Y, et al. Single-incision vs three-port laparoscopic cholecystectomy: prospective randomized study. *World J Gastroenterol* 2013;19:394-398.
- 3) McGregor CG, Sodergren MH, Aslanyan A, et al. Evaluating systemic stress response in single port vs. multi-port laparoscopic cholecystectomy. *J Gastrointest Surg* 2011;15:614-622.
- 4) Navarra G, Pozza E, Occhionorelli S, Carcoforo P, Donini I. One-wound laparoscopic cholecystectomy. *Br J Surg* 1997;84:695.
- 5) Arezzo A, Scozzari G, Famiglietti F, Passera R, Morino M. Is single-incision laparoscopic cholecystectomy safe? Results of a systematic review and meta-analysis. *Surg Endosc* 2013;27:2293-2304.
- 6) Roslyn JJ, Binns GS, Hughes EF, Saunders-Kirkwood K, Zinner MJ, Cates JA. Open cholecystectomy A contemporary analysis of 42474 patients. *Ann Surg* 1993;218:129-137.
- 7) Joseph M, Phillips MR, Farrell TM, Rupp CC. Single incision laparoscopic cholecystectomy is associated with a higher bile duct injury rate: a review and a word of caution. *Ann Surg* 2012;256:1-6.
- 8) Nuzzo G, Giuliante F, Giovannini I, et al. Bile duct injury during laparoscopic cholecystectomy: results of an Italian national survey on 56 591 cholecystectomies. *Arch Surg* 2005;140:986-992.
- 9) Waage A, Nilsson M. Iatrogenic bile duct injury: a population-based study of 152 776 cholecystectomies in the Swedish Inpatient Registry. *Arch Surg* 2006;141:1207-1213.
- 10) Flum DR, Dellinger EP, Cheadle A, Chan L, Koepsell T. Intraoperative cholangiography and risk of common bile duct injury during cholecystectomy. *JAMA* 2003;289:1639-1644.
- 11) Strasberg SM, Hertl M, Soper NJ. An analysis of the problem of biliary injury during laparoscopic cholecystectomy. *J Am Coll Surg* 1995;180:101-125.
- 12) Sherwinter DA. A novel retraction instrument improves the safety of single-incision laparoscopic cholecystectomy in an animal model. *J Laparoendosc Adv Surg Tech A* 2012;22:158-161.
- 13) Ponsky TA, Diluciano J, Chwals W, Parry R, Boulanger S. Early experience with single-port laparoscopic surgery in children. *J Laparoendosc Adv Surg Tech A* 2009;19:551-553.
- 14) Saber AA, El-Ghazaly TH, Dewoolkar AV. Single-incision laparoscopic bariatric surgery: a comprehensive review. *Surg Obes Relat Dis* 2010;6:575-582.
- 15) Targarona EM, Balague C, Martinez C, Pallares L, Estalella L, Trias M. Single-port access: a feasible alternative to conventional laparoscopic splenectomy. *Surg Innov* 2009;16:348-352.
- 16) Chow AG, Purkayastha S, Zacharakis E, Paraskeva P. Single-incision laparoscopic surgery for right hemicolectomy. *Arch Surg* 2011;146:183-186.
- 17) Strasberg SM, Helton WS. An analytical review of vasculobiliary injury in laparoscopic and open cholecystectomy. *HPB* 2011;13:1-14.
- 18) Dominguez G, Durand L, De Rosa J, Danguise E, Arozamena C, Ferraina PA. Retraction and triangulation with neodymium magnetic forceps for single-port laparoscopic cholecystectomy. *Surg Endosc* 2009;23:1660-1666.
- 19) Gangl O, Hofer W, Tomaselli F, Sautner T, Fugger R. Single incision laparoscopic cholecystectomy (SILC) versus laparoscopic cholecystectomy (LC)-a matched pair analysis. *Langenbecks Arch Surg* 2011;396:819-824.
- 20) Chamberlain RS, Sakpal SV. A comprehensive review of single-incision laparoscopic surgery (SILS) and natural orifice transluminal endoscopic surgery (NOTES) techniques for cholecystectomy. *J Gastrointest Surg* 2009;13:1733-1740.
- 21) Rivas H, Varela E, Scott D. Single-incision laparoscopic cholecystectomy: initial evaluation of a large series of patients. *Surg Endosc* 2010;24:1403-1412.