대한신경외과학회지 : 제 23 권 제 2 호 1994

Arteriovenous Malformations of the Brain Associated with Cerebral Aneurysms*

Man Bin Yim, M.D., Il Man Kim, M.D, Sang Youl Kim, M.D.,
Jang Chull Lee, M.D., Eun Ik Son, M.D.,
Dong Won Kim, M.D., In Hong Kim, M.D.

Department of Neurosurgery, School of Medicine, Keimyung University, Taegu, Korea

뇌동맥류를 동반한 뇌동정맥기형

계명대학교 의과대학 신경외과학교실

임만빈 · 김일만 · 김상열 · 이장철 · 손은익 · 김동원 · 김인홍

= 국문초록 =

1981년부터 1993년 4월까지 계명대학교 동산의료원에서 가료한 뇌동정맥 기형 96례중 8례가 뇌동맥류를 동반하였고, 이중 다발성 뇌동맥류를 가진 3례가 있어 총 동맥류 수는 13개였다. 뇌동맥류를 동반한 예들과 동반하지 않은 예들의 평균연령을 비교한 바, 뇌동맥류를 동반하지 않은 예들은 26세 동반한 예들은 44세로써, 뇌동맥류를 동반한 예들에서 연령이 높았다($p<0.001$).

뇌동맥류는 뇌혈관촬영상 뇌동정맥기형의 직경이 3cm미만인 56례중 1례에서, 3~5cm인 23례중 4례에서, 5cm이상인 14례중 3례에서 동반되어, 뇌동맥류는 뇌동정맥기형의 크기가 큰 예들에서 동반되는 율이 높았다($p<0.05$). 또한 총 동맥류 13개중 12개가 뇌동정맥 기형에 혈류를 공급하는 동맥의 근위부나 원위부에서 발견되었다.

치료는 한 예를 제외한 모든 예들에서 뇌동정맥기형을 제거하고 동시에 뇌동맥류를 결찰하였다. 한 예에서 편측 시력상실이 야기되었으나 다른 예들에서는 좋은 결과를 얻었으며 사망예는 없었다.

따라서 저자들의 경험에 의하면 뇌동맥류의 발생에 뇌혈류의 증가가 관여한다는 설이 타당하고 또한 뇌동맥류를 동반한 뇌혈관기형 환자들을 치료할 때 뇌동정맥기형을 수술시 뇌동맥류를 동시에 결찰하는 것이 좋다고 생각된다.

KEY WORDS : Aneurysm · Arteriovenous malformation · Cerebral blood flow.

---

*본 논문의 예중 1례의 수술장면은 1992년 The 3rd international workshop on cerebrovascular surgery (Tokyo)에서 video로 발표되었음.

*본 논문은 1993년 동산의료원 조사연구비 및 을종연구비의 보조로 이루어졌음.

Introduction

The coexistence of an intracranial arteriovenous malformation(AVM) and one or more intracranial aneurysms in a patient is unusual[1)4)7-9)14)15)18-21)23)26)30)]. It is known that approximately 1 to 2 percent of patients with an intracranial aneurysm also habor an intracranial AVM[10)26)], and about 10 percent of patients with an intracranial AVM also have an intracranial aneurysm[4)7-9)14)15)20)21)26)30)].

Some theories about the pathogenesis of the intracranial aneurysm in patients with an intracranial AVM have been proposed such as a hemodynamic stress induced by the AVM[3)11)13)15)19)21)22)24)27)29)30)], multiple congenital disorders of the cerebral vessels[2)9)19)25)27)28)] and incidental occurrence[5)22)23)].

Many authors agree with the opinion that the surgical treatment of these lesions should be directed first to the ruptured lesion[8)14)15)23)30)]. However, when it is difficult to know which one has ruptured preoperatively, some authors recommend clipping of the aneurysm prior to the resection of the AVM[4)17)], while other authors recommend treatment of the AVM only or surgical resection of the AVM prior to the clipping of the associated aneurysm[8)13)].

We reviewed 8 cases of intracranial AVM coexisting with aneurysm(s). The clinical characteristics of each was analyzed in comparision with patients who had AVM alone to obtain further knowledge about the pathogenesis of an intracranial aneurysm and the appropriate surgical management of patients with AVM combined with aneurysms(s).

Clinical Material and Methods

The records of all patients treated at our hospital from 1981 to 1993 under the diagnosis of intracranial vascular anomaly were reviewed. Patients with cavernous angioma, venous malformation, dural AVM and scalp AVM were excluded. The presence of intracranial aneurysm was determined by cerebral angiographic or operative findings. The patient with an aneurysm within the AVM was regarded as a case with AVM alone. Based on the maximal diameter on angiogram, AVMs were categorized as "small" if the diameter was less than 3cm, "medium" if 3 to 5cm, and "large" if greater than 5cm. The aneurysm site was classified according to the relationship between the artery harboring the aneurysms and the AVMs as follows : proximal on the feeding vessel ; distal on the feeding vessel ; remote site of the artery from the AVM.

The authors investigated the classified aneurysmal sites, and compared the mean age and the incidence of aneurysms according to the size of the AVMs between patients with AVM coexisting with aneurysm(s) and patients with AVM alone.

Results

1. Clinical summary of the patients with AVM coexisting with aneurysm(s)

Among 96 patients with intracranial AVM, 8 patients(8.3%) were identified as having 13 intracranial aneurysms(two patients had two aneurysms and one 4 aneurysms). There were six men and two women. The mean age at diagnosis was 44 years(ranged from 36 to 63 years). Six cases were presented with intracranial hemorrhage, one with headache, and one with seizure.

Among the 6 cases which were presented with intracranial hemorrhage, subarachnoid hemorrhage(SAH) was noted in four, intracerebral hemorrhage in one and intracerebellar hemorrhage in one. The SAHs were from the aneurysm in 2 cases, from the AVM in 3, and undetermined in 1. Two patients did not bleed.

Seven cases were treated surgically. Each AVM

and aneurysm in all cases was resected and obliterated by one operation. One case refused surgical treatment(case 1).

One patient(case 6) had a rebleeding episode about 7 months after the resection of the AVM and clipping of the aneurysm, and another patient (case 4) showed a remnant of the AVM on postoperative angiogram. The remnants of the AVMs in both cases were resected completely by the second operation.

Overall outcome was good in six patients. One patient had a mild memory disturbance and unilateral blindness(Table 1).

2. Characteristics of the AVM and aneurysm in patients with AVM coexisting with aneurysm (s)

Table 1. Clinical summary of AVM cases coexisting with aneurysm(s)#

	Age (year)	Sex	Presentation	Source of hemorrhage	Management	Result*
1	49	M	SAH	Unknown	Conservative	Good
2	45	M	SAH	AVM	Surgery	Good
3	63	M	Headache	None	Surgery	Good
4	39	M	ICH cbll	AVM	Surgery	Good
5	39	M	Seizure	None	Surgery	Good
6	37	F	SAH	Aneurysm	Surgery	Good
7	44	M	SAH	Aneurysm	Surgery	Moderate disability
8	34	F	ICH	AVM	Surgery	Good

abbreviation : cbll=cerebellum.

* : Glasgow outcome scale[16]

Table 2. Characteristics of the AVM and aneurysm#

	Aneurysm			AVM	
	No.	Site	Relation to AVM	Size*	Site
1	1	PICA. Lt.	Distal	6 cm	Cbll. Rt.
2	1	PICA. Rt.	Distal	4 cm	Cbll. Rt.
3	2	MCA. Lt.	Distal	2.5cm	Temporal. Lt.
4	1	PICA. Lt.	Distal	4 cm	Cbll. Rt.
5	1	MCA. Lt.	Distal	3 cm	Parietal. Lt.
6	1	Distal ACA. Rt.	Proximal	6 cm	Frontal. Rt.
7	4	Pcom, Acho, MCA. Lt., SCA. Rt.	Proximal	6 cm	Frontal. Lt.
8	2	Distal ACA. Rt.	Remote Distal	4 cm	Frontal. Rt.

* : Maximal diameter on the angiographic film.

# abbreviation : PICA=posterior inferior cerebellar artery.
MCA=middle cerebral artery.
ACA=anterior cerebral artery.
Pcom=posterior communicating artery.
Acho=anterior choroidal artery.
SCA=superior cerebellar artery.
Cbll=cerebellum.

Table 3. Comparison of the clinical characteristics between patients with AVM coexisting with aneurysm(s) and patients with AVM alone

	AVM alone(N=88)	AVM with aneurysm(s)(N=8)	
Mean age(year)	26.1± 13.8	44.0± 8.9	p=0.0004**
(range)	(1−62)	(36−63)	
Sex(M : F)	50 : 38	6 : 2	
Location			
Supratentorial	78	5	
Infratentorial	10	3	
Presentation			
Hemorrhage	76	6	
No hemorrhage	12	2	
Size*			
Small(N=56)	55	1(1.8%)	p=0.023***
Medium(N=23)	19	4(17.4%)	
Large(N=17)	14	3(17.6%)	

* : small ; <3cm, medium ; 3−5cm, large ; >5cm.
** : Mann-Whitney test. *** : chi-square test.

Aneurysm sites were PICA in 3 cases, middle cerebral artery(MCA) in 3, distal anterior cerebral artery(ACA) in 2, and posterior communicating artery(Pcom), anterior choroidal artery (Acho) and superior cerebellar artery(SCA) in 1 of each. In the relationship between the aneurysm and AVM, the aneurysms were located proximal on the feeding artery to AVM in 2 cases, distal on the feeding artery to AVM in 6 and remote site of the artery from the AVM in 1. Therefore, most aneurysms(88.9%) were located on the artery which related to the AVM hemodynamically. AVM sizes ranged from 2 to 6cm, and the AVM's locations were cerebellum in 3 cases, frontal lobe in 3, temporal and parietal lobe in 1 of each(Table 2)

3. Comparison of the clinical characteristics between the patients with AVM coexisting with aneurysm(s) and those with AVM alone

The mean age of the 8 patients with aneurysms was 44.0+8.9 years(range : 36−63 years), while that of the 88 patients without aneurysm was 26.1 +13.8 years(range : 1−62 years). The aneurysms were more likely to occur in the older patients($p<0.001$). Aneurysm was found in one out of 56 patients with a small AVM, in four out of 23 patients with a moderate-sized AVM and in three out of 17 patients with the larger AVM($p<0.05$)(Table 3).

Illustrative Case Reports

1. Aneurysm located proximal on the feeding artery to the AVM

Case 6 : This 36-year-old woman was admitted because of a sudden onset of headache in Hunt-Hess Grade II status. Computed tomographic (CT) scan revealed diffuse SAH. Cerebral angiography demonstrated a large AVM in the right frontal lobe and aneurysm on the distal ACA which fed the AVM(Fig. 1A). Total resection of the AVM and clipping of the aneurysm were carried out. It was confirmed that the source of hemorrhage was the aneurysm.

Postoperative course was uneventful, and a postoperative angiography showed complete obliteration of the aneurysm and no residual AVM(Fig. 1B).

About 8 months after the first operation, the patient was readmitted because of a sudden onset

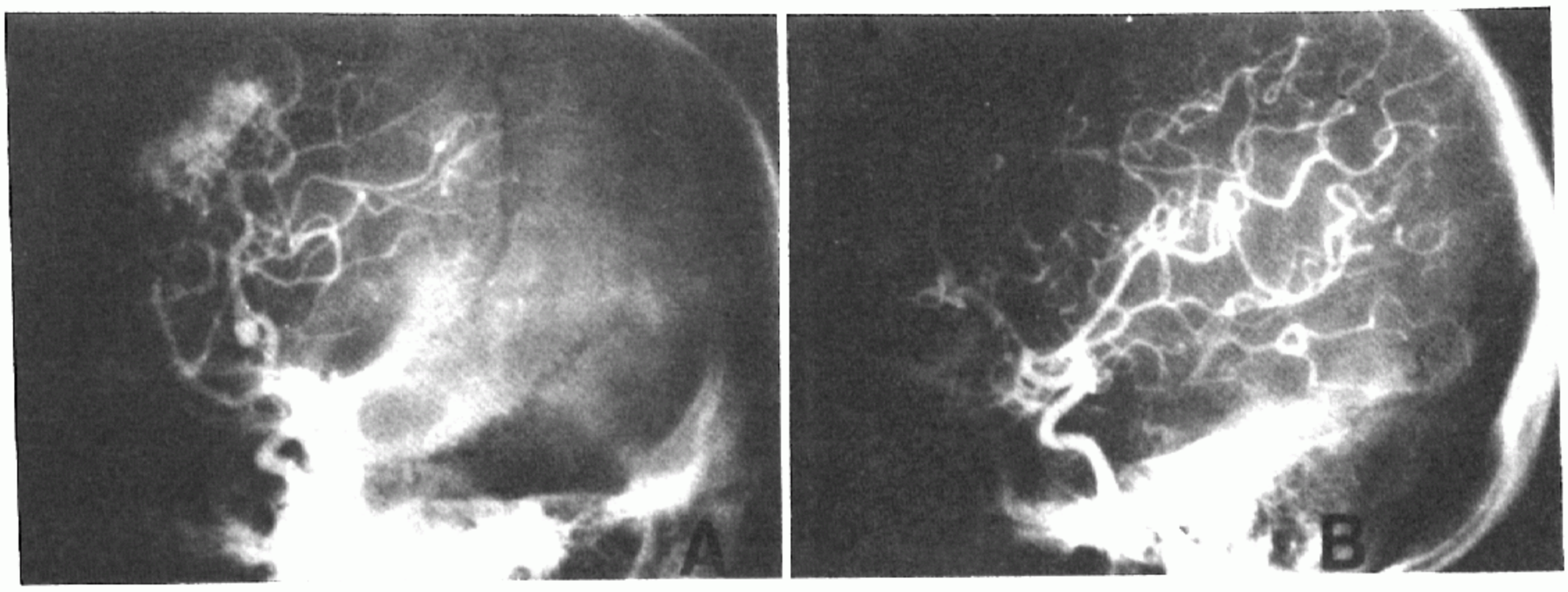

Fig. 1. A) Right ICA angiogram demonstrates a large AVM in the right frontal lobe and an aneurysm on the distal ACA which feeds the AVM.
B) Postoperative right ICA angiogram shows complete obliteration of the aneurysm and no residual AVM.

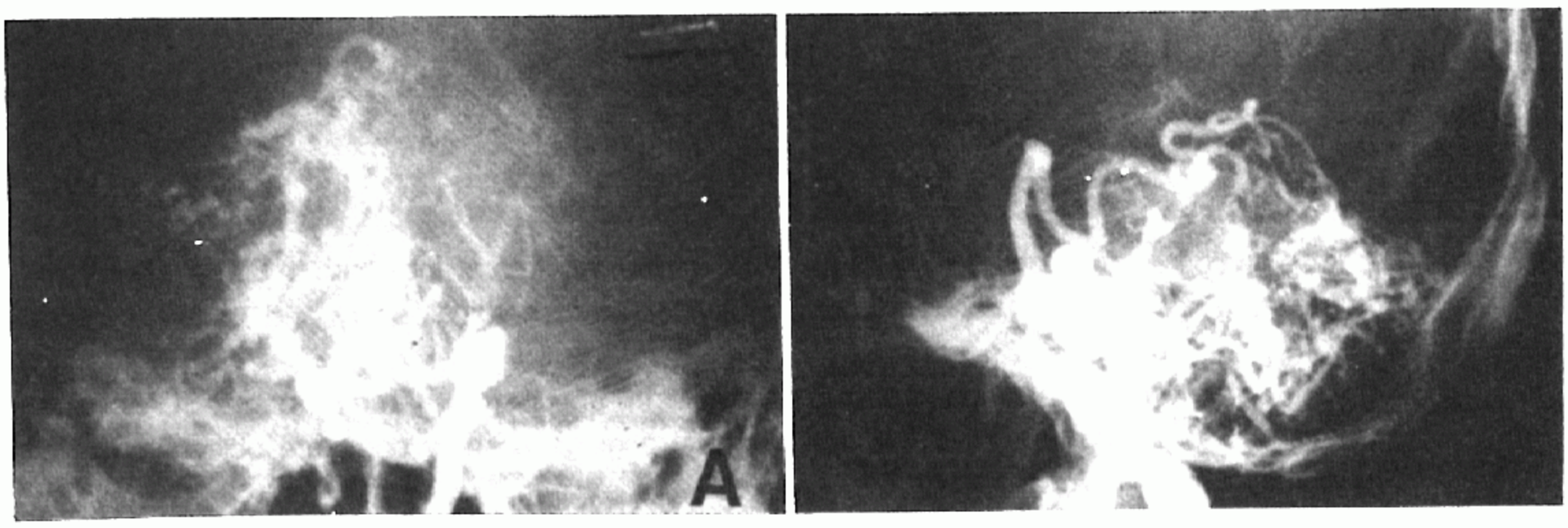

Fig. 2. A and B) Left vertebral angiogram, A-P and lateral view, demonstrate a large AVM in the right cerebellar hemisphere and an aneurysm at the left PICA which feeds the AVM mainly.

of headache. Brain CT demonstrated a small amount of intracerebral hematoma(ICH) at the previously resected site of the AVM. Even though a repeated cerebral angiography after the second hemorrhage did not demonstrate any evidence of the residual AVM, we found a small remnant of the AVM at the wall of the previous AVM site during the second operation. The patient recovered completely after the second operation without morbidity.

2. Aneurysm located distal on the feeding artery to the AVM

Case 1 : A 49-year-old man was admitted because of a sudden onset of headache, followed by a transient loss of consciousness, in Hunt-Hess Grade II status. Brain CT showed diffuse SAH. An angiography demonstrated a large AVM in the right cerebellar hemisphere and an aneurysm at the left PICA which mainly fed the AVM(Fig. 2A and B). It was hard to determine which, the AVM or the aneurysm, was the source of hemorrhage. The patient refused surgery and was followed up for 7 months after the SAH without further bleeding.

3. Aneurysm located at a remote site of the artery from the AVM

Case 7 : This 44-year-old man was admitted because of a sudden onset of bursting headache in Hunt-Hess Grade II status. The patient had a history of seizure, 2 or 3 times per year, for several

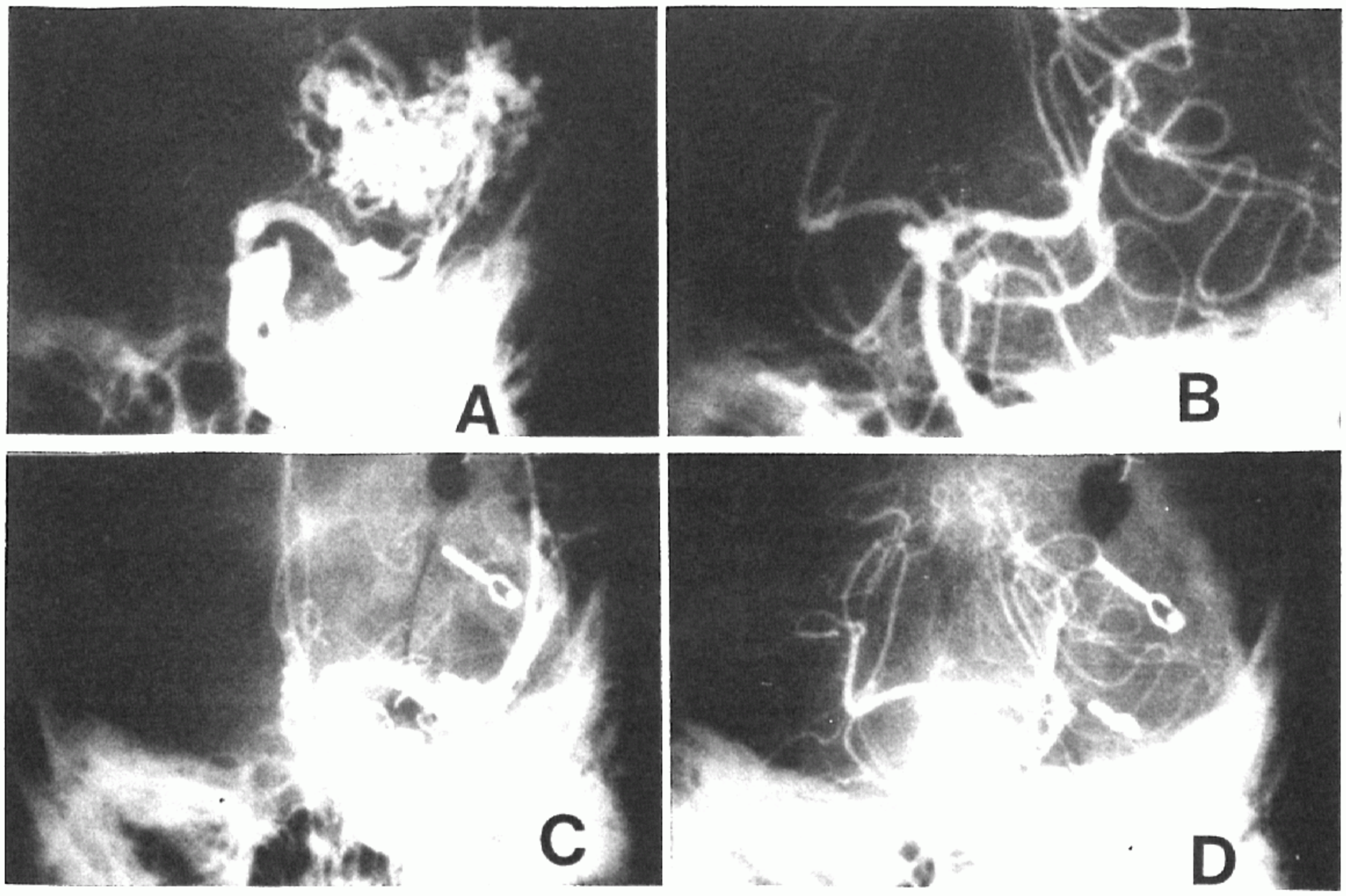

Fig. 3. A) Left ICA angiogram demonstrates a large AVM in the left frontal lobe and multiple aneurysms at the same side posterior communicating artery, anterior choroidal artery and middle cerebral artery.
B) A-P view of the vertebral angiogram shows another small aneurysm at the right basilar-SCA bifurcation site. C and D) Postoperative ICA and vertebral angiogram show complete obliteration of all aneurysms and no residual AVM.

years. Brain CT revealed thick SAH in the whole basal cistern. An angiography demonstrated a large AVM in the left frontal lobe and aneurysms at the same side Pcom, Acho and MCA. The left internal carotid artery(ICA) was enlarged and the AVM was fed by this enlarged ICA branch, such as lenticulostriate arteries and cortical branches of the MCA(Fig. 3A). Another aneurysm was found at the right basilar-superior cerebellar artery(SCA) bifurcation site, which was not involved in feeding arteries to the AVM(Fig. 3B). Total resection of the AVM and clipping of all the aneurysms during one operation were carried out with orbitozygomatic bone flap. It was confirmed that the source of hemorrhage was the rupture of the Pcom aneurysm. A postoperatively developed hematoma was removed again on the first postoperative day which occurred at the resected site of the AVM. Postoperative angiography showed complete obliteration of all the aneurysms and no residual AVM(Fig. 3C and D). The patient was discharged with mild memory disturbance and left visual loss. His memory deficit improved remarkably during the follow-up period. However, the visual loss in the left eye persisted without improvement.

Discussion

The coexistence of an intracranial AVM and an aneurysm is relatively rare[4)7-9)10)15)20)21)26)30)] Hyun et al[15)] reported four cases of coexisting AVM and aneurysm in a total of 67 patients with AVM. Lasjaunias et al[20)] found 23 cases of aneur-

ysm in their series of 101 patients with cerebral AVM. Other authors[4)7-9)21)26)30)] reported the incidence of its occurrence as between 6% to 23% in patients with AVM. The incidence of its occurrence in this study was 8.3%.

There are several case reports of the combination of AVM and aneurysm in the posterior fossa because these authors[14)18)19)23)28)] thought its occurrence was very rare. However, Cunha e Sa et al[8)] reported a high incidence of posterior circulation aneurysm(25 aneurysms in a total 64 aneurysms) in their 400 patients with AVM and Fox[10)], after reviewing the literature, suggested that the incidence of AVM combined with aneurysm in the posterior fossa might be higher than earlier thought. In our series, we found 3 cases in the posterior fossa among a total of 8 cases.

The incidence of presentation with bleeding in patients with AVM coexisting with aneurysm varies from 41%[4)] to 66.7%[30)].

Cunha e Sa et al[8)] reported the incidence of this presentation was 62% in their 39 patients. In view of the source of hemorrhage, some authors reported that an aneurysm was more frequently the source of hemorrhage than AVM[4)8)12)15)], while other authors reported the AVM was more frequent[9)26)]. Still other authors reported the incidence of the source of the hemorrhage between AVM and aneurysm was similar in both[6)30)].

Hyun et al[15)] reported the bleeding was caused by an aneurysm rupture in all their cases and Derupty et al[9)] reported AVM was the source of hemorrhage in all their cases. In our series, six of the eight cases were presented with hemorrhage. The hemorrhage was thought to have originated from the AVM in three cases, from aneurysm in two and unknown in one.

As to the pathogenesis of aneurysm in patients with AVM, three theories have been proposed i.e., a hemodynamic stress by the increased blood flow through the arterial feeders of the AVM[3)11)13)15)19)21)22)24)27)29)30)], multiple congenital disorders of the cerebral vessels[2)9)19)25)27)28)] and incidental occurrence[5)22)23)]. Several authors reported various evidences which supported the hemodynamic theory[13)19)29)]. Hayashi et al[13)], Koulouris and Rizzoli[19)], and Shenkin et al[29)] reported cases which showed decreasing size or disappearance of aneurysms on feeding arteries to AVMs after surgical resection of the AVMs. Lasjaunias et al[20)] described 16 cases which showed regression of proximal aneurysms on the feeding arteries to AVMs after obliteration of the AVMs by embolization. Azzam[3)] reported new development of aneurysms in a case which had been diagnosed as harboring an AVM 3 years before, and Fuwa et al[11)] reported an enlargement of a small aneurysm during an eleven year period in a case with AVM.

Many authors also supported the hemodynamic theory with evidence that, in patients with aneurysm and AVM, a high percentage of the aneurysm was located on arteries which related to the AVM anatomically or hemodynamically[4)8)13)15)21)24)30)]. The age of the patients with aneurysm was older and the size of the AVM of the patients with aneurysm was larger than those with AVM alone[21)].

On the other hand, some authors[2)9)27)28)] support the theory of the multiple congenital vascular anomalies with evidence that some aneurysms in the AVM patients were found on the vessels which did not have any relationship to the AVM hemodynamically. They mentioned that the hemodynamic theory was hardly applicable to such cases and cases in which the lesions were located separately in a different hemisphere. Salpietro et al[27)] also supports this theory with a case report in which a large intracavernous aneurysm was revealed eighteen years after the spontaneous disappearance of a cerebral AVM. In our series, almost ninety percent(88.9%) of aneurysms were located on the arteries which related to the AVMs hemodynamically and one aneurysm was located at a

remote site of the artery from the AVM. The mean age of the patients with aneurysm(s) was older and the sizes of the AVMs of the patients with aneurysms was larger than those of the patients without aneurysm. Therefore, our results also support the hemodynamic theory strongly and the theory of the multiple congenital vascular anomalies to some degree.

There is no controversy in the management of patients with a combination of aneurysm and AVM that the aneurysms and/or the AVMs should be obliterated by surgical, endovascular or radiosurgical methods. Brown et al[6] studied 16 patients with AVM coexistant with unruptured aneurysm to estimate the risk of hemorrhage. They estimated the risk of hemorrhage to be 7% during the first year and the risk persisted at 7% per year for 5 years. They concluded that the risk of hemorrhage was higher in these patients than patients with AVM alone. Perret and Nishoka[25] also demonstrated higher mortality in the cases which were managed conservatively than in the cases which were managed surgically in the patients with AVM coexisting with aneurysm.

There is also no controversy that obliteration of the lesion should be directed first to the lesion which ruptured. However, when it is difficult to know which one has ruptured preoperatively, controversy exists. Betjer et al[4], and Kaech et al[17] gave the opinion that treatment of aneurysm should be preceded by the resection of the associated AVM because hemodynamic changes following the abrupt elimination of an AVM may increase the risk of a rupture of the associated aneurysm. Hayashi et al[13], Cunha e Sa et al[8] and Koulouris and Rizzoli[19] gave their opinion that the AVM only should be treated or should be done prior to the surgical obliteration of the associated aneurysm because aneurysms could disappear or decrease in size after total excision or obliteration with embolization of the AVM alone. Noterman et al[23], Kikuchi et al[18] and Suzuki and Onuma[30] recommended a one-stage operation for both lesions and Fox[10] presented his case which was managed by this policy. In our series, we were not able to determine which lesions were the source of the hemorrhage in 3 cases preoperatively(case 4, 6, 7). We made a bone flap to cover both lesions and managed them by a one-stage operation. We recommend the aneurysm should be treated first in the case where it is not possible to obliterate both lesions by a one-stage operation because the effects of bleeding or rebleeding from the aneurysm rupture are more malignant than those of bleeding from the AVM rupture or rerupture.

The results of surgical management in patients with AVM coexistant with aneurysm were good in documented cases in the noted literature[8)9)13-15)18-20)23)28-30] even though Batjer et al[4] reported a 26% operative mortality. We also obtained satisfactory results in all cases without mortality.

Conclusion

The authors reviewed 8 cases of AVM coexisting with aneurysm(s), and analyzed the clinical characteristics of each in comparision with the cases of AVM alone.

The incidence of this combination was 8.3% of all AVM patients. Almost ninety percent(88.9%) of the aneurysms were located on the arteries which related to the AVMs hemodynamically, and the mean age and the sizes of the AVMs of these cases tended to be older and larger than those of patients with AVM alone. Total removal of the AVMs and clipping of the aneurysms were performed in one-stage operations in all cases except one. Favorable results were obtained in all cases with no mortality. In conclusion, the increased blood flow through the arterial feeders of the AVM is likely to contribute to the development of an aneurysm and the procedure of choice in patients with AVM coexisting with aneurysm is

a radical operation aimed at total excision of the AVM and obliteration of the aneurysm.

References

1) Aarabi B, Chambers J : *Giant thrombosed aneurysm associated with an arteriovenous malformation. Case report. J Neurosurg 49 : 278-282, 1978*
2) Anderson RM, Blackwood W : *The association of arteriovenous angioma and saccular aneurysm of the arteries of the brain. J Path Bact 77 : 101-110, 1959*
3) Azzam CJ : *Growth of multiple peripheral high flow aneurysms of the posterior inferior cerebellar artery associated with a cerebellar arteriovenous malformation. Neurosurgery 21 : 934-939, 1987*
4) Batjer H, Suss RA, Samson D : *Intracranial arteriovenous malformations associated with aneurysms. Neurosurgery 18 : 29-35, 1986*
5) Boyd-Wilson JS : *The association of cerebral angiomas with intracranial aneurysms. J Neurol Neurosurg Psychiat 22 : 218-223, 1959*
6) Brown RD, Wiebers DO, Forbes GS : *Unruptured intracranial aneurysms and arteriovenous malformations : frequency of intracranial hemorrhage and relationship of lesions. J Neurosurg 73 : 859-863, 1990*
7) Cronqvist S, Troupp H : *Intracranial arteriovenous malformation and arterial aneurysm in the same patient. Acta Neurol Scandinav 42 : 307-316, 1966*
8) Cunha e Sa MJ, Stein BM, Solomon RA, et al : *The treatment of associated intracranial aneurysms and arteriovenous malformations. J Neurosurg 77 : 853-859, 1992*
9) Deruty R, Mottolese C, Soustiel JF, et al : *Association of cerebral arteriovenous malformation and cerebral aneurysm. Diagnosis and management. Acta Neurochir(Wien) 107 : 133-139, 1990*
10) Fox JL : *Concurrent intracranial aneurysm and arteriovenous malformation, in Wilkins RH, Rengachary SS(eds) : Neurosurgery update II. Vascular, spinal, pediatric, and functional neurosurgery. New York : McGraw-Hill, 1991, pp126-128*
11) Fuwa I, Matsukado Y, Kaku M, et al : *Enlargement of a cerebral aneurysm associated with ruptured arteriovenous malformation. Acta Neurochirurgica 80 : 65-68, 1986*
12) Gács G, Vinuela F, Fox AJ, et al : *Peripheral aneurysms of the cerebellar arteries. Review of 16 cases. J Neurosurg 58 : 63-68, 1983*
13) Hayashi S, Arimoto T, Itakura T, et al : *The association of intracranial aneurysms and arteriovenous malformation of the brain. Case report. J Neurosurg 55 : 971-975, 1981*
14) Higashi K, Hatano M, Yamashita T, et al : *Coexistence of posterior inferior cerebellar artery aneurysm and arteriovenous malformation fed by the same artery. Surg Neurol 12 : 405-408, 1979*
15) Hyun YI, Jung HT, Kang JK, et al : *Intracranial arteriovenous malformation associated intracranial aneurysms. J Kor Neurosurg Soc 22 : 139-143, 1993*
16) Jennett B, Bond M : *Assessment of outcome after severe brain damage. A practical scale. Lancet 1 : 480-484, 1975*
17) Kaech D, Tribolet N, Lasjaunias P : *Anterior inferior cerebellar artery aneurysm, carotid bifurcation aneurysm, and dural arteriovenous malformation of the tentorium in the same patient. Neurosurgery 21 : 575-582, 1987*
18) Kikuchi K, Kowada M, Yoneya M : *Association of arteriovenous malformation and intracranial aneurysm in the posterior fossa. Surg Neurol 22 : 499-502, 1984*
19) Koulouris S, Rizzoli HV : *Coexisting intracranial aneurysm and arteriovenous malformation. Case report. Neurosurgery 8 : 219-222, 1981*
20) Lasjaunias P, Piske R, Terbrugge K, et al : *Cerebral arteriovenous malformations(C. AVM) and associated arterial aneurysms(AA). Analysis of 101 C. AVM cases, with 37 AA in 23 patients. Acta Neurochir(Wien) 91 : 29-36, 1988*
21) Miyasaka K, Wolpert SM, Prager RJ : *The association of cerebral aneurysms, infundibula, and intracranial arteriovenous malformations. Stroke 13 : 196-203, 1982*
22) Nehls DG, Carter LP : *Multiple unusual aneurysms and arteriovenous malformation in a single patient : A case report. Neurosurgery 17 : 97-100, 1985*
23) Noterman J, Georges P, Brotchi J : *Arteriovenous malformation associated with multiple aneurysms in the posterior fossa : A case report with a review of the literature. Neurosurgery 21 : 387-391, 1987*

24) Okamoto S, Handa H, Hashimoto N : *Location of intracranial aneurysms associated with cerebral arteriovenous malformation : statistical analysis. Surg Neurol 22 : 335-340, 1984*

25) ϕstergaard JR : *Association of intracranial aneurysm and arteriovenous malformation in childhood. Neurosurgery 14 : 358-362, 1984*

26) Perret G, Nishioka H : *Report on the cooperative study of intracranial aneurysms and subarachnoid hemorrhage. Arteriovenous malformations : An analysis of 545 cases of cranio-cerebral arteriovenous malformations and fistulae reported to the cooperative study. J Neurosurg 25 : 467-490, 1966*

27) Salpietro FM, Cipri S, Tomasello F, et al : *Late onset of a large cavernous aneurysm after spontaneous disappearance of cerebral arteriovenous malformation. Case report. J Neurosurg Sci 33 : 211-214, 1989*

28) Santucci N, Gazzeri G, Tamorri M : *Association of two saccular aneurysms of the posterior inferior cerebellar artery with a cerebellar arteriovenous malformation fed by the same artery. J Neurosurg Sci 29 : 109-112, 1985*

29) Shenkin HA, Jenkins F, Kim K : *Arteriovenous anomaly of the brain associated with cerebral aneurysm. Case report. J Neurosurg 34 : 225-228, 1971*

30) Suzuki J, Onuma T : *Intracranial aneurysms associated with arteriovenous malformations. J Neurosurg 50 : 742-746, 1979*