TECHNICAL NOTE

J Korean Neurosurg Soc 41 : 347-351, 2007

# New Technique for Surgery of Petrous Apex Cholesterol Granuloma

Eal maan Kim, M.D., Ph.D.,[1] Sung-Il Nam, M.D., Ph.D.[2]

*Departments of Neurosurgery,[1] Otorhinolaryngology,[2] Skull Base Surgery Division, Dongsan Medical Center, Keimyung University School of Medicine, Daegu, Korea*

The authors present a new technique for surgery of cholesterol granuloma (CG) at the petrous apex. An epidural middle fossa approach is used to expose and remove the cyst, with silicon tube drainage into the sphenoid sinus via the anterolateral cavernous sinus triangle between the first and second divisions of the trigeminal nerve. This novel method is less invasive skull base approach to the petrous apex and very effective for minimizing recurrence of CGs within the petrous apex.

**KEY WORDS :** Petrous apex · Cholesterol granuloma · Surgical technique · Skull base surgery · Drainage.

## Introduction

Cholesterol granulomas (CGs) of the petrous apex are result of inadequate aeration and drainage of petrous air cells within the temporal bone, which in turn leads to repeating cycle of mucosal thickening, intracystic bleeding, foreign body reaction, and granuloma formation[6,9]. These extradural benign lesions have traditionally been treated by either otological conservative procedures or radical resection by some neurosurgeons[5,8]. However, because both approaches have high recurrence rates and a notable surgical morbidity rates[2], the optimal surgical treatment of these deep-seated skull base lesions is still not established.

The authors developed a new technique, middle fossa extradural approach and stenting the drainage tube into the sphenoid sinus, that provides safe access to and simple drainage of the petrous apex CGs. The controversies in choosing the appropriate surgical approach to CGs in the petrous pyramid will be discussed.

## Operative Technique

The patient is put under general anesthesia and lumbar drain is placed in the usual fashion. Facial nerve electrodes are then placed on the right side of the face prior to positioning. The patient is secured in the supine position with the head turned to the left. The right scalp is prepped and draped in a sterile fashion. A scalp incision starts just in front of the tragus, extends superiorly for 6-7 cm. The incision slants posteriorly and then anteriorly. The scalp flap is elevated, and the temporalis muscle is cut and then dissected away from the middle fossa.

A burr hole is made in the inferotemporal region and a 4-cm craniotomy is performed. The inferior rough of the craniotomy is drilled down to the middle fossa floor. At this point, lumbar drain is opened and drained to reduce the degree of temporal dura retraction necessary. Middle fossa dura is detached from the superior surface of the temporal bone. Anteriorly, the middle meningeal artery is cauterized and divided above the foramen spinosum. The second landmark of middle fossa dissection, the arcuate eminence is identified medially and posteriorly in elevating the temporobasal dura. Further dural elevation is then carried out posterior to anterior, protecting the greater superficial petrosal nerve exiting from the facial hiatus with aid of the facial nerve monitoring. Putting surgeon's attention to the cavernous sinus lateral wall, extradural dissection proceeds anteriorly and medially until the foramina of ovale and rotundum are exposed. The lateral dural wall of cavernous sinus is then dissected and elevated free from the trigeminal roots and ganglion. A self-retaining retractor is then applied. The surgeon continues extradural dissection down demonstrating

• Received : November 21, 2006 • Accepted : March 28, 2007
• Address for reprints : Eal maan Kim, M.D., Ph.D., Department of Neurosurgery, Skull Base Surgery Division, Dongsan Medical Center, Keimyung University School of Medicine, 194 Dongsan-dong, Jung-gu, Daegu 700-712, Korea Tel : +82-53-250-7823, Fax : +82-53-250-7356, E-mail : bach1158@dsmc.or.kr

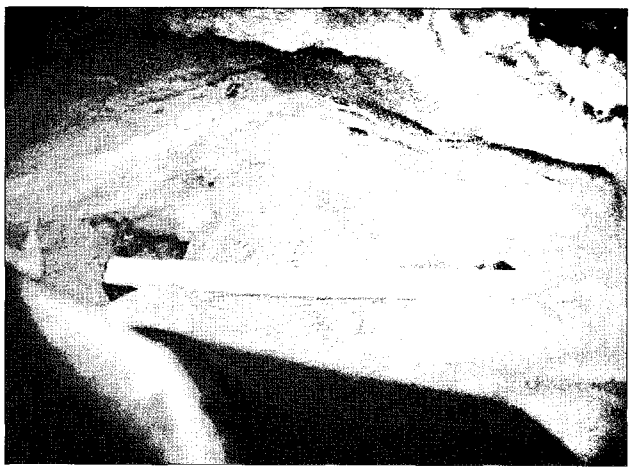

**Fig. 1.** Intraoperative photography of the left-sided cadaveric head showing the extradural middle fossa approach and drainage procedure for cholesterol granuoloma of the petrous apex. Note the silicone catheter running from the petrous apex into the hole between V1 and V2 nerve roots.

the Kawase's triangle which defines the portion of the petrous apex. Petrous apex CGs are usually located in Kawase's posteromedial triangle. Care is taken to recognize any brownish discoloration of the bone while the dura is elevated further medially. The triangular area between the porus trigeminus, the cochlea, and the mandibular nerve is drilled out. If a thin bony diaphragm is still present, that is a usual in cases of expanding cystic lesions, a window is created using the high-speed air drill and a diamond burr. Care must be taken to avoid entering the carotid canal which lies laterally in the triangle and be often bony dehiscent. Because these large processes, as a rule, have partially eroded the carotid canal, circumferential exposure of the vessel is readily achieved. Extensive process may have already eroded the floor of the middle fossa, therefore the cochlea posteromedial to this triangle should also be protected during additional bony resection. Depending on the size of the CGs and degree of petrous erosion, additional bony drilling and dissection can be adjusted.

Usually, the surrounding bone is quite thin and eroded by an expanding CGs at this area. Having drilling and dissection done, the granuloma cyst is located and entered, then its content is aspirated and the pseudocapsule is incised. The cavity can be then inspected for possible fragments of the solid component with a dental mirror or an endoscopic probe. In general, it is not possible to resect radically the cyst wall in its entirety because of its anatomic complexity and tight attachment to surrounding vascular and neural structures in this region. Consequently, at this point, the cyst needed to be stented open into the sphenoid sinus. The ophthalmic and maxillary divisions of the trigeminal nerve are dissected, exposing the anteromedial triangle of the cavernous sinus, and then a small hole is made into the sphenoid sinus via this triangle. A silicon tube is then placed within the cyst cavity with other end in the sphenoid

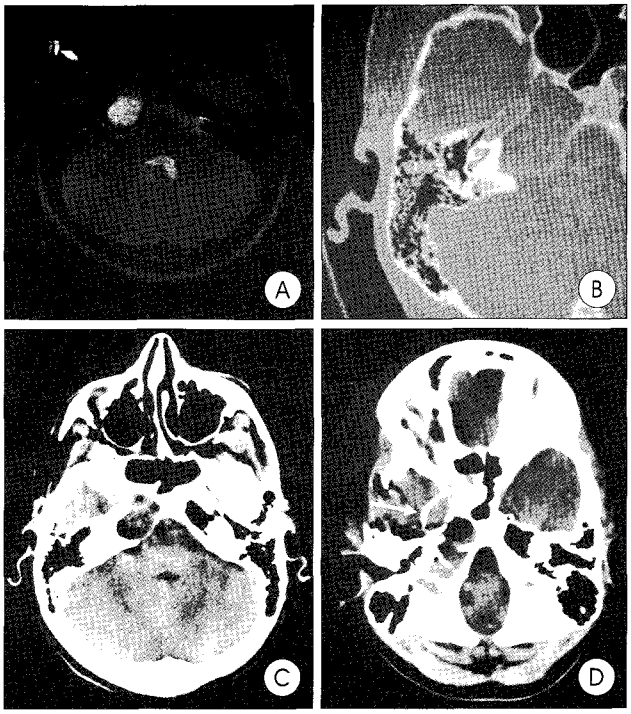


**Fig. 2.** Preoperative magnetic resonance images and computed tomography (CT) scan of a large petrous apex cholesterol granuloma. A homogenously hyperintense cystic lesion on the T2-weighted (A) images and well-marginated erosion in the tip of the right petrous apex (B) is noted. A hypodense oval-shaped cyst is demonstrated on the admission CT scan (C). Postoperative CT reveals the silastic catheter (arrow) which extends into the right sphenoid sinus (D).

sinus, and it is secured the dura overlying the cavernous sinus and trigeminal ganglion (Fig. 1). Meticulous hemostasis is obtained and the wound is irrigated copiously. Several dural take-up sutures are made entire temporal region, and the bone flap is placed back in position and secured with microplates. Temporalis muscle and scalp are then closed in usual fashion, and a lumbar drain is removed at the end of the procedure.

## Case Illustration

This 25-year-old woman presented with symptoms of headache and right eye pain about two years. Findings on physical examination of the head and neck and cranial nerves were normal. Magnetic resonance (MR) imaging demonstrated a cystic lesion at the right petrous apex that was bright signal on T1- and T2-weighted images (Fig. 2A). Computed tomography (CT) findings were typical of a hypodense expansile lesion in the temporal bone. The mass was posterior and directly adjacent to a prominent horizontal part of the petrous cartoid artery (Fig. 2B, C). For surgical removal of this cyst, we used the epidural middle fossa approach instead of the transspehnoidal route to obtain better control over the petrous carotid artery. She underwent a right middle fossa approach to the petrous apex with drainage of the CG without any

complications, as previously described. The lesion occupied the petrous pyramid that was easily identified by the presence of dark material within the mass. It was exposed as widely as possible then incised and the brown-oily cyst contents aspirated and flushed out. An attempt was made to radically remove the cyst wall adhering to the bone, but was abandoned when it was noted that internal auditory canal, facial nerve, and carotid artery were skeletonized within the cyst. After removing of the surrounding epithelium subtotaly, a silastic stent was placed into the cyst and brought out into the spehnoid sinus for drainage and aeration (Fig. 2D). Biopsy of the cyst wall revealed granulomatous inflammation, cholesterol crystals, and hemosiderin deposits. Postoperatively, her headaches resolved, and trigeminal, facial, and vestibulocochlear nerves were functionally intact. The patient has been recurrence-free for more than two years clinically and radiologically.

## Discussion

Petrous apex CGs are an unusual, but distinct clinical entity that mimic lesions more commonly discovered in the cerebellopontine angle, making the exact diagnosis difficult at times[11]. Before choosing the surgical approach to these lesions, it is important to differentiate CGs from cholesteatoma, mucocele, epidermoid, and other vascular, neoplastic, and infectious processes. As shown in the case presented, CG of the petrous apex has a quite characteristic MR signal intensity[15], so that MRI appears to be the technique of choice in the correct diagnosis of CGs and in the follow-up of previously treated patients.

Clinical presentations of CGs in petrous apex are those of an expanding lesions within the temporal bone and cerebellopontine angle, and include aural fullness, temporal headache, tinnitus, ear pain, discharge, vertigo, diplopia, trigeminal neuralgia, facial numbness, and hearing loss[1,10]. In cases of nonaggressive petrous apex CGs, when symptoms are stable or improving, the patients can be safely followed with serial clinical examination and MR imaging.

The lack of ventilation in pneumatized bone has been considered as a main etiology of CGs formation, so that the drainage and permanent aeration is a goal in surgery of petrous apex CGs[2,3]. In addition, because CGs lack a distinct epithelial lining, complete excision of lesion is rarely indicated, and it has historically treated with a drainage procedure via otorhinological approaches[7,13]. The transsphenoidal drainage is the procedure of choice for CGs abutting or prolapsing into the sphenoid sinus[12]. Among the otological procedures for drainage of apical cystic lesions, the most commonly used surgical approaches are the transcanal subcochlear and infralabyrinthine approaches. These techniques are useful for the patient with serviceable hearing when the lesion can not be approached anteriorly. The subcochlear route has become a popular approach in recent years for the drainage of petrous apex CGs[8,13]. Merits of this approach include preservation of inner ear anatomy through an inferior myringotomy, the shortest route to reach the lesion, and dependent drainage to the mastoid sinus. It can also be done in the patient of high jugular bulb that obstruct the infralabyrinthine approach. For the large petrous apex lesions, transcochlear and translabyrinthine approaches can be used in the patients with no usable hearing, and both approaches allow greater exposure of the lesion and direct access for aeration from mastoid through surgical defect to petrous apex[14]. However, these approaches destroying the hearing and balancing are rarely required for benign primary apical cysts, and also are not practical because many CGs patients have good vestibulo-cochlear nerve function.

Most rhino-otologists have preferred the conservative surgery for petrous apex CGs with or without placement of draining tube. Their transmatoid or transsphenoidal approach is fast and simple, and recovery from operation is also rapid. A long-term control of symptoms and signs could be also provided in the selected cases. However, unfortunately, a limited surgical exposure and increased risk of stenosis of the drainage fistula are common shortcoming of both techniques[7,8,10]. Most recurrences have been reported to be caused by closure of the draining tract by fibrosis, new bone formation or granulation tissue occurring around the stent[12-14]. This major drawback of drainage procedures have resulted in a relatively high rate of cyst recurrence, with several patients requiring multiple revisions. In addition, because of its pathological nature and content consistency, simple drainage through the relatively small opening is inadequate for preventing reaccumulation of cholesterol cysts[3,5]. But, as shown in our modified technique, we tried to excise most portion of the cyst wall and empty the cavity, and then put the ventilating tube into the residual cavity so as to reestablish aeration. With maintaining the patency of draining tube, this approach could make lesion recurrence less likely because the tubing allow adequate ventilation of the petrous apex after radical resection of the CGs.

Interestingly, half of a clinically significant CGs were treated by neurosurgeons, and suboccipital, petrosal, and middle cranial fossa approaches have been reported in the neurosurgical literature[1,4,5,15]. They advocated complete excision of granuloma capsule because the cyst drainage through the fenestration that is generally only a few millimeters large are inadequate. Some otolaryngologists have also proposed a transcranial approach to a lesion considered inaccessible via a lateral one because the apex remains the least accessible portion of the petrous bone from a lateral approach[2,3]. The posterior approach i.e., retromastoid suboccipital, requires cerebellar retraction and

does not establish external drainage. Furthermore, contamination of the subarachnoid space by the cyst contents may induce an aseptic meningitis. The posterior petrosal approach is too extensive and inappropriate for this benign non-neoplastic extradural cyst. As a consequence, middle fossa approach have been commonly used by neurosurgeons and neurootologists, but this approach does not allow adequate aeration of the petrous apex after drainage of the cyst. Therefore, using middle fossa approach, a few authors have tried to completely remove the granuloma and its pseudocapsule and to prevent reaccumulation by obliterating the resultant space with temporalis muscle or abdominal fat[1,4,5]. There are reports on successful treatment of petrous apex CGs through a middle fossa approach, those underline the efficacies of the transcranial radical surgery compared with alternative drainage procedures. For our patient, we also discussed the transsphenoidal versus the middle fossa approach to lesion. Imaging showed only a small bony window at the posterior wall of the sphenoid sinus immediately adjacent to sphenoid septum, which inserts in front of the petrous carotid artery. Therefore, to reach the CG, we chose the safer middle fossa approach. The middle fossa approach has the following advantages: 1) ability to open a bone window in a region devoid of eloquent structures; 2) direct and shallow access to the petrous apex lesion; 3) minimum temporal lobe retraction and extradural dissection; 4) circumferential exposure and complete resection of the lesion with minimized recurrence; 5) early exposure and control of the carotid artery; 6) preservation of hearing and balance; 7) complementary use of endoscopy to allow a view of the blind corner; and 8) keeping ventilation of petrous air cells by placing draining tube into the sphenoid sinus. However, there are several risks from radical resection and drainage surgery for apex CGs via a middle fossa approach[2,3,15]. First, total or near total resection through the middle fossa has risk of hearing loss if the surgeon accidently enters the cochlea or internal auditory canal. Second, an inadvertent penetration of the carotid artery may potentially complicate the unroofing of the carotid canal especially in cases of cysts that extend inferiorly or surround the carotid artery. Third, the basal dura in petroclival region investing the cisternal portion of the CGs is very thin, therefore any energetic dissection of the pseudocapsule in this region should be avoided because its penetration may be complicated by a cerebrospinal fluid fistula. Forth, a substantial distortion of the dura carries the risk of a mechanical injury to the cranial nerves running over its dorsal surface. For these reasons, no attempt was made to remove calcified remnants of the pseudocapsule adherent to the dura in our patients. Fifth, with opening of sphenoid sinus, there is risk of ascending intracranial infection, and so that the patients with sinusitis are not candidate for this technique.

Small remnants of the capsule, left in place to avoid potential complications, seem not to affect the long-term outcome of the patients if the cavity in the petrous bone is ventilated adequately[1,2]. Drainage of CGs through the middle fossa approach into the mastoid cells may prove difficult to establish, due to the difficulty encountered in placing the stent. Based on both concepts, the authors have modified the traditional middle fossa approach, with more anterior extradural dissection to the cavernous sinus, and drained anteriorly the cyst into the sphenoid sinus leaving small remnants of cyst wall on the adjacent structures. A scheduled follow-up is important to detect early signs of recurrence in the patients of subtotally resected CGs. Despite its some limitation for estimating the tube patency, the intrasphenoid sinus inspection using nasal endoscope can be useful for the follow-up in the outpatient clinic. Furthermore, in patients with no recurrence of the preoperative symptoms, use of fluoroscopy is also mandatory for checking displacement of the drainage tube. We believe that an extensive cyst resection and subsequent drainage of petrous apex CGs can offer good long-term control with minimal morbidity from surgery.

## Conclusion

The authors believe that middle fossa craniotomy, subtotal excision, and creating drainage route to the sphenoid sinus can be easily accomplished, and is considered as a relatively safe, and viable skull base technique during surgery for the petrous apex CGs.

### References


1. Bockmuhl U, Khalil HS, Draft W : Clinicoradiological and surgical considerations in the treatment of cholesterol granuloma of the petrous pyramid. **Skull Base 15** : 263-267, 2005
2. Brackmann DE, Toh EH : Surgical management of petrous apex cholesterol granulomas. **Otol Neurotol 23** : 529-533, 2002
3. Brodkey JA, Robertson JH, Shea JJ III, Gardner G : Cholesterol granuloma of the petrous apex : combined neurosurgical and otological management. **J Neurosurg 85** : 625-633, 1996
4. Cristante L, Puchner MAJ : A keyhole middle fossa approach to large cholesterol granulomas of the petrous apex. **Surg Neurol 53** : 64-71, 2000
5. Eisenberg MB, Haddad G, Al-Mefty O : Petrous apex cholesterol granulomas : evolution and management. **J Neurosurg 86** : 822-829, 1997
6. Gherini SG, Brackmaan DE, Lo WW, Solti-Bohman LG : Cholesterol granuloma of the petrous apex. **Laryngoscope 95** : 659-664, 1985
7. Ghorayeb BY, Jahrsdoerfer RA : Subcochlear approach for cholesterol granulomas of the inferior petrous apex. **Otolaryngol Head Neck Surg 103** : 60-65, 1990
8. Giddings NA, Brackmann DE, Kwartler JA : Transcanal infracochlear approach to the petrous apex. **Otolaryngol Head Neck Surg 104** : 29-36, 1991
9. Goldofsky E, Hoffman RA, Holliday RA, Cohen NL : Cholesterol cysts of the temporal bone : diagnosis and treatment. **Ann Otol Rhinol Laryngol 100** : 181-187, 1991
10. Graham MD, Kemink JL, Latack JT, Kartush JM : The giant cholesterol cyst of the petrous apex : a distinct clinical entity. **Laryngoscope 95** : 1401-1406, 1985
11. Greenberg JJ, Oot RF, Wismer GL, Davis KR, Goodman ML, Weber

AE, et al : Cholesterol granuloma of the petrous apex : MR and CT evaluation. **AJNR 9** : 1205-1214, 1988
12. Griffith AJ, Terrell JE : Transsphenoid endoscopic management of petrous apex cholesterol granuloma. **Otolaryngol Head Neck Surg 114** : 91-94, 1996
13. Jaramillo M, Windle-Taylor PC : Large cholesterol granuloma of the petrous apex treated via subcochlear drainage. **J Laryngol Otol 115** : 1005-1009, 2001
14. Mosnier I, Cyna-Gorse F, Grayeli AB, Fraysse B, Martin C, Robier A, et al : Management of cholesterol granulomas of the petrous apex based on clinical and radiologic evaluation. **Otol Neurotol 23** : 522-528, 2002
15. Terao T, Onoue H, Hashimoto T, Ishibashi T, Kogure T, Abe T : Cholesterol granuloma in the petrous apex : case report and review. **Acta Neurochir (Wien) 143** : 947-952, 2001