대한중환자의학회지 : 제 11 권 제 1 호
Vol. 11, No. 1, June, 1996

Noncardiogenic Pulmonary Edema and Dilutional Hyponatremia Secondary to Intrauterine Instillation of 2.7% Sorbitol During Hysteroscopy

– A case report –

Deog Jae Kim, M.D. and **Jin Mo Kim**, M.D.

Department of Anesthesiology, Keimyung University, School of Medicine, Taegu, Korea

= 국문초록 =

자궁경 검사시 2.7% Sorbitol의 자궁내 점적주입으로 인한 비심인성 폐부종과 희석성 저나트륨 혈증

– 증례 보고 –

계명대학교 의과대학 마취과학교실

김 덕 재 · 김 진 모

자궁경 검사시 자궁강을 팽창시키고 수술 표면을 세척하고 시야를 좋게 하기 위하여 2.7% sorbitol 세정 용액의 지속적 주입이 필요한데 이 2.7% sorbitol 용액의 많은 양이 혈관내로 흡수되어 저산소혈증, 대사성 산증, 저나트륨 혈증, 폐부종, 적혈구 용혈과 응고이상등 합병증을 유발시킬 수 있다.

최근 자궁경을 이용한 수술이 계속 증가하는 추세이며 합병증의 발생은 치명적일 수 있다. 본 증례는 장궁경 검사시 2.7% sorbitol의 자궁내 주입후 비심인성 폐부종과 희석성 저나트륨 혈증이 발생한 예이며, 이런 합병증의 잠재성과 사용되는 감시장치의 불충분함을 다시한번 강조하고 이에 대한 치료를 함께 보고하고자 한다.

핵심용어: 비심인성 폐부종, 희석성 저나트륨 혈증, 자궁경 수술

CASE REPORT

A 45 year-old, 65 kg, para 1-0-1-1 woman who had uterine myoma, was scheduled for hysteroscopic myomectomy. Her past medical history, physical examination and chest X-ray (Fig. 1) were unremarkable. Vital signs and preoperative routine laboratory findings were normal.

Preoperative medication consisted of nalbuphine 10 mg and glycopyrrolate 0.2 mg intramuscularly. The procedure was done under general anesthesia maintained with nitrous oxide/oxygen, enflurane, fentanyl, and vecuronium bromide.

After induction of general anesthesia, the hysteroscope was connected to an infusion bag which contatined 2.7% sorbitol urological irrigating solution. Approximately 7,000 ml of irrigating solution under hydrostatic pressure of 80 ~100 mmHg were infused to distend and irrigate the uterus over the course of 1 hour.

Most of the irrigant returned back through the cervix or was suctioned out of the abdomen. She received 900 ml of lactated Ringer's solution given intravenously during the procedure. Blood loss was 200 ml and urine output was 1, 800 ml. After resection time of approximately 70 minutes, peak airway pressure increased form 18 to 35 cmH_2O, and followed by decrease in arterial oxygen saturation determined by pulse oximeter from 99% to 81% on F_IO_2 of 0.5 within 5 minutes.

The anesthesiologist noted frothy fluid from the endotracheal tube. The hysteroscopic resection procedure was discontinued. Physical examination revealed coarse rales throughout both lungs, generalized edema, but no heart murmur.

Chest X-ray revealed bilateral pulmonary edema (Fig. 2). Arterial blood gas data were pH 7.12, $PaCO_2$ 56 mmHg, PaO_2 61 mmHg, HCO_3^- 18. 1 mEg/L. Electrolytes, blood chemistries, prothrombin time and partial thromboplastin time were normal except decreased serum sodium and potassium of 109.5 mmol/L and 2.1 mmol/L, respectively.

The central venous pressure was 23 mmHg. The patient remained intubated for use of positive end expiratory pressure(15 cmH_2O). The patient was given with intravenous furosemide. 20 mEq potassium chloride was administered intravenously to correct potassium depletion. For the correction of the hyponatremia, the intravenous infusion was changed from lactated Ringer's solution to 0.9% sodium chloride, and 1,000 ml was given over 30 minutes.

After treatment, serum sodium concentration

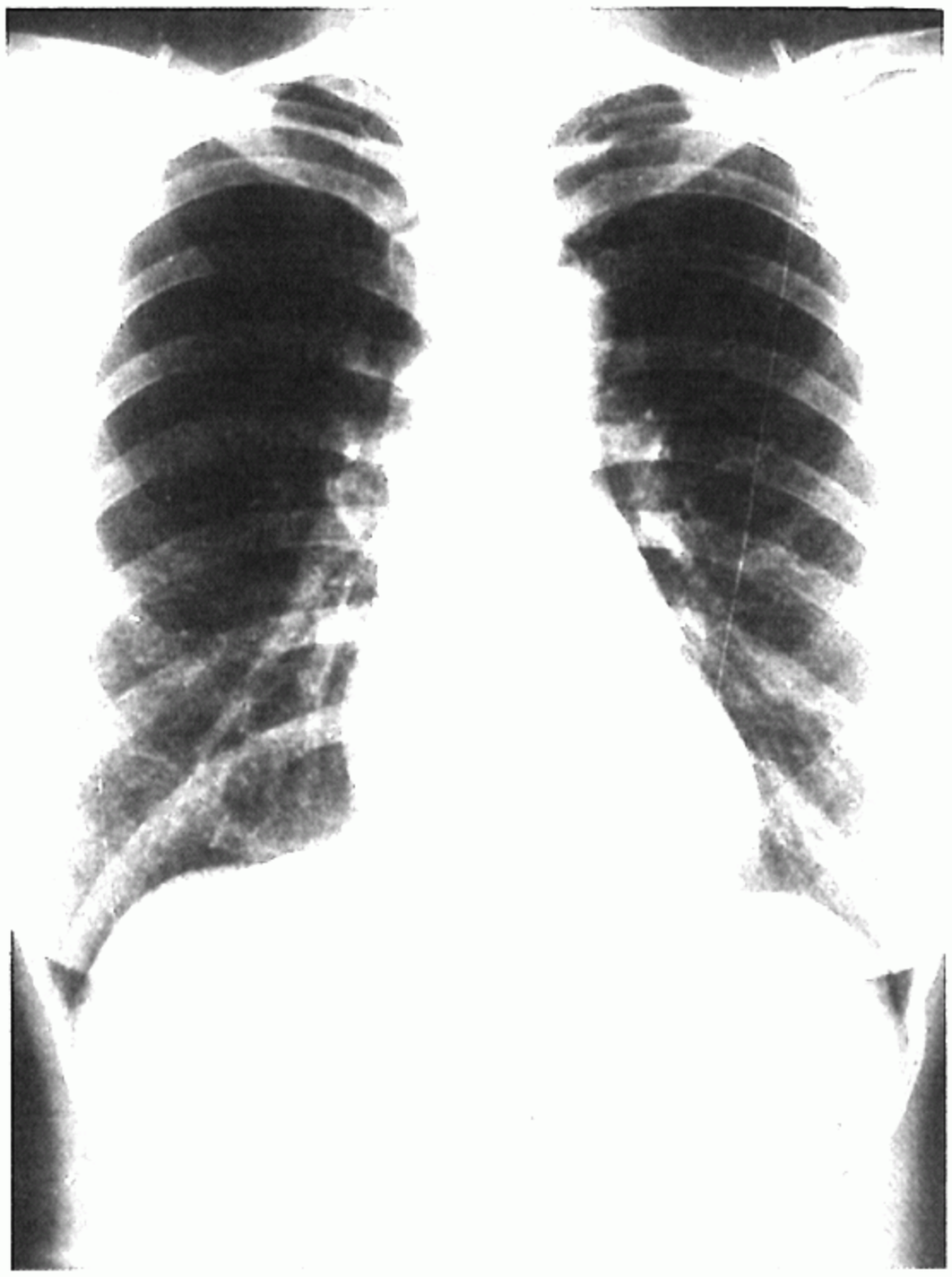

Fig. 1. Posteroanterior X-ray view of chest before operation. No definite abnormality in both lungs and heart.

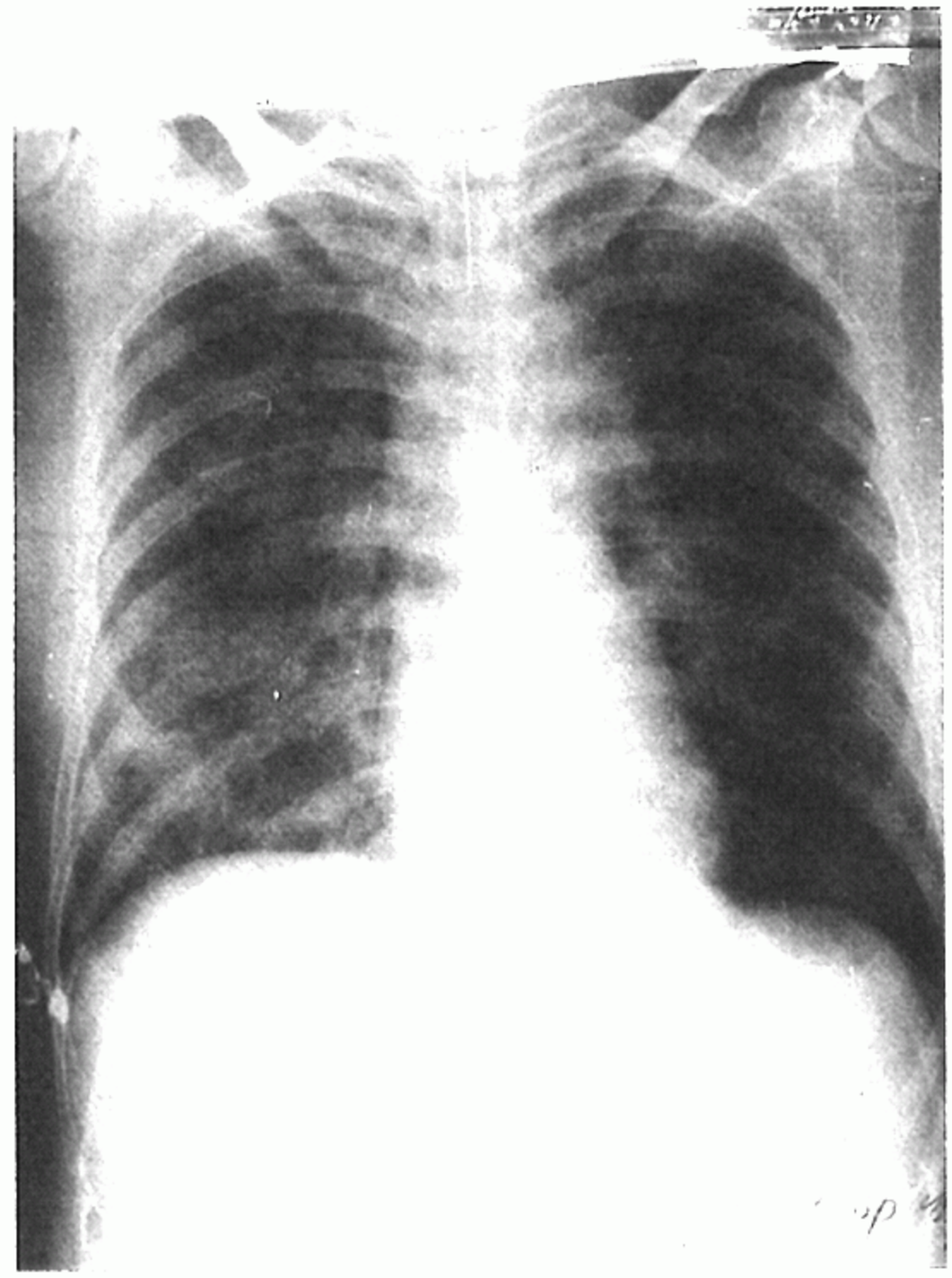

Fig. 2. Anteroposterior X-ray view of chest during operation revealed multiple amorphous alveolar consolidations on both lungs.

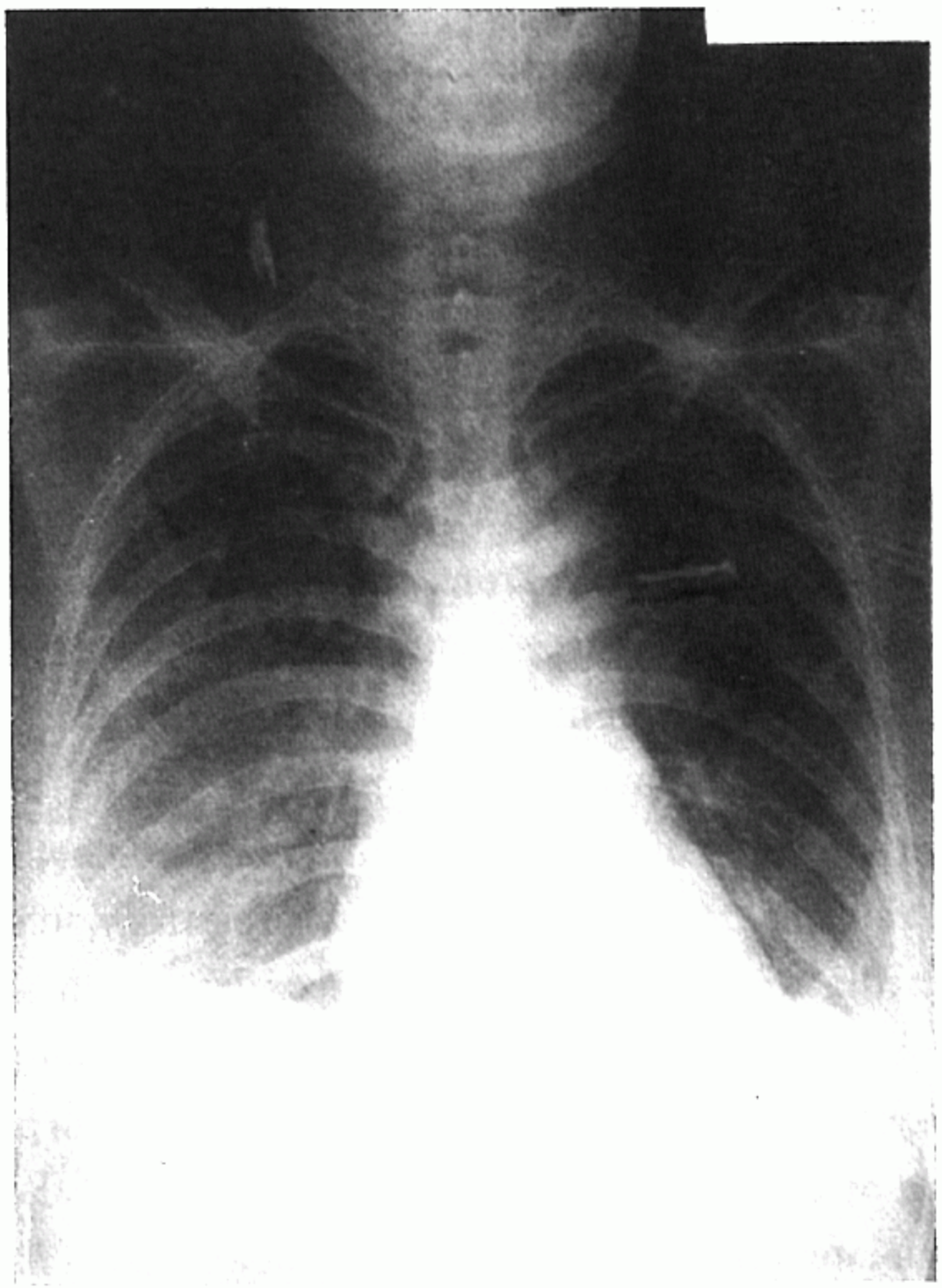

Fig. 3. Anteroposterior X-ray view of chest 12 hours after the management in intensive care unit revealed much cleared previous alveolar consolidations, but bilateral pleural effusions were noticed.

was 115.8 mmol/L. Urine output increased to 500 ml/h. The central venous pressure decreased to 12 mmHg. Arterial blood gas on 15 cmH_2O-PEEP and F_IO_2 of 0.7 showed pH 7.32, $PaCO_2$ 37 mmHg, PaO_2 160 mmHg, HCO_3^- 19.2 mEq/L.

A second 1000 ml intravenous bolus of 0.9% NaCl was infused over the ensuing 30 minutes. Thereafter serum sodium and potassium concentration were 120.5 mmol/L and 2.9 mmol/L, respectively. The patient was transferred to the intensive care unit. Serial chest X-rays and physical examination showed progressive improvement of the pulmonary edema over the next 12 hours (Fig. 3).

After the close observation in the intensive care unit for 24 hours, the patient was extubated when an arterial blood gas on F_IO_2 of 0.4 showed pH 7.40, PaO_2 35.0 mmHg, PaO2 100.6 mmHg, HCO_3^- 23.1 mEq/L. The patient was transferred to the general ward on the second postoperative day with a serum sodium concentration of 145 mmol/L, a serum potassium concentration of 3.6 mmol/L, and arterial blood gas on room air of pH 7.42, $PaCO_2$ 41.2 mmHg, PaO_2 143 mmHg, HCO_3^- 25.3 mEq/L.

DISCUSSION

The 2.7% sorbitol is indicated for use with the hysteroscopy as an aid in distending the uterine cavity and in irrigating and visualizing its surface. However, use of 2.7% sorbitol has problems. Several liters of fluid can be absorbed over the couse of hysteroscopic proceduce. The rapid intravascular absorption of 2.7% sorbitol can cause acute hyponatremia, red blood cell hemolysis, disseminated intravascular coagulation, anaphylaxis, and pulmonary edema[3]. The amount absorbed is dependent on the injection pressure, the tissue trauma, the seal of the hysteroscope around the cervix, and the duration of infusion.

Pulmonary edema has been reported with irrigating fluid infusion volumes ranging from 150 to 1200 ml[4~6]. This is believed to result from intravascular absorption. In this patient, central venous catheter monitoring showed a CVP of 23 mmHg from which we concluded fluid overload. The pulmonary edema was not cardiogenic because there was no abnormal finding on auscultation and ECG.

Some investigators recommend limiting the procedures to be done in less than 45 minutes using less than 500 ml[4~6] and not to exceed an infusion pressure of 150 mmHg. In this case a

large volume of irrigating fluid (7,000 ml) under hydrostatic pressure of 80~100 mmHg is used for more than 1 hour.

Dilutional hyponatremia is a well known complication during hysteroscopic procedures, and it occurs because of absorption of irrigating fluid. In the majority of patients, hyponatremia is mild and asymptomatic. However, severe symptomatic hyponatremia (serum sodium concentration<120 mmol per liter) may be associated with permanent neurologic damage or death[7]. In this case the patient did not exhibit any of the electrocardiographic changes typically associated with hyponatremia, such as ST-segment depression, widening of the QRS complex, loss of the P wave, or bradycardia. Excessively slow therapy appears to result in increased mortality[7,8], and excessively rapid treatment may result in the development of central pontine myelinolysis or other demyelinationg lesions of the brain[9]. Rapid correction of severe hyponatremia by administration of hypertonic saline until level of mild hyponatremia is not harmful and is not associated with clinical or radiologic neurologic damage. On the other hand, it is possible that rapid conversion of hyponatremia to normonatremia or hypernat-remia may produce demyelinationg lesions of brain. Depending on the cause and relative total sodium and water content, treatment can range from administration of hypertonic saline or mannitol (with or without diuretic drugs) to restriction of fluids or administration of other drugs[10].

Once hyponatremia is diagnosed, treatment consists of an increase in serum concentration at a rate not to exceed 2 mmol/L/h[11,12] in order to avoid circulatory failure or central pontine myelinolysis[7]. After the serum sodium concentration becomes 125 mmol/L, therapy may consist of water restriction.

In summary, to avoid possible complications with 2.7% sorbitol irrigating solution, the ammount of irrigating fluid used should be noted continuously. Unfortunately the systemic absorption of this fluid can not be predicted accurately for each procedure.

The anesthesiologist recommends careful monitoring of the infusion pressure which should not exceed 150 mmHg in order to prevent excessive fluid from entering the uterine vasculature, to diminish entry into the peritoneal cavity, and to limit the duration of the procedure and the infusion volume. One should be alert to signs of impending pulmonary edema, i. e., rales, increase in peak airway pressure, tachycardia and decreased arterial oxygen saturation. Frequent estimations of serum sodium may be of value in detection excessive absorption of the irrigating fluid and in preventing the development of dilutional hyponatremia. In high risk patients with depressed myocardial function from valvular heart disease and prosthetic heart valves taking anticoagulants, intraoperative arterial and pulmonary arterial pressure or central venous pressure monitoring should be considered.

REFERENCES

1) Pantaleoni D. *On endoscopic examination of the cavity of the wormb. The Medical Press and Circular 1969; 8: 26-27.*

2) Baggish MS. *Distending media for panoramic hysteroscopy. In: Baggish MS, Barbot, Valle RRF. Diagnostic and Operative Hysteroscopy: A Text and Atlas, Chicago: Yearbook Medical Publishers 1989; 89-93.*

3) Marx GF, Orkin LR. *Complications associated with transurethral surgery. Anesthesiology 1982; 23: 802.*

4) Zebella EA, Moise J, Caisan SA. *Noncardiogenic pulmonary edema secondary to intrauterine instillation of 32% dextran 70. Fertil Steril 1985; 43: 479-480.*

5) Leake, Murphy AA, Zacur HA. *Noncardiogenic pulmonary edema: a complication of operative hysteroscopy. Fertil Steril 1987; 48: 497-499.*
6) Lukacsko P. *Noncardiogenic pulmonary edema secondary to intrauterine instillation of 32% dextran-8-(Letter). Fertil Steril 1985; 44: 560-561.*
7) Atus JC, Krothapalli RK, Arieff AI. *Changing concepts in treatment of severe hyponatremia; rapid correction and possible relation in central pontine myelinolysis. Am J Med 1985; 78: 897-902.*
8) Arieff AL. *Hyponatremia, convulsion, respiratory arrest, and permanent brain damage after elective surgery in healthy women. N Engl J Med 1986; 314: 1529-1535.*
9) Norenberg MD, Leslie KO, Robertson AS. *Associating between rise in serum sodium and central pontine myelinolysis. Am Neurol 1982; 11: 128-135.*
10) Sterns RH. *Severe symptomatic hyponatremia; treatment and outcome. Ann Intern Med 1987; 107: 656.*
11) Narins RG. *Therapy of hyponatremia; dose haste make waste? N Engl J Med 1986; 314: 1573-1575.*
12) Covery CM, Arieff AI. *Disorders of sodium and water metabolism and their effects on the central nervous system. In: Brenner BM, Stein JH. Contemporary issuse in nephrology, sodium and water homeostasis. New York: Churchill Libingstone. 1978; 212-241.*