

The skeletal cortical anchorage using titanium microscrew implants

Hyo Sang Park¹⁾

Anchorage plays an important role in orthodontic treatment. Endosseous implants may be considered adequate firm anchorage. However, clinicians have hesitated to use endosseous implants as orthodontic anchorage because of limited implantation space, high cost, and long waiting period before osseointegration occurs.

Recently, some clinicians have tried to use titanium miniscrews and microscrews in treatment due to their many advantages such as ease of insertion and removal, low cost, immediate loading, and the ability to place microscrews in any area of alveolar bone.

The author treated a case with skeletal cortical anchorage using titanium microscrew implants. During six months of orthodontic force application from skeletal cortical anchorage, the author could get 4 mm bodily retraction and intrusion of upper anterior teeth. The most outstanding result was a 1.5 mm posterior retraction of the upper posterior teeth. The titanium microscrew implants had remained firm and stable throughout treatment.

These results indicate that skeletal cortical anchorage might be a very good option.

Key word : Skeletal cortical anchorage, Titanium microscrew implants

In orthodontic therapy, anchorage plays a crucial role. There are two categories in discussing anchorage: intraoral and extraoral. Intraoral derived anchorage is unstable, necessitating appliances which can be complicated, inefficient, and often require the extraction of dental units. On the other hand, extraoral appliances can be quite stable but depend on the patient's cooperation. In order to provide acceptable anchorage for orthodontic appliances, endosseous implants have been suggested and used.^{12,14)} But their use for orthodontic anchorage has been limited by space, economy, and time lag between implantation and orthodontic force application.

Recently, Kanomi⁸⁾ and Costa et al³⁾ have introduced the use of titanium microscrews as orthodontic anchorage. The advantages of the microscrews are that they are small enough to place in any area of alveolar bone, ease of implantation and removal, low cost, and the short interval between implantation and orthodontic force application.

Herein, the author presents a case report of treatment with skeletal cortical anchorage using titanium microscrew implants for retracting upper anterior teeth and discusses the clinical considerations.

CASE

The patient was a 12-year-old boy whose chief complaints were upper protrusion and crowding.

¹⁾ Department of Orthodontics Dentistry, College of Medicine, Keimyung University,

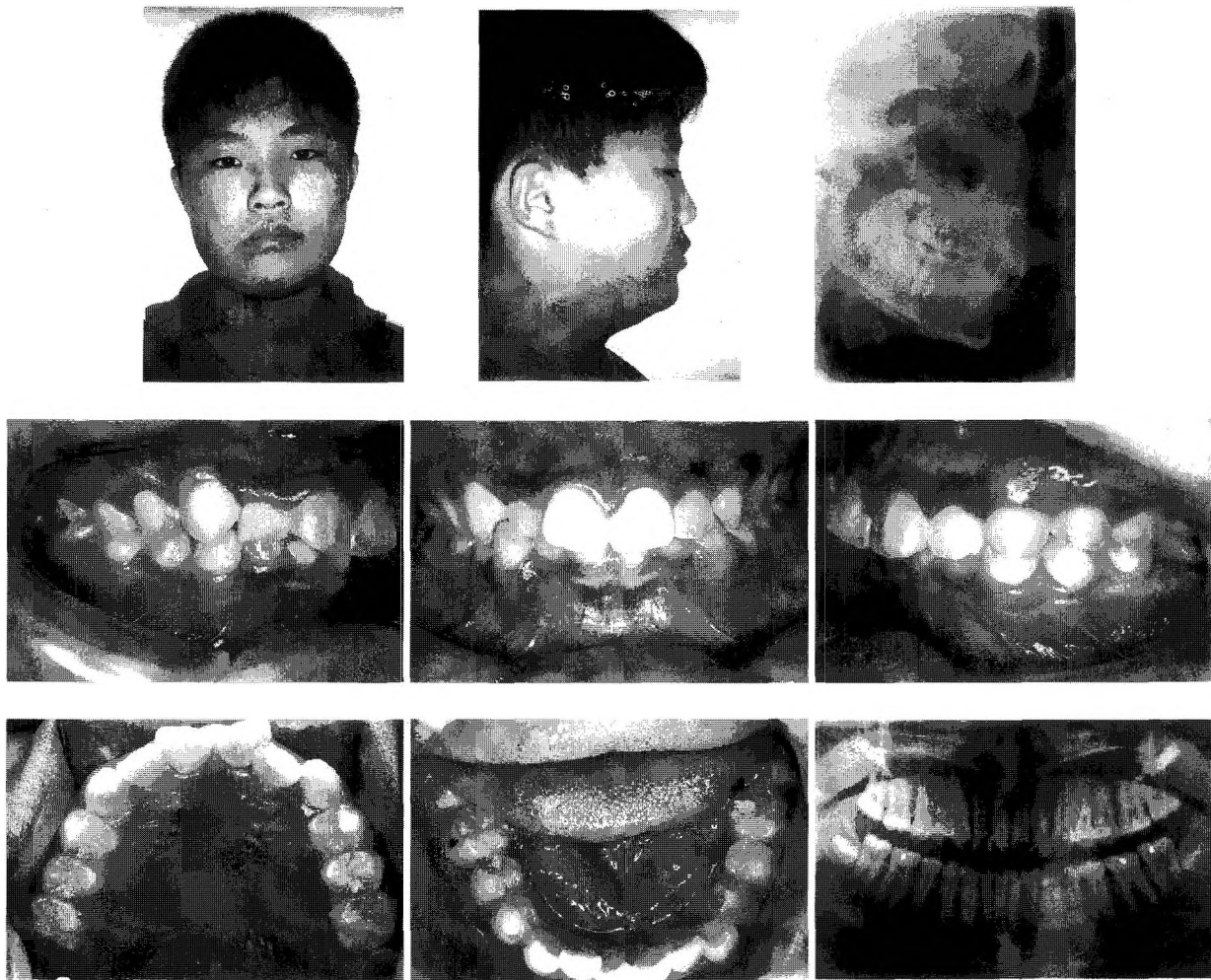


Fig. 1. Initial facial photos, lateral cephalometric radiograph, intraoral photos, and panoramic radiograph.

1. Diagnosis

1) Extraoral findings

The patient had a straight profile. The lateral photo showed protrusion of upper and lower lips and curved mentolabial fold (Fig. 1).

2) Intraoral findings

The patient showed Class II canine and molar relationships. The over-jet, overbite, and curve of Spee were 6 mm, 5 mm, 2 mm, respectively. The patient had moderate arch length deficiency (upper arch, 4.5 mm : lower arch, 4 mm) (Fig. 1).

3) Cephalometric analysis (Table 1)

The cephalometric measurements revealed the skeletal Class I with deep bite.

2. Treatment

1) Treatment plan

For the relief of upper crowding, extraction of upper first premolars and lower second premolars was planned. The anterior bite plate was utilized to extrude lower posterior teeth and enhance mandibular growth.

Table 1. Summary of cephalometric measurements.

Measurements	Pretreatment	microcrew implantation	Posttreatment
Skeletal			
SNA	80.5	80	80
SNB	79.5	80	80.5
ANB	1	0	-0.5
FMA	27	27	27
Y-axis	62	62.5	62.5
Dental			
FH to UI	117.5	115	114
IMPA	93.5	86	82.5
FH to occlusal plan	7	7.5	4.5
Interincisal angle	122	133	136.5
Soft tissue			
Z-angle	75.5	76.5	80.5
Upperlip to E-line	1.5	-0.5	-3
Lowerlip to E-line	1	0.5	-2

2) Treatment progress

After extraction, edgewise appliances were bonded and banded. In order to relieve anterior crowding, upper canines were retracted by power chain between canine and upper first molar. The patient was instructed to wear anterior bite plate full time and wear Class II elastics.

After 13 months of treatment, the author decided to implant titanium microcrew implants, skeletal cortical anchorage, to intrude and retract upper anterior teeth, because of lack of patient's cooperation.

* Surgical procedure

Under local anesthesia, a stab incision was made on the alveolar mucosa between upper second premolar and first molar. A small pit (1.5 mm) was made by round bur under water cooling, and a mucoperiosteal flap was opened. Drilling was performed with 1 mm drill under water cooling. Titanium microcrew (Leibinger Co, Germany), 6 mm in length and 1.2 mm in diameter, was inserted by screwdriver (Fig. 2). Three periapical radiographs were taken to evaluate whether microcrew was placed well between adjacent roots or not.

One month after microcrew implantation, orthodontic force was applied. NiTi coil spring was ligated between titanium microcrew and hook, which was soldered on main archwire between upper lateral incisor and canine (Fig. 2). The force was approximately 150 gm on each side. The total treatment time was 20 months including 6 months of orthodontic force application from titanium microcrew implants.

3) Treatment result

The good facial harmony was obtained by superoposterior movement of upper anterior teeth segment, anterior repositioning and enhanced growth of mandible (Fig. 3 and Fig. 4).

The upper anterior teeth showed 4 mm bodily posterior and intrusive movement during orthodontic force application from skeletal cortical anchorage. The upper posterior teeth moved backward 1.5 mm (Fig. 5).

The FH to occlusal plane was changed from 7.5 to 4.5 during skeletal cortical anchorage treatment resulting from intrusion of upper anterior teeth. The panoramic radiograph showed good root paralleling.

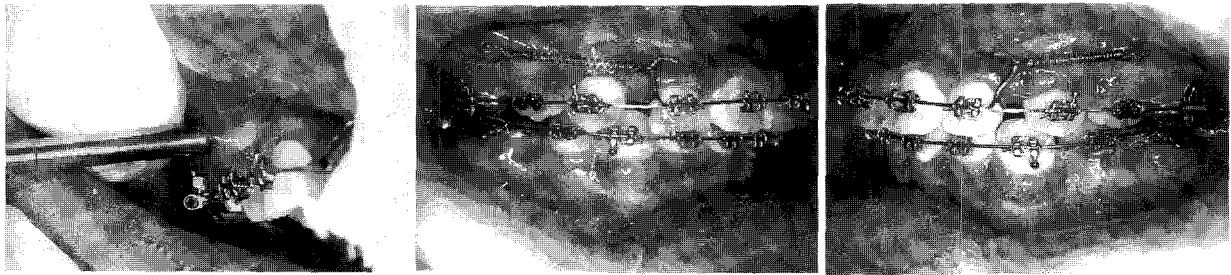


Fig. 2. Intraoral photos showing implanting titanium microscrew with screwdriver, and orthodontic force application by NiTi coil spring from skeletal cortical anchorage to upper anterior teeth.

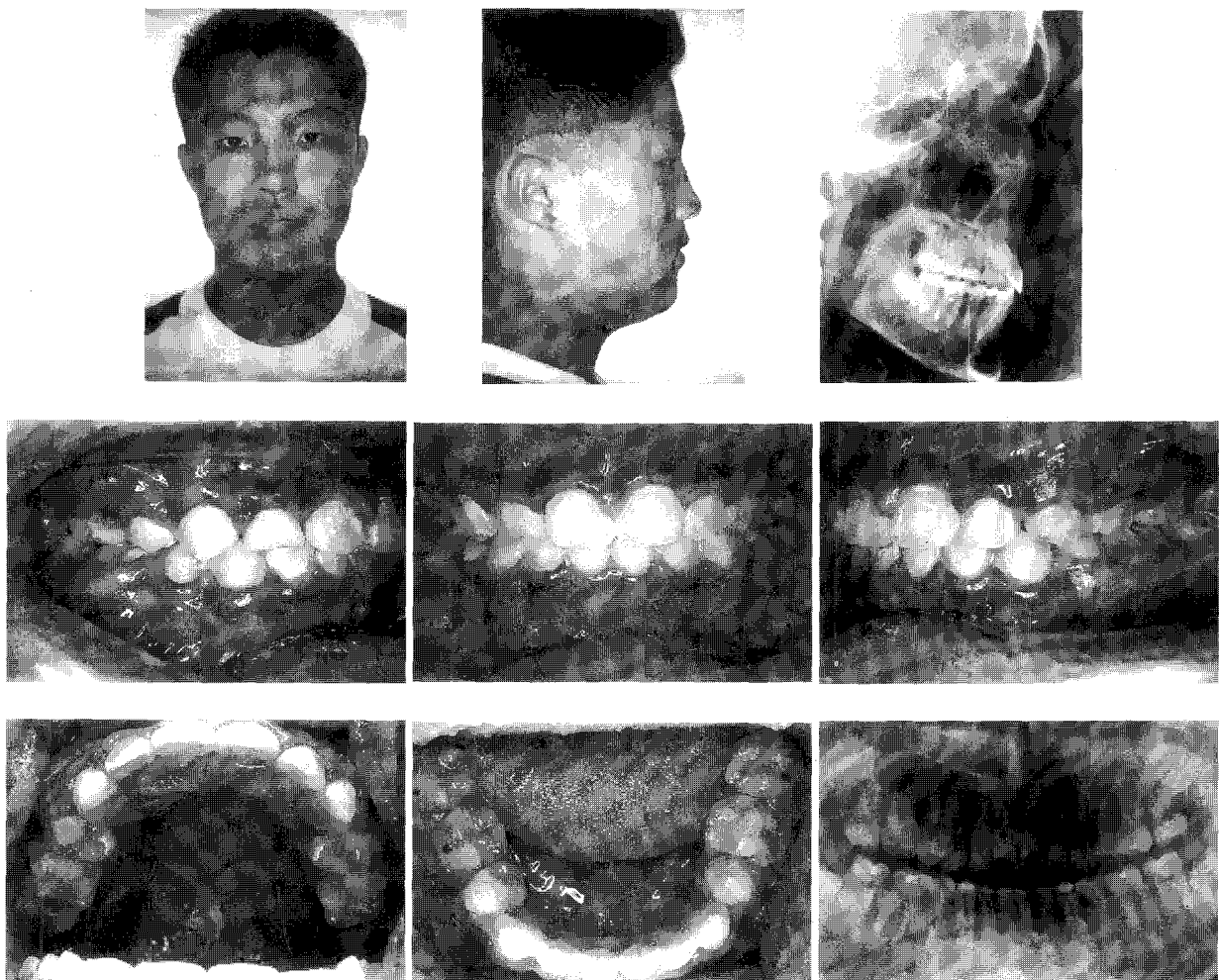


Fig. 3. Final facial photos, lateral cephalometric radiograph, intraoral photos, and panoramic radiograph.

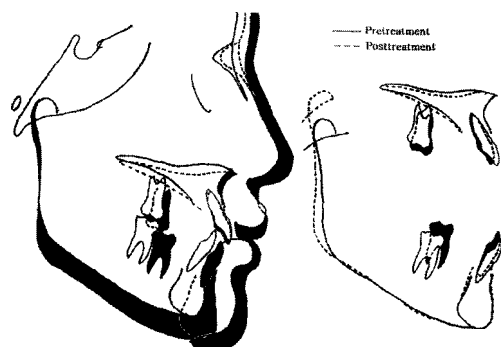


Fig. 4. Superimposition of pretreatment and posttreatment cephalograms: Enormous amount of mandibular growth as compared with maxillary growth was observed.

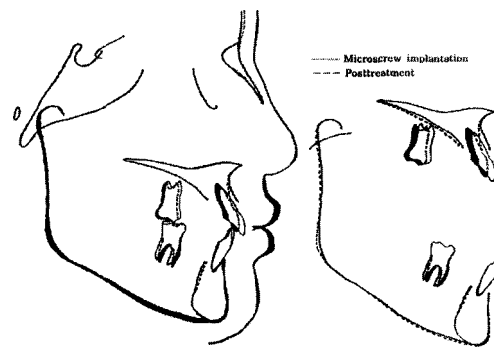


Fig. 5. Superimposition of titanium microscrew implantation and posttreatment cephalogram: Upper anterior teeth showed 4 mm bodily posterior and intrusive movement: Upper posterior teeth showed 1.5 mm posterior movement during six months orthodontic force application from skeletal cortical anchorage.

DISCUSSION

At times orthodontists encounter problem caused by lack of anchorage. Noteworthy advancements in endosseous implants may help solve such problems. Orthodontists have begun to take an interest in using implants for orthodontic anchorage. In early 1945, Gainsforth and Higley⁵⁾ examined the possibility of vitallium screws in orthodontic anchorage. The next reported use of implants as anchors for tooth movement was by Linkow.¹¹⁾ There were many studies to evaluate the possibility of endosseous implants and screws as orthodontic^{6,10,13,15,16,19)} and orthopedic anchorage¹⁷⁾ in animals.

After Branemark et al's²⁾ research, in which he observed successful osseointegration of implants with bone, clinical approaches were performed.^{12,14,21)} In 1994, Roberts et al¹²⁾ presented retromolar implant which was implanted in the mandibular retromolar area and used to close the extracted lower molar space.

Block and Hoffman¹⁾ introduced the on-plant which was implanted on midpalatal area subperiosteally. As mentioned earlier, endosseous implants have many limitations for orthodontic anchorage.

Creekmore and Eklund⁴⁾ reported a case that intrusion of upper anterior teeth by using vitallium

screw, which was implanted to the bone just below anterior nasal spine. Umemori et al²⁰⁾ reported open-bite cases treated with skeletal anchorage system using surgical miniplates. Recently, Kanomi⁸⁾ and Costa et al³⁾ presented the use of small titanium microscrews as orthodontic anchorage. In regard to the extensiveness of the procedure, a skeletal anchorage system using surgical miniplates is more extensive than microscrew implants. In regard to the amount of force which can be withstood, the skeletal anchorage system is superior. But, in a biological point of view, the amount of force to retract anterior teeth does not exceed 1 N. Concerning the amount of force applied on implants, many researchers observed that implants could withstand 1 N to 6 N of force.^{7,13,21)} There were no studies dealing with the amount of force on titanium microscrews except a study of Gray et al.⁶⁾ According to Gary et al's⁶⁾ study, a 1.6 mm vitallium screw could withstand 180 gm of horizontal loading. The author had applied many different force levels in many cases. Microscrew implants could withstand 200 gm of force (unpublished data). Skeletal cortical anchorage may be strong enough to remain stable in this range of force application. The author decided to use

150–200 gm of continuous force to retract anterior teeth. In this case, titanium microcrew implants remained firm and stable throughout treatment. A NiTi coil spring was selected for force application because it offered continuous light force.

The author directed the force to be passed through the center of resistance of the anterior teeth as much as possible. After six months of force application, the upper anterior teeth showed 4 mm bodily posterior and intrusive movement. The most outstanding result was the posterior movement of the upper posterior teeth, which were usually the anchor unit in conventional orthodontic treatment (Fig. 5). In other words, maxillary whole dentition was moved backward against small titanium microcrew implants. These results indicate that skeletal cortical anchorage using titanium microcrew implants can be an absolute anchorage system for orthodontic movement and can retract entire dentition as far as it persists. This is consistent with Southard et al's observation.¹⁸⁾

Because the vector of force passed over the center of resistance of the whole maxillary dentition, the occlusal plane was flattened. It may be helpful to reposition the mandible forward.

There was minor inflammation around titanium microcrew implants and the NiTi coil spring. Because the author used ligature wire to connect NiTi coil spring to titanium microcrew implants, ligated wire around microcrew neck must have acted as an irritant. Lindhe et al¹⁰⁾ also found the placement of plaque retentive ligatures around the implant neck resulting in inflammation. The author is planning to develop a new type of titanium microcrew implants that have a hook on the head of the microcrew for attaching the NiTi coil spring. In clinical work, the author tried to use polyethylene tubing to wrap the NiTi coil spring. It can be a means of reducing inflammation.

The studies dealing with the timing of force application after implantation can be divided into two groups. One group of studies stated that the clinician should delay the force application until osseointegration occurred. Roberts et al¹³⁾ concluded from an

experiment in the femurs of rabbits that immediate loading needed to be avoided. The other group of studies insisted on immediate force application.^{3,9)} As Gray et al's observation,⁶⁾ as far as using titanium microcrew implants as orthodontic anchorage, osseointegration might not be necessary. He found firm stable screws after force application that had connective tissue encapsulation. In my opinion, once soft tissue is healed it is possible to apply orthodontic force.

Skeletal cortical anchorage using titanium microcrew implants has just started to be used for clinical purposes. There are many clinical considerations we must clarify scientifically such as the timing of force application, the amount of force, method of force application and inflammation.

Despite some limitations, skeletal cortical anchorage using titanium microcrew implants may be a good option for reinforcing anchorage.

SUMMARY

The author treated a patient with skeletal cortical anchorage using titanium microcrew implants after patient failed to cooperate during 13 months of conventional mechanotherapy. During six months of orthodontic force application using titanium microcrew implants, the upper anterior teeth showed 4 mm bodily and intrusive movement. The most positive result was 1.5 mm posterior movement of upper posterior teeth. The titanium microcrew implants had remained firm and stable throughout treatment.

These results indicate that skeletal cortical anchorage may be used as anchorage for orthodontic movement.

REFERENCE

1. Block MS, Hoffman DR. A New Device for Absolute Anchorage for Orthodontics, *Am J Orthod Dentofac Orthop* 1995 : 107 : 251–258.
2. Branemark PI, Breine U, Hallen O, et al. Repair of Defects in the Mandible, *Scand J Plast Reconstr Surg* 1970 : 4 : 100–108.

3. Costa A, Raffini M, Melsen B. Microscrews as Orthodontic Anchorage, *Int J Adult Orthod Orthogn Surg* 1998 : 13 : 201-209.
4. Creekmore TD, Eklund MK. The Possibility of Skeletal Anchorage, *J Clin Orthod* 1983 : 17 : 266-269.
5. Gainsforth BL, Higley LB. A Study of Orthodontic Anchorage Possibilities in Basal Bone, *Am J Orthod Oral Surg* 1945 : 31 : 406-417.
6. Gray JB, Steen ME, King GJ, Clark AE. Studies on the Efficacy of Implants as Orthodontic Anchorage, *Am J Orthod* 1983 : 83 : 311-317.
7. Hurzeler MB, Quinones CR, Kohal RJ, et al, Changes in Peri-implant Tissues Subjected to Orthodontic Forces and Ligature Breakdown in Monkeys, *J Periodontol* 1998 : 69 : 396-404.
8. Kanomi R. Mini-implant for Orthodontic Anchorage, *J Clin Orthod* 1997 : 31 : 763-767.
9. Kohri M, Cooper EP, Ferracane JL, Waite DF. Comparative Study of Hydroxyapatite and Titanium Dental Implants in Dogs, *J Oral Maxillofac Surg* 1990 : 48 : 1265-1273.
10. Lindhe J, Berglundh T, Ericsson B, Liljenberg B, Marinello C. Experimental Breakdown of Peri-implant and Periodontal Tissues-A Study in the Dog, *Clin Oral Impl Res* 1992 : 3 : 9-16.
11. Linkow LI. The Endosseous Blade Implant and Its Use in Orthodontics, *Int J Orthod* 1969 : 18 : 149-154.
12. Roberts WE, Nelson CL, Goodacre CJ. Rigid Implant Anchorage to Close a Mandibular First Molar Extraction Site, *J Clin Orthod* 1994 : 28 : 693-704.
13. Roberts WE, Smith RK, Zilberman Y, Mozsary PG, Smith RS. Osseous Adaptation to Continuous Loading of Rigid Endosseous Implants, *Am J Orthod* 1984 : 86 : 95-111.
14. Shapiro PA, Kokich VG. Uses of Implants in Orthodontics, *Dent Clin North Am* 1988 : 32 : 539-550.
15. Sherman AJ. Bone Reaction to Orthodontic Forces on Vitreous Carbon Dental Implants, *Am J Orthod* 1978 : 74 : 79-87.
16. Smalley WM, Shapiro PA, Hohl TH, Kokich VG, Branemark PI. Osseointegrated Titanium Implants for Maxillofacial Protraction in Monkeys, *Am J Orthod Dentofac Orthop* 1988 : 94 : 285-295.
17. Smith JR. Bone Dynamics Associated with the Controlled Loading of Bioglass-coated Aluminum Endosteal Implants, *Am J Orthod* 1979 : 76 : 618-636.
18. Southard TE, Buckley MJ, Spivey JD, Krizan KE, Casko JS. Intrusion Anchorage Potential of Teeth Versus Rigid Endosseous Implants : A Clinical and Radiographic Evaluation, *Am J Orthod Dentofac Orthop* 1995 : 107 : 115-120.
19. Turley PK, Kean C, Schur J, et al, Orthodontic Force Application to Titanium Endosseous Implant Angle, *Orthod* 1988 : 58 : 151-162.
20. Umemori M, Sugawara J, Mitani H, Nagasaka H, Kawamura H. Skeletal Anchorage System for Open-bite Correction, *Am J Orthod Dentofac Orthop* 1999 : 115 : 166-174.
21. Wehrbein H, Merz BR, Hammerle CHF, Lang NP. Bone-to-Implant Contact of Orthodontic Implants in Humans Subjected to Horizontal Loading", *Clin Oral Impl Res* 1998 : 9 : 348-353.

국문초록

Titanium microscrew implant를 이용한
skeletal cortical anchorage

계명대학교 의과대학 치과학교실

박 효 상

고정원의 조절은 교정치료에 있어서 매우 중요한 요소로 이를 보강하기 위한 많은 노력이 있어왔다. 골융합성 임플란트의 경우 확실한 고정원으로서 가능성이 인정되고 있고, 또 임상에서 많이 시도되고 있다. 그러나 임플란트를 매식하기 위해서는 무치악이 존재해야 하거나 하악구치 후방부위에 식립해야 하는 등 장소의 제약이 있고, 값이 비싸며, 골융합을 위하여 기다리는 시간이 필요하다는 등의 단점으로 인하여 보편화되고 있지는 않다.

최근 몇몇 임상가에 의하여 수술용 titanium microscrew 나 miniscrew를 교정치료시의 고정원으로 사용하려는 시도가 있었는데, 이것은 골융합성 임플란트보다 수술이 간단하며, 가격이 저렴하고, 치조골 어느 부위이든지 식립할 수 있다는 장점이 있다.

저자는 titanium microscrew implant를 사용한 skeletal cortical anchorage를 이용하여 통상적인 교정치료 동안 협조도가 고갈된 환자를 치료하였다. 6 개월간의 titanium microscrew로 부터 가해진 교정력에 의하여 상악 전치부는 4 mm 후방 치체이동과 압하이동을 얻었다. 통상의 교정치료에서 고정원역할을 하는 상악 구치부도 1.5 mm 후방이동되었다. titanium microscrew는 치료기간 동안 움직임없이 잘 유지되었다.

비록 과학적으로 밝혀져야할 임상적인 문제가 있기는 하나, skeletal cortical anchorage는 확실한 고정원으로서의 역할을 할 수 있을 것으로 생각된다.

주요단어: Skeletal cortical anchorage, Titanium microscrew implants