

투고일 : 2020. 7. 10

심사일 : 2020. 9. 4

게재확정일 : 2020. 9. 18

3

Herpes zoster infection with meningitis after prodromal symptom presented as toothache

Department of Dentistry, Dongsan Hospital, Keimyung University School of Medicine

Ju-Yeon Cho

ABSTRACT

Herpes zoster infection with meningitis after prodromal symptom presented as toothache

Department of Dentistry, Dongsan Hospital, Keimyung University School of Medicine

Ju-Yeon Cho

Herpes zoster virus (HZV) infection is reactivation of Varicella Zoster virus that entered into the dorsal root ganglia during prior chicken pox infection, then remained in a latent form. HZV is characterized by its typical unilateral vesicles and rash along with a dermatome involvement. In its early stage, the only symptom may be prodromal odontalgia. Therefore, the difficulty in its diagnosis may lead to delayed HZV treatment as well as unnecessary dental procedures. A case of HZV infection of the trigeminal nerve branch is presented here, which was not properly diagnosed at the initial examination, but later confirmed as HZV infection with meningitis.

Key words : Herpes zoster, virus, trigeminal, meningitis

Corresponding Author

Ju-Yeon Cho,  <https://orcid.org/0000-0001-8338-9493>

Department of Dentistry, Dongsan Hospital, School of Medicine, Keimyung University,
1095 Dalgubeol-daero, Dalseo-gu, Daegu, 42601, Republic of Korea

Te l: +82-53-258-4681/ E-mail : cipher01@dsmc.or.kr

I. Introduction

Herpes zoster virus (HZV) infection is caused by Varicella zoster virus (VZV), a double stranded DNA virus of Herpesviridae family^{1,2)}. Herpes zoster infection along the trigeminal nerve is a reactivation of the VZV which remains in the trigeminal ganglion after primary and initial chickenpox infection, which occurs 18.5-22% of the total cases of maxillofacial infections¹⁾. This secondary outbreak of HZV happens after several decades of its latent period, when one's immunity against VZV decreases. The lifetime risk of VZV infection is estimated as 10%-20%, and the adjusted HZV incidence rate ratios in South Korea have been increased from 4.23 to 9.22 per 1000 person-years in the periods of 2006-2015^{1,3)}.

Immunosuppression, advanced age, cytotoxic drugs, radiation, malignancies, alcohol, physical and psychological trauma and dental manipulation are the risk factors of HZV infection^{4,5)}. Herpes zoster affects any sensory ganglion and its nerve, usually dermatomes of trunk, rather than those of cranial nerves. The active stage of this disease is characterized by maculopapular rash in one or two intimate dermatomes that usually affects unilateral side of the body or face. The rash proceeds into clusters of painful vesicles for 3-5 days, then eventually dry to form crust in 2 to 4 weeks. In immunocompromised cases, the rash may affect 3 or more dermatomes¹⁾.

With regards to the maxillofacial area, Herpes zoster occurs separately in dermatomes of the

ophthalmic nerve (V1), the maxillary nerve (V2), and the mandibular nerve (V3), although multiple occurrences among the three dermatomes have been reported in immunocompromised cases. If the virus involves trigeminal nerve branches, it is usually the ophthalmic branch (V1), while the V2 and V3 dermatomes are less commonly affected^{6,7)}.

In its prodromal stage, HZV infection can be manifested as toothache, usually 2-3 days before emergence of its prominent rash or vesicles⁶⁾. Furthermore, during the active stage of this disease, the absence of a rash (zoster sine herpete) may complicate the differential diagnosis of HZV with toothache or other orofacial pain^{6,7)}.

Thus, diagnosis of HZV infection is challenging when the subject does not have any typical rash or symptoms, as it may lead to improper treatment aiming at an unrelated disease or delayed treatment of herpes zoster itself, that causes unnecessary procedures or other complications like postherpetic neuralgia. Early diagnosis and prompt treatment with antiviral medication will minimize the patient's discomfort as well as postherpetic neuralgia (PHN)⁶⁾. This article presents a case of HZV infection that had presented toothache like symptom as its prodromal manifestation, which made it difficult to diagnose as well as treating the disease promptly that might have led to unnecessary medication and meningitis as one of its complications.

II. Case reports

A 50-year-old male presented to the Department of Dentistry for evaluation of a severe toothache radiating to the right side of his face. The patient was taking thyroid hormone medication for hypothyroidism, which was a result of radiation treatment for his pre-existing hyperthyroidism. A sharp and throbbing pain had occurred in right mandibular and maxillary molar area two days ago after the patient had been overworking for several days, and the patient stated that the pain must be related to his old restorations because at first he could pinpoint his toothache to the maxillary right molars until the throbbing pain started to radiate to his forehead, cheek and temporomandibular joint (TMJ). The patient also said his gums and face felt swollen.

On clinical examination, objective findings revealed old but fair restorations on his upper and lower right molars. Sensitivity to percussion and

mobility test were not definitely noted on any teeth, as well as biting a wood stick and contacting an ice stick. Probing depths were less than 3mm and there was also no soft tissue swelling or other soft tissue abnormalities in the vicinity of upper and lower right molars. Panoramic radiography showed no signs of periradicular and bony pathosis except suspicious haziness of right maxillary sinus (Fig. 1). The patient showed vague but not definite discomfort when touching and pressing his cheek and infraorbital area. However, there was not any trigger point or pain when pressing the facial muscles and moving TMJ. The patient also complained of a cold-like symptoms as stuffed nose and general malaise. Therefore, the patient was prescribed acetaminophen for analgesia and antibiotics under the assumption of right acute maxillary sinusitis.

Febrile and chilling sensations, nausea and a severe headache developed 3 days later, so the patient visited the emergency room and was hospitalized for further

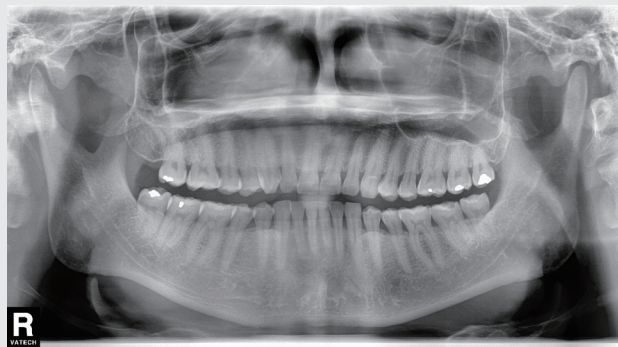

Fig. 1. Radiographic findings: no definite radiographic abnormalities except suspicious haziness of right maxillary sinus.

evaluation and treatment. On the 4th day after visiting the Department of Dentistry, which was the 1st day of hospitalization, a rash and blisters appeared on his right chin, lower lip, right lower part of the cheek and preauricular area. The rash did not extend beyond the midline. The patient was referred to the Department of Dermatology for evaluation, and HZV infection of V3 dermatome was diagnosed, based on the constellation of clinical features with Tzanck test (multinucleated giant cell with perinuclear halo) from the affected skin lesion. Then unilateral grouped blisters on erythematous base increased without intraoral lesion. The patient reported all involved areas were very tender, and complained of a severe headache and fluctuating fever.

The patient was managed with systemic antiviral treatment by intravenous acyclovir (10mg/kg, 3 times a day for 10days), systemic steroid therapy with dexamethasone (5mg 1 time a day at initial dose, then tapered), tricyclic antidepressant (amitriptyline

25mg for starting dose) for prevention of PHN, and analgesics as well as wet dressing and topical ointment on the lesion. Although the skin lesions got improved with crust, fever and headache persisted (Fig. 2). Therefore, cerebrospinal fluid (CSF) tapping and consecutive polymerase chain reaction (PCR) were performed to rule out the possibility of meningitis due to HZV. Meningitis and Varicella zoster virus infection were diagnosed as results of CSF analysis. There was complete resolution of toothache, facial crust and ulceration at 2 weeks after his admission, then the patient was discharged. However, a neuralgia of V3 dermatome was reported after resolution of the facial lesions, for which gabapentin was prescribed (300mg, 3 times a day). The patient was completely free of postherpetic neuralgia without facial scarring after 3 months and 2 weeks after his rash.

(*This is an exempt case report from IRB: one, retrospective and de-identified case report)

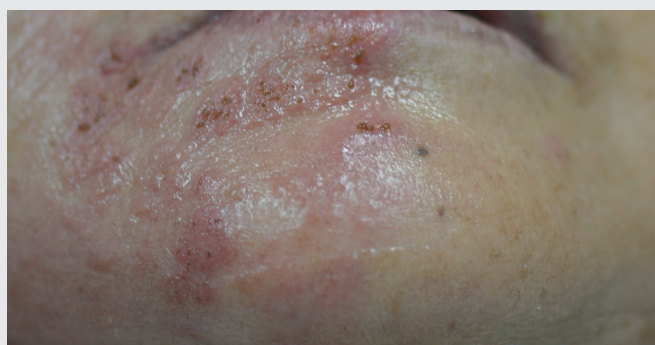


Fig. 2. Skin lesions of the herpes zoster infection (6 days after the onset of rash and blisters: clusters and blisters on the right side of the chin and lower lip)

III. Discussion

Varicella zoster virus is a cause of two common infection: shingles and chicken pox. Chicken pox is the primary infection which can occur in early childhood. After this initial infection, the virus remains latent until there is a reactivation, that may break out decades later. This subsequent reactivation of Varicella zoster virus is called Herpes Zoster infection⁸⁾. Herpes zoster infection is usually known as shingles that commonly presents a unilateral rash and vesicles⁹⁾. HZV is contagious and spread via direct contact and by inhalation of the airborne virus. The virus is then carried via the blood stream and lymphatic system, and spread to the epidermis from the capillary, in which viral replication attacks the basal cells. It remains dormant in the dorsal nerve root ganglia. A person with HZV remains contagious 2 days before a rash appears, until all lesions are crusted⁸⁾.

Herpes zoster may affect any sensory ganglia and its cutaneous nerve. Dermatomes of thoracic (T)-3 to lumbar (L)-2 are mostly affected (over 50%), but 13% of patients present involvement of the three branches of the trigeminal nerve^{2,10)}.

Herpes zoster infections have three diagnostic stages: prodromal stage, active or acute stage, and chronic stage⁸⁾. However, a few patients may not develop vesicles or a rash in the acute stage, but they do present pain related to the dermatome (Zoster sine herpette). This makes its diagnosis more difficult since the characteristic feature of Herpes zoster is vesicular eruptions upon rash¹⁰⁾.

The prodromal stage exhibits abnormal sensations of the affected area such as: burning, itching, tingling, prickly and even swollen sensation like the present case. They are usually occurring on the skin of the affected nerve distribution, called dermatome. It is believed that these sensory changes are a consequence of nerve degenerations due to viral infection. The prodromal stage precedes the acute stage by a few hours to several days, but in some cases it took 1-2 months^{7,11,12)}. The affected subject may express an odontalgia, which might be the only symptom in the prodromal stage^{13,14)}. Therefore, a dentist's role to rule out HZV infection in this stage should be emphasized.

The active or acute stage is easily detected by rash and vesicular eruptions accompanies with generalized condition as malaise, headache, nausea and fever. The rash proceeds to vesicles in a day, then progresses to pustules within a week. These pustules dry and form crusts which come off in two or three weeks, sometimes leaving scars. Intraoral lesions are usually presented after the appearance of rash. It is reported that when the rash is most active in acute stage, pain is minimal on the contrary although the pain returns during the crusting phase¹¹⁾.

The chronic stage is generally termed as post herpetic neuralgia (PHN). PHN is described as pain persisting after the healing of the active skin lesion, even after all the crusts are peeled off. PHN usually occurs in 10% of the case and lasts 1 to 3 months, however it persists even for years and decades. PHN is characterized as pain of constant, recurrent

shooting, and sharp radiating dysesthesia which is facilitated by light touching of the skin^{7,15}). Age is the one of the most important factors of predicting the occurrence of PHN. More than 40% of HZV patients among the age over 60 years, experience PHN. Treatment of PHN usually includes tricyclic antidepressants, gabapentin, topical lidocaine patches, sometimes capsaicin patches, botulinum toxin or percutaneous peripheral nerve field stimulation¹⁰).

The diagnosis of zoster virus infection is usually made clinically by the appearance of the skin rash. In confusing or unusual appearing cases, diagnosis may be made with blood test, showing positive antibodies against VZV Ig G, or PCR by identifying DNA in skin lesion although it is expensive and time-consuming. In patients with suspected meningitis or other complications due to HZV, the viral DNA may be detected in CSF or saliva²). Although the diagnosis of HZV is easy when there are prodromal symptoms with the appearance of rash, it will be a challenge to clinicians when the vesicular rash does not occur. Detailed and thorough dental examination with full medical history taking which includes the subject's past history of herpes attack can help ruling out other pathology like trigeminal neuralgia, maxillary sinusitis, irreversible pulpitis, acute periapical periodontitis and other odontogenic/nonodontogenic pain¹⁶). Furthermore, even though patients can point out a problematic tooth or make certain that their pain originates from odontogenic focus, that may not be true. The nature of the pain informed by the patient may be similar like that of tooth origin, therefore this situation may lead to un-

necessary dental treatment including nonsurgical/surgical root canal treatment or even extraction, which will fail to subside the patient's symptom and pain⁷). However, another problem with HZV infection of trigeminal nerve is that pulpal necrosis can be occurred by this virus¹⁷). The dental pulp has terminal nerve endings, and the reactivated virus may migrate along the nerve and reaches the pulp to infect and devitalize. Therefore, detailed and repeated regular pulp tests of the affected side are also necessary for detecting pulp condition and initiating root canal treatment. HZV infection often makes scars, which makes the diagnosis of HZV and its related pulp necrosis easier⁸).

Patients with zoster virus infection should be treated with acyclovir, famciclovir, or valacyclovir orally. If zoster is severe, intravenous acyclovir can be administered. Antiviral medications should be given as soon as possible, at least 72 hours prior its onset of skin lesion for the best outcome^{2,6}). Antiviral drug therapy includes acyclovir, a classic drug of choice that usually be given 800mg four times a day for 10 days as a standard regimen and up to five times a day for more promising results. Famciclovir can be prescribed as 500mg every 8 hours for 7 days while valacyclovir, a drug of choice for immunodeficient patients, 1g three times a day for 7 days.

The treatment of PHN is composed of topical use of capsaicin cream, topical anesthetics and low dose of amitriptyline, which is a kind of tricyclic antidepressant drug. Since the pain originates from injury of the central nervous system, it is not likely to respond to usual analgesics, nor a single treatment is

CASE REPORT

effective.

Ocular involvement is the most common complication of HZV infection in trigeminal nerve (50%), therefore it should be remembered that cutaneous zoster lesions on the tip of the nose (Hutchinson's sign) is pathognomonic of V1 (ophthalmic) branch involvement of trigeminal nerve that can affect the eyes and visions⁸⁾. Sometimes, unusual complications of HZV infections of trigeminal nerve may occur. For example, Ramsay Hunt syndrome rarely occurs in 1% of cases, affecting the otic and cranial nerve alterations; ear lesions and facial nerve paresis⁴⁾. Any part of central nervous system can be affected, as brain, liver, joints and heart. These complications can be found in those who are immunosuppressant or in systemic disease. In patients with HIV infection, repeated herpes zoster infections may occur, or zoster may be the first manifestation^{1,10)}. Reported dental complications are devitalization of tooth, tooth exfoliation, internal root resorption and osteonecrosis^{12,18-20)}. The risk of stroke is increased in adults with zoster infection, and by 4.5-fold when HZV infection occurs in the ophthalmic division of

the trigeminal nerve (V1)¹⁰⁾.

In conclusion, the present case of severe HZV infection was difficult to diagnose immediately since the patient had not presented any rash or skin lesions but complained about severe toothache and swollen sensation of the right maxilla during his visit of Department of Dentistry. The differential diagnosis of atypical tooth pain should include TMJ disorders, systemic disorders, trigeminal neuralgia, salivary gland disorders, and referred pain as well as HZV infection⁴⁾. Later, the present case was diagnosed as severe HZV infection of V3 accompanied with meningitis, which made the patient to be hospitalized for over a week along with lingering PHN for 3 months. In this case and literature reviews, the dentists' role should be emphasized in early diagnosis of HZV infection of its prodromal stage, or HZV infection without its typical skin lesion, especially when it comes to a severe toothache of the affected area. Herpes zoster infection should be included as a possible factor when there is atypical presentation of odontogenic pain.

참 고 문 헌

1. Paquin R, Susin LF, Welch G, et al. Herpes Zoster Involving the Second Division of the Trigeminal Nerve: Case Report and Literature Review. *J Endod* 2017;43(9):1569–1573.
2. Kennedy PGE, Gershon AA. Clinical Features of Varicella-Zoster Virus Infection. *Viruses* 2018;10(11).
3. Choi JK, Park SH, Park S, et al. The changing epidemiology of herpes zoster over a decade in South Korea, 2006–2015. *Vaccine* 2019;37(36):5153–5160.
4. Brooks JK, Rostami AM, McCorkle DC, Benesh SI. Trigeminal herpes zoster and Ramsay Hunt syndrome in an elderly adult: Presentation with prodromal toothache. *Gerodontology* 2018;35(3):276–278.
5. Nair P, Gharote H, Singh P, Jain-Choudhary P. Herpes zoster on the face in the elderly. *BMJ Case Rep* 2014;2014:bcr2013200101.
6. Tsai MC, Chiu CY, Tsai SH. Male with Toothache. *J Emerg Med* 2018;54(1):e5–e6.
7. Fristad I, Bardsen A, Knudsen GC, Molven O. Prodromal herpes zoster—a diagnostic challenge in endodontics. *Int Endod J* 2002;35(12):1012–1016.
8. Tidwell E, Hutson B, Burkhart N, et al. Herpes zoster of the trigeminal nerve third branch: a case report and review of the literature. *Int Endod J* 1999;32(1):61–66.
9. Shah S, Singaraju S, Einstein A, Sharma A. Herpes zoster: A clinicocytopathological insight. *J Oral Maxillofac Pathol* 2016;20(3):547.
10. Nagel MA, Gilden D. Complications of varicella zoster virus reactivation. *Curr Treat Options Neurol* 2013;15(4):439–453.
11. Strommen GL, Pucino F, Tight RR, Beck CL. Human infection with herpes zoster: etiology, pathophysiology, diagnosis, clinical course, and treatment. *Pharmacotherapy* 1988;8(1):52–68.
12. Mintz SM, Anavi Y. Maxillary osteomyelitis and spontaneous tooth exfoliation after herpes zoster. *Oral Surg Oral Med Oral Pathol* 1992;73(6):664–666.
13. Barrett AP, Katelaris CH, Morris JG, Schifter M. Zoster sine herpete of the trigeminal nerve. *Oral Surg Oral Med Oral Pathol* 1993;75(2):173–175.
14. Law AS, Lilly JP. Trigeminal neuralgia mimicking odontogenic pain. A report of two cases. *Oral Surg Oral Med Oral Pathol Oral Radiol Endod* 1995;80(1):96–100.
15. Rowbotham MC, Fields HL. Topical lidocaine reduces pain in post-herpetic neuralgia. *Pain* 1989;38(3):297–301.
16. Patil S, Srinivas K, Reddy BS, Gupta M. Prodromal herpes zoster mimicking odontalgia—a diagnostic challenge. *Ethiop J Health Sci* 2013;23(1):73–77.
17. Chen V, Chen Y, Li H, et al. Herpesviruses in abscesses and cellulitis of endodontic origin. *J Endod* 2009;35(2):182–188.
18. Millar EP, Troulis MJ. Herpes zoster of the trigeminal nerve: the dentist's role in diagnosis and management. *J Can Dent Assoc* 1994;60(5):450–453.
19. Sigurdsson A, Jacoway JR. Herpes zoster infection presenting as an acute pulpitis. *Oral Surg Oral Med Oral Pathol Oral Radiol Endod* 1995;80(1):92–95.
20. Kim N-K, Kim BC, Nam J-w, Kim HJ. Alveolar bone necrosis and spontaneous tooth exfoliation associated with trigeminal herpes zoster: a report of three cases. *J Korean Assoc Oral Maxillofac Surg* 2012;38(3):177–183.