



Evaluation of transmitted glow point at *a priori* chosen depth (1 cm below vocal cords) for lightwand intubation: a prospective observational study

Eunyoung Cho^{1,*}, Hyun-Chang Kim^{2,3,*} ,
Jung-Man Lee⁴, Ji-Hoon Park¹, Najeong Ha¹,
Ji Hee Hong¹ and Jiwon Lee^{1,2,3,†} 

Abstract

Objective: When performing lightwand intubation, an improper transmitted glow position before tube advancement can cause intubation failure or laryngeal injury. This study was performed to explore the transmitted glow point corresponding to *a priori* chosen depth for lightwand intubation.

Methods: Before lightwand intubation, we marked the transmitted glow point from a bronchoscope on the neck when it reached 1 cm below the vocal cords. Lightwand intubation was then performed using this marking point. The distances from the mark to the upper border of the thyroid cartilage, upper border of the cricoid cartilage, and suprasternal notch were measured.

Results: In total, 107 patients were enrolled. The success rate of lightwand intubation using the mark was 93.5% (95% confidence interval, 88.7%–99.2%) at the first attempt. The marking point was placed 12.0 mm (95% confidence interval, 10.6–13.4 mm) below the upper border of the cricoid cartilage.

¹Department of Anesthesiology and Pain Medicine, Keimyung University Dongsan Hospital, Keimyung University School of Medicine, Daegu, Korea

²Department of Anesthesiology and Pain Medicine, Yonsei University College of Medicine, Gangnam Severance Hospital, Seoul, Korea

³Anesthesia and Pain Research Institute, Yonsei University College of Medicine, Seoul, Korea

⁴Department of Anesthesiology and Pain Medicine, SMG-SNU Boramae Medical Center, Seoul National University College of Medicine, Seoul, Korea

*These authors contributed equally to this work and are considered co-first authors.

[†]Jiwon Lee moved to this institution after completion of the study.

Corresponding author:

Jiwon Lee, Department of Anesthesiology and Pain Medicine, Yonsei University College of Medicine, Gangnam Severance Hospital, 211 Eonjuro, Gangnam-gu, Seoul 06273, Korea.

Emails: belief705@gmail.com, belief705@yuhs.ac



Conclusion: Anaesthesiologists should be aware of the appropriate point of the transmitted glow on the patient's neck when performing lightwand intubation. We suggest that this point is approximately 1 cm below the upper border of the cricoid cartilage.

Trial registration: ClinicalTrials.gov NCT03480035

Keywords

Intubation, cricoid cartilage, lightwand, general anaesthesia, bronchoscope, transmitted glow

Date received: 14 June 2020; accepted: 27 October 2020

Introduction

Tracheal intubation is a standard technique for anaesthesiologists. However, it is also the most important procedure. In most cases, intubation is performed under direct laryngoscopy. However, when a laryngoscope cannot be used for various reasons such as limited mouth opening, weak teeth, cervical spine instability, or facial trauma, many alternative devices can be used.^{1,2}

There has recently been a move toward non-blind intubation techniques emphasising visualisation of the laryngeal entrance. This shift has been prompted by the development of novel imaging techniques in difficult airway management.³ Videolaryngoscopes have great advantages in direct visualisation of the area around the laryngeal opening, which can lead to successful tracheal intubation in patients with both difficult and normal airways. However, the use of videolaryngoscopes may be restricted in patients with limited mouth opening, cervical spine instability, or severely weak teeth. Tracheal intubation using a lightwand is useful in patients with limited mouth opening, neck stiffness, or weakened teeth⁴ despite this technique being a blind intubation technique. Neck extension, lightwand modification, and the jaw-thrust manoeuvre are convenient methods for intubation using a lightwand.⁵⁻⁸ During tracheal intubation

with this technique, clinicians advance a tracheal tube onto the lightwand when they judge that the transmitted light is located at the optimal position. We considered that an excessive tube depth combined with use of the lightwand can lead to tracheal injury during intubation. Additionally, we considered that a too-shallow tube depth can lead to intubation failure or laryngeal damage such as arytenoid cartilage subluxation or vocal cord injury according to our clinical experiences and a literature review.⁹⁻¹³ The purpose of this study was to explore the transmitted glow point corresponding to *a priori* chosen depth (1 cm below the vocal cords) for lightwand intubation.

Materials and methods

This prospective observational study was approved by the institutional review board of Dongsan Medical Center, Daegu, Korea (2018-01-009-004). The study protocol was registered at clinicaltrials.gov (NCT 03480035). Patients were enrolled from March 2018 to August 2018 after providing written informed consent.

Adult patients (≥ 18 years old) who were scheduled for elective surgery and required tracheal intubation for general anaesthesia were screened for eligibility for this study. Patients were enrolled in this study if they exhibited weak teeth, cervical spine

instability, neck stiffness, or mouth opening of <3 cm in the preoperative interviews. The exclusion criteria were moderate cardiopulmonary disease, a history of neck surgery, a history of radiotherapy on the neck, and withdrawal of informed consent.

First, we chose the optimal position of the lightwand tip during lightwand intubation. In our literature review, some reports indicated that use of a stylet could cause tracheal injury.^{9,11,13–17} We considered that such tracheal injury due to use of a stylet may result from over-insertion of the stylet into the tracheal tube before intubation, rapid and powerful advancement of the combined tracheal tube and stylet into the trachea, or unnecessary deep insertion of the combined tracheal tube and stylet into the trachea. The lightwand is a type of stylet often referred to as a lighted stylet. Therefore, the mechanisms of possible tracheal injury by a stylet seem to apply to lightwand intubation. Tracheal intubation may be successful while withdrawing the stylet when the combination of the tracheal tube and stylet is inserted into the trachea approximately 1 cm below the vocal cords. Therefore, in the present trial, our *a priori* chosen depth for the lightwand tip was 1 cm below the vocal cords.

The patients were admitted to the operating theatre without premedication and were monitored using electrocardiography, pulse oximetry, and noninvasive blood pressure measurements. We inserted a lightwand into a tracheal tube (inner diameter of 7.0 mm for women and 7.5 mm for men) with the bulb of the lightwand positioned at the midpoint of the bevel of the tube before induction of anaesthesia. Anaesthesia was induced with 40 mg of lidocaine, 2 mg·kg⁻¹ of propofol, 0.1 µg·kg⁻¹ of sufentanil, and 0.8 mg·kg⁻¹ of rocuronium. After manual ventilation for several minutes, an experienced anaesthesiologist (>50 bronchoscopic intubations) performed an examination using a fiberoptic bronchoscope (FOB)

with an outer diameter of 4.1 mm (Olympus LF-GP; Olympus Optical Co., Tokyo, Japan). When the tip of the FOB reached the vocal cords, an assistant attached silk tape to the instrument at the level of the upper incisors. The FOB was then advanced 1 cm, and the supervisor marked the brightest point of transmitted light on the anterior neck while the practitioner held the FOB 1 cm below the vocal cords. The patient's posture was then maintained with the jaw lifted by the assistant and without neck extension. After withdrawal of the FOB, tracheal intubation with the lightwand (Surch-LiteTM; Bovie Medical Corp., Clearwater, FL, USA) was performed using the marking point as a guide (Figure 1) by a resident who had been trained for 2 or 3 years and had performed >50 lightwand intubation procedures. The practitioner lifted the patient's

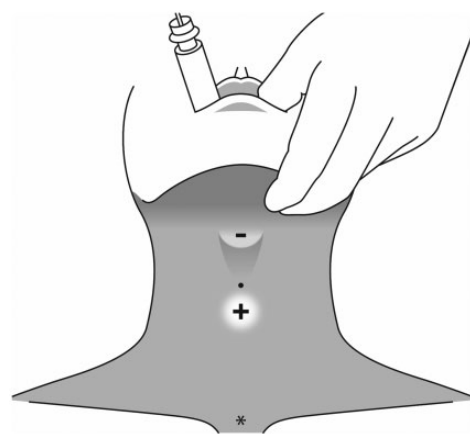


Figure 1. Tracheal intubation with a lightwand using a pre-marking point determined by a fiberoptic bronchoscope. Bar (–): upper border of thyroid cartilage. Spot (:): upper border of cricoid cartilage. Cross (+): pre-marking point; the position where the light from the fiberoptic bronchoscope transmitted through the anterior neck shone most brightly when the tip of the scope was located 1 cm below the vocal cords during fiberoptic bronchoscopic examination. Asterisk (*): supra-sternal notch.

mandible while placing the thumb of the left hand against the mandibular molars and pressing the index finger against the outside of the left mandible. During this lifting of the patient's mandible, the practitioner gripped the patient's left mandible while keeping the left hand as lateral as possible to avoid any obstacles in handling the combined lightwand and tracheal tube by the right hand. Next, the practitioner inserted the combined lightwand and tracheal tube into the oropharynx from the right side and brought it to the midline, following the mid-sagittal plane that transected the tongue by rotating the right hand. The practitioner gently advanced the tip of the combined lightwand and tracheal tube under the tongue with anterior traction. The practitioner then attempted to advance the tube only by the right hand with the lightwand held by the left hand if a bright glow was adequately transmitted at the level of the marked point. The practitioner did not advance the instrument further if a feeling of resistance was encountered while advancing the tube. The combined lightwand and tracheal tube was then scooped to reposition the distal tip into the laryngeal inlet.¹⁸ The modification angle of the lightwand was 90 degrees, and its bending point (by the supervisor) was 6.5 to 7.0 cm above the distal end of the endotracheal tube (Figure 2).⁶ After completion of the tracheal intubation, the distance from the mark to the upper border of the thyroid cartilage, the distance from the mark to the upper border of the cricoid cartilage, and the distance from the mark to the suprasternal notch were recorded (Figure 1). We used a straight paper scale to measure the distances from the mark to these anatomical landmarks to minimise the effect of the superficial curvatures of the human body. All procedures were completed with the patient in the supine position without head support by a pillow. If the first attempt by a resident failed, the supervisor

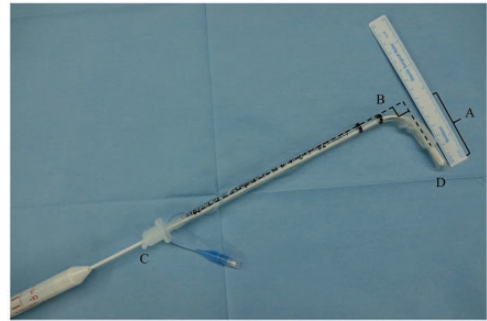


Figure 2. Set-up of the combined lightwand and tracheal tube. We combined the lightwand and tracheal tube as follows. (A) We bent the union at 6.5 to 7.0 cm from the tip of the tracheal tube. (B) The bending angle was about 90 degrees. (C) The plastic material of the lightwand (tube-stop) was impinged into the 15-mm tube connector to hold it together. (D) The bulb of the lightwand was placed at the midpoint of the bevel of the tracheal tube.

performed the lightwand intubation and the case was recorded as a failure.

The primary outcome was the distance from the mark on the neck (assumed to be 1 cm below the vocal cords) to the upper border of the cricoid cartilage, the distance from the mark to the upper border of the thyroid cartilage, and the distance from the mark to the suprasternal notch. The secondary outcome was the success rate of lightwand intubation at the first attempt. Additionally, the total time for lightwand intubation (from insertion of the tube combined with the lightwand into the oral cavity to confirmation of successful tracheal intubation as a capnographic waveform) was recorded.

We assumed that the variation in the distances between these anatomical indicators would be small and have a normal distribution. Additionally, we considered that some sex-related differences in the distances would be encountered, although our primary aim was not to compare the predicted differences between men and women but to present the measured distances.

Therefore, we set the target sample size at 50 patients of each sex and calculated a total sample size of 110 patients (50 of each sex with a dropout rate of 10%). The results are presented as the 95% confidence interval (CI) for each sex and for all participants. The Shapiro–Wilk test was used to confirm a normal distribution of the patients’ characteristics, including patient age, height, weight, body mass index, neck circumference, and the measured distances from the marking point to anatomical landmarks. We used an independent t-test to evaluate whether the measured distances differed between men and women.

Results

All patients (55 men, 52 women) were enrolled and completed the trial. The patients’ characteristics are shown in Table 1. The mean distance from the mark on the neck to the upper border of the thyroid cartilage was -33.1 ± 10.5 mm (95% CI, -35.1 to 31.0 mm) in all patients, -38 ± 9 mm (95% CI, -40 to 35 mm) in men, and -28 ± 10 mm (95% CI, -31 to -26 mm) in women. The distance from the mark to the upper border of the cricoid cartilage was -12.0 ± 7.1 mm (95% CI, -13.4 to -10.6 mm) in all patients, -13 ± 6 mm (95% CI, -14 to -11 mm) in men, and -11 ± 8 mm (95% CI, -14 to -9 mm) in

women. In addition, the distance from the mark to the suprasternal notch was 44.9 ± 9.6 mm (95% CI, 43.1 – 46.7 mm) in all patients, 45 ± 8 mm (95% CI, 43 – 47 mm) in men, and 45 ± 11 mm (95% CI, 42 – 48 mm) in women (Table 2). The initial success rate for tracheal intubation using the mark at the first attempt was 93.5% (95% CI, 88.7%–99.2%). The mean time from lightwand-guided tracheal tube insertion into the oral cavity to successful intubation was 19.0 ± 14.3 s in initial success cases. For the seven patients in whom failed intubation occurred at the first attempt, the supervisor performed lightwand intubation once after the first attempt. No adverse events, including desaturation, occurred during the trial in all patients.

Discussion

This study has shown that lightwand intubation can be successfully performed using the pre-marking point as guidance for the transmitted glow on the neck. When we chose 1 cm below the vocal cords as the position of the lightwand tip, the success rate was 93.5% at the first attempt in our trial. The pre-marking point on the patient’s neck was located slightly more than 1 cm below the upper border of the cricoid cartilage when the *priori* determined depth of the lightwand tip was 1 cm below the vocal cords. To our knowledge, no previous study has focused on the optimal depth for the lightwand tip. However, a previous review article described the process of lightwand intubation in detail.¹⁸ The authors stated that the maximal light intensity was present at the level of the hyoid and then distally toward the suprasternal notch.¹⁸ Technically, the brightest glow is visible within a range in clinical practice. However, we considered that as the lightwand advances more deeply, the risk of tracheal injury increases. Although this was not proven in our study, some

Table 1. Patient characteristics.

	Male (n = 55)	Female (n = 52)
Age, years	53 ± 14	60 ± 14
Height, cm	169 ± 6	155 ± 7
Weight, kg	71 ± 11	57 ± 8
BMI, kg·m ⁻¹	25 ± 3	24 ± 3
Neck circumference (cm)	41 ± 3	36 ± 3

Values are expressed as mean ± standard deviation.
BMI, body mass index.

Table 2. Distances from pre-marking point to anatomical landmarks.

	Male (n = 55)	Female (n = 52)	P-value*	All (n = 107)
Distances from pre-marking point, mm				
to thyroid cartilage upper border	-38 ± 9 (-40 to -35)	-28 ± 10 (-31 to -26)	<0.01	-33.1 ± 10.5 (-40.2 to -35.2)
to cricoid cartilage upper border	-13 ± 6 (-14 to -11)	-11 ± 8 (-14 to -9)	0.31	-12.0 ± 7.1 (-13.4 to -10.6)
to suprasternal notch	45 ± 8 (43-47)	45 ± 11 (42-48)	1.00	44.9 ± 9.6 (43.1-46.7)

Values are expressed as mean ± standard deviation (95% confidence interval).

*Independent t-test was used to compare the distances between the two sexes.

previous articles have described tracheal injury by a stylet.^{9,11,13-17} Therefore, we evaluated the efficacy of the lightwand tip located 1 cm below the vocal cords for lightwand intubation and assessed the corresponding point for the position of the lightwand tip on the patient's neck.

The literature indicates that a too-shallow depth of the combined lightwand and tracheal tube can cause perilaryngeal injury (such as subluxation of the arytenoid cartilage) or failed intubation.^{10,12} To avoid such risks, we determined that the depth of the lightwand tip should be 1 cm below the vocal cords. We assumed that this depth would not be too shallow if the success rate at the first attempt was not lower than that of previous studies involving a lightwand. The success rate at the first attempt of lightwand intubation under guidance by the mark was 93.5% in our study, which is similar to that of some previous studies on lightwand intubation^{8,19-22} and superior to that of other studies.²³⁻²⁵ This suggests that the *priori* chosen depth (1 cm below the vocal cords) is not too shallow for lightwand intubation.

After the FOB examination in the present study, the lightwand failed to reach the marking point in five patients (four men and one woman). In these cases, the

combined tracheal tube and lightwand was inserted only to the point at which resistance was felt; the tracheal tube was then pushed gently into the trachea. Lightwand intubation was successfully performed in all five of these patients. The two-curve theory in the human airway was introduced in a recent report.²⁶ Various relationships may exist between the first curve and the second curve of the airway among individual people. The inflection point between the two curves may be located more anteriorly in some people. The combined tracheal tube and lightwand cannot be easily advanced in such patients because the union can contact the posterior wall of the trachea before it reaches 1 cm below the vocal cords. We identified no specific findings that might be associated with the above phenomenon. For the five above-mentioned patients, the distance from the cricoid cartilage to the marking point was >20 mm or <5 mm; i.e., these measurements were outside the 95% CI. The two-curve theory and our data suggest that if resistance is felt during advancement of the combined tube and lightwand while the transmitted light is sufficiently bright on the patient's neck, intubation can gently proceed without advancing the combined tube and lightwand further.

The sizes of the laryngeal cartilages also differ among individuals. Among the laryngeal cartilages, the thyroid cartilage seems to exhibit the greatest differences in size among individuals, sexes, and races.^{27,28} In the present study, the distance from the mark to the upper border of the thyroid cartilage was significantly different between men and women. The reason for this is considered to be the differences in the sizes of the thyroid bones. Therefore, the thyroid cartilage is not suitable as an anatomical landmark for lightwand intubation despite the thyroid cartilage being the most easily detected cartilage because of its protrusion. Additionally, the distance from the brightest position of the transmitted light to the suprasternal notch seems to be too long for intuitive clinical use, although the distance from the mark to the suprasternal notch was not different between men and women in our study. A previous study showed that the distance from the point at 15 mm below the vocal cord to the suprasternal notch, which was termed VSD-15 in that study, was not correlated with sex in 427 patients (213 women, 214 men).²⁹ Therefore, our results seem to correspond to those of the previous study in terms of the constant distance from the vocal cords to the suprasternal notch regardless of sex. In addition, confirming the suprasternal notch by palpation might differ among clinicians because palpation of the suprasternal notch can be obscured on the surface of the body but not on radiologic images. In our study, only one investigator palpated the suprasternal notch and measured the distances. The mean distance from the mark to the suprasternal notch was about 4.5 cm among all participants as measured by one investigator in our study, and the corresponding distance was about 6.5 cm by analysis with computed tomography images for all patients of the previous study.²⁹ However, a range of 4.5 to 6.5 cm might not be appropriate for

intuitive use. We believe that a range of 1.0 to 1.5 cm is not difficult for clinicians to approximate at a glance. Therefore, we also believe that this notch is not an adequate landmark. In view of the above facts, the cricoid cartilage seems to be the best choice among all laryngeal structures as the landmark to determine the depth of the lightwand in clinical practice. However, our study was performed with a small sample size. Therefore, the distance from the mark to the upper margin of the cricoid cartilage could become more constant with a larger sample size. Additionally, we used a straight paper scale to measure the distances from the mark to anatomical landmarks. This might have affected the accuracy of the distances, although we used it to minimise the effect of superficial curvatures of the human body. Therefore, a study with a larger sample size is needed to evaluate the accuracy of our findings.

This study had several limitations. First, we defined the *priori* chosen depth for the lightwand tip as 1 cm below the vocal cords according to our experience and a literature review. No previous study has identified the optimal depth for the lightwand tip. We determined the *priori* chosen depth in our study based on previous studies on the use of a stylet, studies on the use of a fiberoptic bronchoscope, or our clinical experience. The transmitted glow position corresponding to 3 cm below the vocal cords might provide more confidence for successful entry of the combined lightwand and tracheal tube into the trachea than a point 1 cm below the vocal cords. Therefore, a randomised trial involving two or three lightwand positions is necessary to identify the optimal position of the lightwand tip. Second, we did not evaluate complications associated with lightwand intubation, such as the severity of sore throat after surgery. Many previous studies of tracheal intubation have evaluated sore

throat. Some studies on lightwand intubation, in which the optimal position of the transmitted light was not defined, revealed that the incidence of sore throat ranged from 17% to 23%.^{24,30,31} In one of these studies, the incidence of sore throat was higher in lightwand intubation than tracheal intubation under direct laryngoscopy.³⁰ If our chosen depth of the lightwand tip (1 cm below the vocal cords) was close to the optimal location, sore throat after surgery might have been less severe than that in previous studies. However, we did not evaluate this complication in the present study. Third, the sample size was somewhat small. Because this was an observational study and no previous studies have focused on the same issue, we decided that a sample size of 50 men and 50 women (considering the possible difference between sex and the sample size of 50) could provide a normal distribution of our data on the measured anatomical distances. However, these anatomical distances exhibit not only sex-related differences but also individual and racial differences. Our study only involved the Korean population. Therefore, we cannot conclude that the 95% CIs obtained in our study are applicable in all patients worldwide.

In conclusion, anaesthesiologists should be aware of the most appropriate point of the transmitted glow on the patient's neck for safe and successful lightwand intubation. We suggest that 1 cm below the vocal cords is an effective position for the lightwand tip and that a point slightly more than 1 cm below the upper border of the cricoid cartilage should be the corresponding point on the neck.

Availability of data and materials

The datasets used and/or analysed during the current study are available from the corresponding author on reasonable request.


Declaration of conflicting interest


The authors declare that there is no conflict of interest.

Funding

This work was supported by the Keimyung University Research Grant of 2018.

ORCID iDs

Hyun-Chang Kim  <https://orcid.org/0000-0001-7783-7595>

Jiwon Lee  <https://orcid.org/0000-0002-6650-0396>

References

1. Frerk C, Mitchell VS, McNarry AF, et al. Difficult Airway Society 2015 guidelines for management of unanticipated difficult intubation in adults. *Br J Anaesth* 2015; 115: 827–848.
2. Xue FS, Yang QY, Liao X, et al. Lightwand guided intubation in paediatric patients with a known difficult airway: a report of four cases. *Anaesthesia* 2008; 63: 520–525.
3. Özyilkan NB. New trends in intubation for the difficult airway management. *Anestezi Dergisi* 2016; 24: 63–66.
4. Inoue Y, Koga K and Shigematsu A. A comparison of two tracheal intubation techniques with Trachlight and Fastrach in patients with cervical spine disorders. *Anesth Analg* 2002; 94: 667–671; table of contents.
5. Goneppanavar U, Nair A and Kini G. Jaw lift causes less laryngeal interference during lightwand-guided intubation than combined jaw and tongue traction applied by single operator. *Indian J Anaesth* 2011; 55: 154–159.
6. Chen TH, Tsai SK, Lin CJ, et al. Does the suggested lightwand bent length fit every patient? The relation between bent length and patient's thyroid prominence-to-mandibular angle distance. *Anesthesiology* 2003; 98: 1070–1076.
7. Jeon YT, Lim YJ, Na HS, et al. A double bending lightwand can provide more successful endotracheal intubation in patients with a short thyromental distance: a

- prospective randomised study. *Eur J Anaesthesiol* 2011; 28: 651–654.
8. Chen J, Luo W, Wang E, et al. Optimal bent length of lightwand for intubation in adults: a randomized, prospective, comparative study. *J Int Med Res* 2012; 40: 1519–1531.
 9. Su K, Gao X, Xue FS, et al. Difficult tracheal tube passage and subglottic airway injury during intubation with the GlideScope(R) videolaryngoscope: a randomised, controlled comparison of three tracheal tubes. *Anaesthesia* 2017; 72: 504–511.
 10. Wu L, Shen L, Zhang Y, et al. Association between the use of a stylet in endotracheal intubation and postoperative arytenoid dislocation: a case-control study. *BMC Anesthesiol* 2018; 18: 59.
 11. Komasa N, Nishihara I and Minami T. Effects of stylet use during tracheal intubation on postoperative pharyngeal pain in anesthetized patients: a prospective randomized controlled trial. *J Clin Anesth* 2017; 38: 68–70.
 12. Asai T and Shingu K. Difficulty in advancing a tracheal tube over a fiberoptic bronchoscope: incidence, causes and solutions. *Br J Anaesth* 2004; 92: 870–881.
 13. Yoon HK, Lee HC, Oh H, et al. Postoperative sore throat and subglottic injury after McGrath(R) MAC videolaryngoscopic intubation with versus without a stylet in patients with a high Mallampati score: a randomized controlled trial. *BMC Anesthesiol* 2019; 19: 137.
 14. Massard G, Rouge C, Dabbagh A, et al. Tracheobronchial lacerations after intubation and tracheostomy. *Ann Thorac Surg* 1996; 61: 1483–1487.
 15. Borasio P, Ardisson F and Chiampo G. Post-intubation tracheal rupture. A report on ten cases. *Eur J Cardiothorac Surg* 1997; 12: 98–100.
 16. Tezel C, Okur E and Baysungur V. Iatrogenic tracheal rupture during intubation with a double-lumen tube. *Thorac Cardiovasc Surg* 2010; 58: 54–56.
 17. Kim J, Lim T and Bahk JH. Tracheal laceration during intubation of a double-lumen tube and intraoperative fiberoptic bronchoscopic evaluation through an LMA in the lateral position -A case report. *Korean J Anesthesiol* 2011; 60: 285–289.
 18. Davis L, Cook-Sather SD and Schreiner MS. Lighted stylet tracheal intubation: a review. *Anesth Analg* 2000; 90: 745–756.
 19. Malik MA, Maharaj CH, Harte BH, et al. Comparison of Macintosh, Truview EVO2, Glidescope, and Airwayscope laryngoscope use in patients with cervical spine immobilization. *Br J Anaesth* 2008; 101: 723–730.
 20. Malik MA, Subramaniam R, Maharaj CH, et al. Randomized controlled trial of the Pentax AWS, Glidescope, and Macintosh laryngoscopes in predicted difficult intubation. *Br J Anaesth* 2009; 103: 761–768.
 21. Teoh WH, Saxena S, Shah MK, et al. Comparison of three videolaryngoscopes: Pentax Airway Scope, C-MAC, Glidescope vs the Macintosh laryngoscope for tracheal intubation. *Anaesthesia* 2010; 65: 1126–1132.
 22. Aziz MF, Dillman D, Fu R, et al. Comparative effectiveness of the C-MAC video laryngoscope versus direct laryngoscopy in the setting of the predicted difficult airway. *Anesthesiology* 2012; 116: 629–636.
 23. Graham DH, Doll WA, Robinson AD, et al. Intubation with lighted stylet. *Can J Anaesth* 1991; 38: 261–262.
 24. Hung OR, Pytko S, Morris I, et al. Clinical trial of a new lightwand device (Trachlight) to intubate the trachea. *Anesthesiology* 1995; 83: 509–514.
 25. Aziz MF, Abrons RO, Cattano D, et al. First-attempt intubation success of video laryngoscopy in patients with anticipated difficult direct laryngoscopy: a multicenter randomized controlled trial comparing the C-MAC D-Blade versus the GlideScope in a mixed provider and diverse patient population. *Anesth Analg* 2016; 122: 740–750.
 26. Greenland KB, Edwards MJ, Hutton NJ, et al. Changes in airway configuration with different head and neck positions using magnetic resonance imaging of normal airways: a new concept with possible clinical applications. *Br J Anaesth* 2010; 105: 683–690.
 27. Enver N, Doruk C, Kara E, et al. A morphometric analysis of laryngeal anatomy: a cadaveric study. *Kulak Burun Bogaz Ihtis Derg (The Turkish Journal of Ear Nose and*

- Throat*) 2018; 28: 71–77. doi:10.5606/Tr-ENT.2018.35229.
28. Jain M and Dhall U. Morphometry of the thyroid and cricoid cartilages in adults. *J Anat Soc India* 2008; 57: 119–123.
29. Kim H, Chang JE, Ryu JH, et al. Retrospective analysis of vocal cord-to-suprasternal notch distance: implications for preventing endotracheal tube cuff-induced vocal cord injury. *Medicine (Baltimore)* 2017; 96: e6155.
30. Ellis DG, Jakymec A, Kaplan RM, et al. Guided orotracheal intubation in the operating room using a lighted stylet: a comparison with direct laryngoscopic technique. *Anesthesiology* 1986; 64: 823–826.
31. Hung OR, Pytka S, Morris I, et al. Lightwand intubation: II–Clinical trial of a new lightwand for tracheal intubation in patients with difficult airways. *Can J Anaesth* 1995; 42: 826–830.