

Molecular heterogeneity in intrahepatic cholangiocarcinoma

Keun Soo Ahn, Koo Jeong Kang

ORCID number: Keun Soo Ahn 0000-0001-8738-8009; Koo Jeong Kang 0000-0003-1385-8308.

Author contributions: Ahn KS designed the study, analyzed the data, and wrote the paper; Kang KJ collected the data and approved the final manuscript.

Supported by the National Research Foundation of Korea Grant funded by the Korea Government, No. 2018R1C1B3004435.

Conflict-of-interest statement: Authors declare no conflict of interests for this article.

Open-Access: This article is an open-access article that was selected by an in-house editor and fully peer-reviewed by external reviewers. It is distributed in accordance with the Creative Commons Attribution NonCommercial (CC BY-NC 4.0) license, which permits others to distribute, remix, adapt, build upon this work non-commercially, and license their derivative works on different terms, provided the original work is properly cited and the use is non-commercial. See: <http://creativecommons.org/licenses/by-nc/4.0/>

Manuscript source: Invited manuscript

Specialty type: Gastroenterology

Keun Soo Ahn, Koo Jeong Kang, Department of Surgery, Keimyung University Dongsan Hospital, Keimyung University School of Medicine, Daegu 42601, South Korea

Corresponding author: Keun Soo Ahn, MD, PhD, Associate Professor, Department of Surgery, Keimyung University Dongsan Hospital, Keimyung University School of Medicine, No.1035 Dalgubeol-daero, Dalseo-gu, Daegu 42601, South Korea. ahnksmd@gmail.com

Abstract

Intrahepatic cholangiocarcinoma (iCCA) is a heterogeneous primary liver cancer, and currently there exist only a few options of targeted therapy. Histopathologically, iCCA is sub-classified according to morphology (mass forming type, periductal infiltrating type, and intraductal growing type) and histology (small duct type and large duct type). According to different histopathological types, clinical features such as risk factors and prognosis vary. Recent developments in genomic profiling have revealed several molecular markers for poor prognosis and activation of oncogenic pathways. Exploration of molecular characteristics of iCCA in each patient is a major challenge in a clinical setting, and there is no effective molecular-based targeted therapy. However, several recent studies suggested molecular-based subtypes with corresponding clinical and pathological features. Even though the subtypes have not yet been validated, it is possible that molecular features can be predicted based on clinicopathological characteristics and that this could be used for a more rational approach to integrative clinical and molecular subclassification and targeted therapy. In this review, we explored the genomic landscape of iCCA and attempted to find relevance between clinicopathologic and molecular features in molecular subtypes in several published studies. The results reveal future directions that may lead to a rational approach to the targeted therapy.

Key Words: Cholangiocarcinoma; Mutation; Gene expression; Pathway; Target therapy; Molecular

©The Author(s) 2020. Published by Baishideng Publishing Group Inc. All rights reserved.

Core Tip: Intrahepatic cholangiocarcinoma (iCCA) is a histopathologically and molecularly heterogeneous tumor. Recent developments in genomic profiling have revealed several molecular markers for poor prognosis and activation of oncogenic pathways. Exploration of molecular characteristics of iCCA in each patient is a major

and Hepatology

Country/Territory of origin: South Korea**Peer-review report's scientific quality classification**

Grade A (Excellent): 0
 Grade B (Very good): B
 Grade C (Good): C
 Grade D (Fair): 0
 Grade E (Poor): 0

Received: July 20, 2020**Peer-review started:** July 20, 2020**First decision:** September 24, 2020**Revised:** October 1, 2020**Accepted:** October 26, 2020**Article in press:** October 26, 2020**Published online:** December 27, 2020**P-Reviewer:** Huang CY,

Leardkamolkarn V

S-Editor: Zhang H**L-Editor:** Filipodia**P-Editor:** Zhang YL

challenge in a clinical setting, and there exists no effective molecular-based targeted therapy. Therefore, the analysis of relevance between molecular and clinicopathological features is very important. The present analysis showed that the molecular subtypes of iCCA have distinct clinicopathologic features and prognostic differences. For developing effective targeted and personalized therapies based on clinical and molecular understanding, future additional large scale studies are needed.

Citation: Ahn KS, Kang KJ. Molecular heterogeneity in intrahepatic cholangiocarcinoma. *World J Hepatol* 2020; 12(12): 1148-1157

URL: <https://www.wjgnet.com/1948-5182/full/v12/i12/1148.htm>

DOI: <https://dx.doi.org/10.4254/wjh.v12.i12.1148>

INTRODUCTION

Cholangiocarcinoma (CCA) is a malignant tumor that arises from biliary epithelium in any portion of the bile duct. Intrahepatic cholangiocarcinoma (iCCA) arises from small peripheral bile duct to second-order segmental bile duct. Risk factors, clinical symptoms, type of surgical resection, and prognosis of iCCA are different from those of extrahepatic CCA (eCCA; Klatskin tumor and distal bile duct cancer)^[1,2]. iCCA is the second most common primary malignant liver tumor and accounts for 10%-15% of hepatobiliary neoplasms^[3]; however, recently, there has been an increase in the incidence and associated significance of pathogenic, clinical, and therapeutic challenges^[4]. Based on morphological and gross appearance, iCCA can be further classified into three subtypes: Mass forming (MF), periductal infiltrating (PI), and intraductal growing (IG). The prognosis of the subtypes differ according to gross morphology^[5]. Due to pathologic heterogeneity and lack of specific symptoms, iCCA is hard to diagnose at the early stages, and most of the patients are at an advanced stage at the time of diagnosis. Therefore, prognosis after curative surgical resection is dismal, and efficacy of chemotherapy or targeted therapy is limited^[6].

Recent molecular analyses revealed several markers for poor prognosis and activation of oncogenic pathways (KRAS mutation, human epidermal growth factor receptor 2 (HER2), and epidermal growth factor receptor (EGFR) signaling)^[6,7]. In addition, various recurrent mutations and fusions have been reported, including *IDH1* and *IDH2*, *BRAF*, *TP53*, and *FGFR2* genes^[7,8]. These molecular findings demonstrate a more integrative analysis of clinical and molecular alterations in iCCA. However, there exist a few other challenges. First of all, the molecular characteristics of tumor heterogeneity are not yet clear. Second, integrative relevance between clinical and molecular characteristics is not enough; and finally, most prevalent oncogenic alterations in CCA are still undruggable. Understanding the molecular characteristics in these heterogeneous tumors may derive specific biologically meaningful subtypes that can be used to define more rational potential targeted therapy.

This review provides an overview of the genetic characteristics and heterogeneity of iCCA with a focus on molecular subtypes and their relevance with the clinicopathological phenotype. Furthermore, the role of molecular markers to stratify patients based on their prognosis and response to therapies is discussed.

HISTOPATHOLOGIC CLASSIFICATION OF iCCA

Histological classification of iCCA is important for understanding the molecular heterogeneity of iCCA. Several investigations have revealed that a whole range of phenotypical traits of hepatocytes, cholangiocytes, and progenitor cells was seen in primary liver cancer [hepatocellular carcinoma (HCC) and iCCA]. It has been suggested that iCCA originated from biliary tree stem cells located within the peribiliary gland as well as hepatic progenitor cells within canals of Hering^[2]. Hepatic bipotent progenitor cells along the small intrahepatic bile duct possibly differentiate not only into hepatocytes but also into cholangiocytes, which can lead to iCCA^[9,10]. Consequently, two different histological types of iCCA may develop: One originating from hepatic stem cell-derived lineages with stem-like molecular characteristics similar to those in HCC or combined HCC-CCA and the other originating from biliary

tree progenitor stem cell-derived cholangiocytes found along the large intrahepatic bile duct with characteristics similar to perihilar or extrahepatic CCA^[2,11-13]. Histologically, iCCA is defined as an adenocarcinoma formed by columnar and cuboidal epithelial cells^[1,14].

Based on the histological findings, conventional iCCA can be classified into two main subtypes. Small bile duct type iCCA may derive from small intrahepatic bile ducts; hepatic progenitor cells present as small-sized tubular or acinar adenocarcinoma with scant mucin production^[11,14-16]. Small bile duct type is either represented as peripheral type or cholangiolar type^[17,18]. Meanwhile, large duct type arises from biliary tree progenitor stem cell and is constituted by mucin-producing columnar tumor cells in large segmental bile ducts or papillary architecture^[11,14-17,19]. Large duct type has been represented as a perihilar type or bile duct type in other studies^[17,18]. The gross and histological features of large bile duct type iCCA are similar to those of perihilar CCA and distal CCA. In addition, the majority of PI and IG has large bile duct type^[11,17,18]. However, the MF type, which is the most prominent morphologic type, is more heterogeneous as it comprises of both small duct type and large duct type^[17,18].

Although the two histological subtypes belong to iCCA, their clinical and molecular features are quite different. While viral hepatitis and cirrhosis are the risk factors of small duct type, cholangitis and parasite infection are the main cause of large duct type^[17,18]. Both subtypes have different precursor lesions and show different survival outcomes^[18]. Furthermore, they show different immunophenotypes like the abundant expression of mucin families, S100P, and anterior gradient homolog 2 in the large duct type, and N-cadherin and neural cell adhesion molecule 1 in the small duct type^[11,17,18,20]. These histopathological heterogeneities based on cell origin are critical for understanding the heterogeneity of iCCA as well as heterogeneous molecular characteristics of iCCA.

MOLECULAR ALTERATIONS IN iCCA

Recent technological advancements have helped in understanding the mutational landscape of iCCA. Mutations in common driver oncogenes and suppressor genes are summarized in Table 1. Due to a small number of samples compared to other cancer and pathological heterogeneity, the prevalence of the mutation is variable across studies. However, several key driver somatic mutations commonly seen in other tumors, such as *KRAS*, *BRAF*, *TP53*, *BAP1*, and *ARID1A*, are also frequently identified in iCCA. Other driver genes like *BRAF*, *PIK3CA*, *GNAS*, *EGFR*, and *ERBBR/HER2* have also been identified in iCCA, but at a much lower frequency in most of the cohorts^[6,21-23]. The presence of *EGFR*, *TP53*, and *KRAS* mutation is known as poor prognostic factor^[6,21,24]. Mutation of *TERT* promoter and *ALB* gene, which are frequently seen in HCC, are also detected in CCA, but only in iCCA or combined HCC and CCA samples with less frequency^[23]. Meanwhile, isocitrate dehydrogenase (*IDH*)1 and *IDH2* mutations have been reported in 10%-20% of iCCA cases^[23]. Interestingly, a large extent of *IDH* mutation has been observed in iCCA and not in eCCA and rarely identified in HCC^[23,25]. *IDH* mutation is associated with a better prognosis^[26]. In one large scale study, *IDH1/2* mutations were identified to be associated with improved overall survival^[27]; however, as the incidence of *IDH* mutation is not frequent, survival impacts of *IDH* mutation is not yet clear^[28]. In iCCA, frequency of fibroblast growth factor receptor 2 (*FGFR2*) fusion is reported as 10%-15%^[29,30]. *FGFR2* pairs with some genes such as *TACC1*, *BICCI*, *PRKACA*, *AHCYL*, and *PRKACB*. These fusions result in the constitutive activation of *FGFR2* and its oncogenic functions^[31]. The *FGFR* related pathway is involved in cellular migration and proliferation. Patients with *FGFR2* fusion show good prognosis, which suggests that *FGFR2* fusions can be a prognostic marker as well as potential target for therapy^[21,32]. Altered genes involving chromatin remodeling, such as *BAP1*, *ARID1A*, and *PBRM1*, are also frequently found in iCCA^[27]. Meanwhile, germline DNA mismatch repair deficiency (Lynch syndrome) has been reported to be associated with CCA^[33]. There exists a report that deleterious germline mutations in breast cancer gene 1/2, *RAD51D*, *MutL* homolog 1, and *MutS* homolog 2 were detected in 11% of CCA patients^[21].

Genomic alteration in CCA is highly heterogeneous, like pathologic features. Several studies identified different gene alterations between iCCA and eCCA^[21,34]. While alterations in *IDH1/2*, *BRAF*, *FGFR2*, *BAP1*, and *NRAS* are frequently found in iCCA, *TP53*, *KRAS*, *SMAD4*, and *BRAF* mutations are common in eCCA^[35]. Interestingly, some of the altered genes commonly found in eCCA such as *KRAS*,

Table 1 Frequency of genetic alteration in intrahepatic cholangiocarcinoma

Pathway	Gene	Frequency of alteration
NADPH metabolism	<i>IDH1/2</i>	4-36
Chromatic remodeling	<i>BAP1</i>	9%-25%
	<i>ARID1A</i>	11-36
	<i>PBRM1</i>	11-17
Cell cycle regulation and DNA damage response	<i>CDKN2A</i>	7
	<i>CDK6</i>	7
	<i>TP53</i>	3-38
	<i>BRCA1/2</i>	4
PI3K signaling	<i>PIK3CA</i>	4-6
	<i>PTEN</i>	1-11
Ras/Raf/MEK/ERK	<i>EGFR</i>	2.2
	<i>KRAS</i>	9-24
	<i>NRAS</i>	3.6
	<i>BRAF</i>	3-22
FGF	<i>FGFR2</i>	4-38

DNA: Deoxyribonucleic acid; ERK: Extracellular signal-regulated kinase; MEK: Mitogen-activated protein kinase kinase; NADPH: Nicotinamide adenosine dinucleotide phosphate; PI3K: Phosphoinositide-3-kinase.

SMAD4, and *TP53* were also shared by large duct types of iCCA. Whereas, small duct iCCA has frequent *IDH1/2* mutations and *FGFR2* gene fusion^[31,36]. Therefore, pathological characteristics and genetic alterations appear to be closely related to each other.

EPIGENETIC PROFILE OF iCCA

Epigenetic mechanisms of iCCA include histone modification, DNA methylation, and noncoding RNAs. In CCA, hypermethylation at the promoters of tumor suppressor genes has been reported^[37]. iCCA is a highly epigenetic regulated tumor type.

DNA methylation is an early molecular lesion of carcinogenesis; tumor suppressor promoter hypermethylation of tumor suppressor gene leads to transcriptional modification and inactivation, and hypomethylation of oncogenes results in activation^[38]. Most of the genes that were altered by CpG methylation belonged to wingless-related integration site (WNT), transforming growth factor beta, PI3K, MAPK, and NOTCH signaling pathways in iCCA^[39]. Like other cancers, promoter hypermethylation of tumor suppressor genes, such as *DAPK*, *SOX17*, and *RUNX3*, has been commonly reported^[40]. It is known that IDH mutations result in hypermethylation and induce silencing of *ARID1A*^[8].

MicroRNA (miRNA) plays a crucial role in diverse cellular processes and regulates gene function. Several pieces of research revealed that overexpression of miR-21 inhibits *TIMP3* and *PDCD4* and sequentially leads to cancer progression^[41]. Besides, miR-191, miR-200, miR-141, miR-204, miR-214, and miR-221 are involved in CCA development^[42]. Among these miRNAs, miR-21, miR-191, and miR-26a were identified as poor prognostic markers^[43]. Meanwhile, the high expression of several lncRNA (*H19*, *NEAT1*, *PVT1*, *CKDN2B-AS1*, and *HUILC*) has been reported to be associated with poor survival of CCA^[44,45].

However, most of the epigenetic mechanisms of iCCA have not been studied sufficiently, and their role as biomarkers and potential targeted therapies should be extensively investigated.

EXPRESSION PROFILE AND FUNCTIONAL GENOMIC PATHWAY OF iCCA

Several studies based on microarray or NGS revealed the expression profile and oncogenic pathway of iCCA. The major key oncogenic molecules, including tumor necrosis factor, transforming growth factor, extracellular regulated-signal kinase, epidermal growth factor, RAS, AKT, p53, NOTCH, and platelet-derived growth factor, are deregulated in iCCA. Immune response-related pathways and inflammation associated with signatures are also enriched^[6,8,22,24]. Aberrant HER2 expression is seen in about 30% of iCCA, and it is related to poor prognosis with coactivation of ERBB3 and EGFR2 as well as mesenchymal epithelial transition factor and mammalian target of rapamycin^[6]. Inflammation associated signatures are commonly activated in iCCA, but their oncologic and prognostic role is controversial^[22,24]. Activation of the WNT pathway is often seen in iCCA, and it relates to inflammatory reaction because macrophages in the stroma surrounding the tumor are required for the maintenance of activated WNT pathway^[46].

The oncogenic signatures are also found in many other cancers. However, deregulated pathways are different according to pathologic and molecular subtypes; therefore, subtype-specific activated pathways are important to assess biology.

INTEGRATIVE CLINICAL-MOLECULAR SUBTYPES OF iCCA

Based on the genomic profile, a few studies have suggested molecular subtype of iCCA beyond anatomical and histological subclassification (Table 2). The recent advances in the molecular classification allow better characterization of heterogeneity of iCCA. Furthermore, they provide insight into the integrated approach of clinical and molecular characterization of iCCA.

Although each subclassification has some heterogeneity, the molecular feature of iCCA is dichotomized two subtypes that have different survival and clinical outcomes^[6,8,22,24,47]. Generally, the poor prognostic molecular subtype is associated with the KRAS mutation. Also, BRAF, ERBB2, and HER alterations are often seen in a poor prognostic subtype. On the other hand, IDH mutation and FGFR fusion are commonly seen in the good prognostic subtype. The molecular subclasses were reported to be rather related to clinical and pathologic features. While PI type, similar to eCCA, is commonly seen in the poor prognostic subtype, the MF type is almost evenly distributed in both good and poor prognostic subtypes^[24]. Large duct type, history of cholangitis and parasite infection, and elevated levels of serum biomarkers (carcinoembryonic antigen and carbohydrate antigen 19-9) are associated with poor prognostic molecular subtype, while small duct type and history of viral hepatitis are associated with good prognostic molecular subtype^[24] (Figure 1).

Several molecular subclassifications in the reported studies provide information about molecular heterogeneity in addition to histopathological heterogeneity. The integrated clinical and molecular subclassifications would be helpful to provide a more rational approach to overcome clinical and molecular heterogeneity. Molecular profile of iCCA is helpful for early diagnosis and prognosis prediction and may potentially provide personalized treatment. However, exploration of molecular characteristics of iCCA in each patient is a major challenge in a clinical setting because of the high cost for evaluating molecular characterization. If molecular subtypes of iCCA have specific clinical and pathologic features, molecular subtypes can be predicted from clinical features. Although the subclassifications reported in several studies have a few differences based on demographic characteristics and study methods, there is still no consensus on the molecular subclass. The present review shows that clinical and molecular relevance based on molecular subclassification has been exploring and may establish integrative clinical and molecular subclassification soon. Since the number of patients is not sufficient in iCCA compared to other cancers, further large scale studies are necessary for validation and establishment of molecular classification.

Still, molecular-based target therapy is not considered to be effective in CCA due to molecular heterogeneity. However, the establishment of molecular subtypes can promote the development of effective subtype-specific therapeutic molecular targeted therapy. Lapatinib, a dual inhibitor of EGFR and HER2, has been reported to be effective in cell lines that had genetic characteristics similar to poor prognostic subtype^[6], while gemcitabine was identified to be effective in cell lines with similar expression profile to good prognostic subtype, which had enriched gemcitabine sensitive genes^[24]. Although these are the outcomes of cell line studies and not

Table 2 Integrative clinical-molecular subclassification of intrahepatic cholangiocarcinoma

Good prognostic subclass		Poor prognostic subclass
GSE26566		Periductal infiltrating type, perineural invasion; KRAS mutation, EGFR and HER2 signatures
GSE32225	Well differentiated tumor; inflammation-related signatures	Poor differentiated tumor; RTK-related pathways (AKT, MET, RAS/RAF/MAPK); overexpression of EGFR; KRAS mutation
GSE32879		EMT-related signatures; TGFβ1, NCAM1, CD133
GSE89749	Fluke-negative; FGFR fusion; BAP1, IDH mutation	Fluke-positive; BRCA1/2, TP53 mutation; ERBB2 gain
GSE107943	Small duct type (cholangiolar type); underlying hepatitis, cirrhosis; metabolism-related signatures; FGFR2 fusion	Large duct type (bile duct type); Elevated CEA, CA 19-9; underlying cholangitis; P53, inflammation-related signatures; KRAS mutation
TCGA ¹	Mitochondria/metabolic-related signatures; IDH, BAP1 mutation	Inflammation-related pathways

¹In The Cancer Genome Atlas, two subtypes have no statistical different survival.

BRCA1/2: Breast cancer gene 1/2; CA 19-9: Carbohydrate antigen 19-9; CEA: Carcinoembryonic antigen; EGFR: Endothelial growth factor receptor; EMT: Epithelial to mesenchymal transition; FGFR2: Fibroblast growth factor receptor 2; HER2: Human epidermal growth factor receptor 2; IDH: Isocitrate dehydrogenase; MAPK: Mitogen-activated protein kinase; NCAM1: Neural cell adhesion molecule; TCGA: The Cancer Genome Atlas; TGFβ1: Transforming growth factor beta 1.

validated clinical data, it is hypothesized that additional applications of drug study on different subtype signaling pathways may be helpful to stratify patients for targeted approaches for the treatment of iCCA.

CONCLUSION

In the present study, we reviewed the molecular heterogeneity of iCCA in association with the clinicopathological features. Several recent studies have revealed molecular characteristics of iCCA and suggested several molecular subclassifications. Molecular study of iCCA may help identify patients at risk of developing iCCA, predicting prognosis, and targeting approach to treatment. However, molecular exploration in all patients is not feasible because of the high cost. Accordingly, analysis of relevance between molecular and clinicopathological features is considered as imperative because if clinicomolecular relevance is established, molecular characteristics can be predicted based on clinical features in each patient.

The present analysis showed that the molecular subtypes of iCCA have distinct clinicopathologic features and prognostic differences. However, integrative clinical and molecular subclassification is not yet validated. For developing effective targeted and personalized therapies based on clinical and molecular knowledge, future additional large scale studies are necessary.

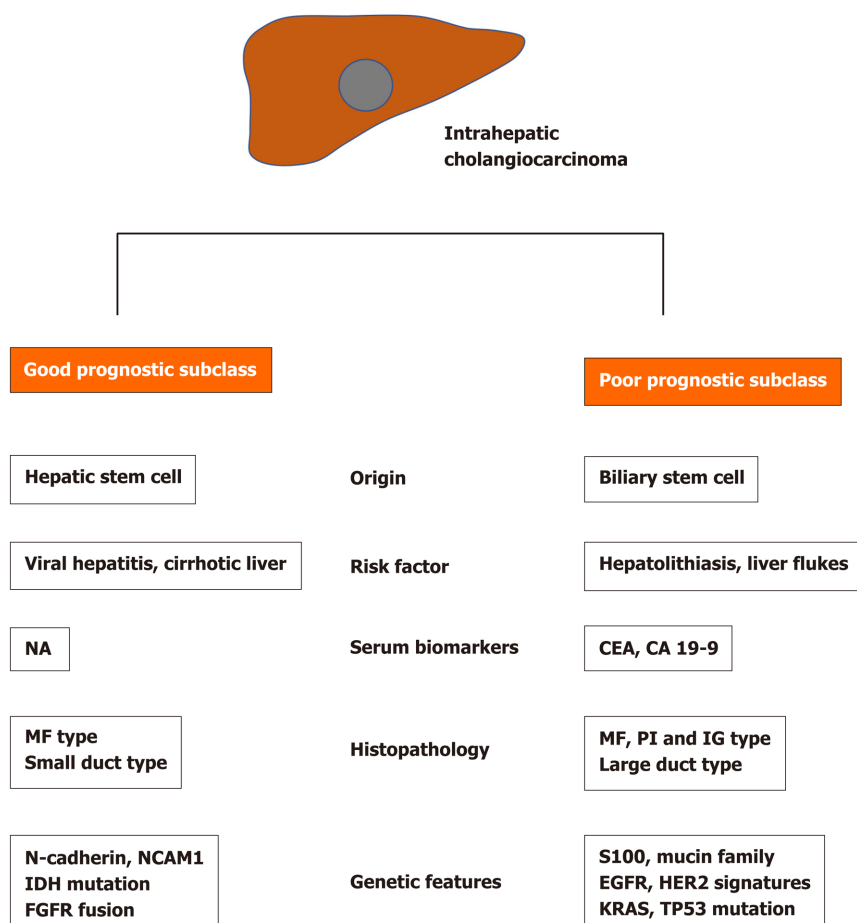


Figure 1 Summary of clinical and molecular characteristics of molecular-based subtypes of intrahepatic cholangiocarcinoma. CA 19-9: Carbohydrate antigen 19-9; CEA: Carcinoembryonic antigen; FGFR2: Fibroblast growth factor receptor 2; HER2: Human epidermal growth factor receptor; IDH: Isocitrate dehydrogenase; IG: Intraductal growing; MF: Mass forming; PI: Periductal infiltrating.

REFERENCES

- 1 **Krasinskas AM.** Cholangiocarcinoma. *Surg Pathol Clin* 2018; **11**: 403-429 [PMID: [29751883](#) DOI: [10.1016/j.path.2018.02.005](#)]
- 2 **Cardinale V, Semeraro R, Torrice A, Gatto M, Napoli C, Bragazzi MC, Gentile R, Alvaro D.** Intra-hepatic and extra-hepatic cholangiocarcinoma: New insight into epidemiology and risk factors. *World J Gastrointest Oncol* 2010; **2**: 407-416 [PMID: [21160904](#) DOI: [10.4251/wjgo.v2.i11.407](#)]
- 3 **Blechacz BR, Gores GJ.** Cholangiocarcinoma. *Clin Liver Dis* 2008; **12**: 131-150, ix [PMID: [18242501](#) DOI: [10.1016/j.cld.2007.11.003](#)]
- 4 **Patel T.** Worldwide trends in mortality from biliary tract malignancies. *BMC Cancer* 2002; **2**: 10 [PMID: [11991810](#) DOI: [10.1186/1471-2407-2-10](#)]
- 5 **Bagante F, Spolverato G, Weiss M, Alexandrescu S, Marques HP, Aldrighetti L, Maithel SK, Pulitano C, Bauer TW, Shen F, Poultides GA, Soubrane O, Martel G, Groot Koerkamp B, Guglielmi A, Itaru E, Pawlik TM.** Impact of Morphological Status on Long-Term Outcome Among Patients Undergoing Liver Surgery for Intrahepatic Cholangiocarcinoma. *Ann Surg Oncol* 2017; **24**: 2491-2501 [PMID: [28466403](#) DOI: [10.1245/s10434-017-5870-y](#)]
- 6 **Andersen JB, Spee B, Blechacz BR, Avital I, Komuta M, Barbour A, Conner EA, Gillen MC, Roskams T, Roberts LR, Factor VM, Thorgeirsson SS.** Genomic and genetic characterization of cholangiocarcinoma identifies therapeutic targets for tyrosine kinase inhibitors. *Gastroenterology* 2012; **142**: 1021-1031. e15 [PMID: [22178589](#) DOI: [10.1053/j.gastro.2011.12.005](#)]
- 7 **Jusakul A, Cutcutache I, Yong CH, Lim JQ, Huang MN, Padmanabhan N, Nellore V, Kongpetch S, Ng AWT, Ng LM, Choo SP, Myint SS, Thanan R, Nagarajan S, Lim WK, Ng CCY, Boot A, Liu M, Ong CK, Rajasegaran V, Lie S, Lim AST, Lim TH, Tan J, Loh JL, McPherson JR, Khuntikeo N, Bhudhisawasdi V, Yongvanit P, Wongkham S, Totoki Y, Nakamura H, Arai Y, Yamasaki S, Chow PK, Chung AYE, Ooi LLPJ, Lim KH, Dima S, Duda DG, Popescu I, Broet P, Hsieh SY, Yu MC, Scarpa A, Lai J, Luo DX, Carvalho AL, Vettore AL, Rhee H, Park YN, Alexandrov LB, Gordan R, Rozen SG, Shibata T, Pairojkul C, Teh BT, Tan P.** Whole-Genome and Epigenomic Landscapes of Etiologically Distinct Subtypes of Cholangiocarcinoma. *Cancer Discov* 2017; **7**: 1116-1135 [PMID: [28667006](#) DOI: [10.1158/2159-8290.CD-17-0368](#)]

- 8 **Farshidfar F**, Zheng S, Gingras MC, Newton Y, Shih J, Robertson AG, Hinoue T, Hoadley KA, Gibb EA, Roszik J, Covington KR, Wu CC, Shinbrot E, Stransky N, Hegde A, Yang JD, Reznik E, Sadeghi S, Pedamallu CS, Ojesina AI, Hess JM, Auman JT, Rhie SK, Bowlby R, Borad MJ; Cancer Genome Atlas Network; Zhu AX; Stuart JM; Sander C; Akbani R; Cherniack AD; Deshpande V; Mounajjed T; Foo WC; Torbenson MS; Kleiner DE; Laird PW; Wheeler DA; McRee AJ; Bathe OF; Andersen JB; Bardeesy N; Roberts LR; Kwong LN. Integrative Genomic Analysis of Cholangiocarcinoma Identifies Distinct IDH-Mutant Molecular Profiles. *Cell Rep* 2017; **18**: 2780-2794 [PMID: [28297679](#) DOI: [10.1016/j.celrep.2017.02.033](#)]
- 9 **Moeini A**, Sia D, Bardeesy N, Mazzaferro V, Llovet JM. Molecular Pathogenesis and Targeted Therapies for Intrahepatic Cholangiocarcinoma. *Clin Cancer Res* 2016; **22**: 291-300 [PMID: [26405193](#) DOI: [10.1158/1078-0432.CCR-14-3296](#)]
- 10 **Kordes C**, Häussinger D. Hepatic stem cell niches. *J Clin Invest* 2013; **123**: 1874-1880 [PMID: [23635785](#) DOI: [10.1172/JCI66027](#)]
- 11 **Komuta M**, Govaere O, Vandecaveye V, Akiba J, Van Steenberghe W, Verslype C, Laleman W, Pirenne J, Aerts R, Yano H, Nevens F, Topal B, Roskams T. Histological diversity in cholangiocellular carcinoma reflects the different cholangiocyte phenotypes. *Hepatology* 2012; **55**: 1876-1888 [PMID: [22271564](#) DOI: [10.1002/hep.25595](#)]
- 12 **Cardinale V**, Bragazzi MC, Carpino G, Torrice A, Fraveto A, Gentile R, Pasqualino V, Melandro F, Aliberti C, Bastianelli C, Brunelli R, Berloco PB, Gaudio E, Alvaro D. Cholangiocarcinoma: increasing burden of classifications. *Hepatobiliary Surg Nutr* 2013; **2**: 272-280 [PMID: [24570958](#) DOI: [10.3978/j.issn.2304-3881.2013.10.02](#)]
- 13 **Wang Y**, Lanzoni G, Carpino G, Cui CB, Dominguez-Bendala J, Wauthier E, Cardinale V, Oikawa T, Pileggi A, Gerber D, Furth ME, Alvaro D, Gaudio E, Inverardi L, Reid LM. Biliary tree stem cells, precursors to pancreatic committed progenitors: evidence for possible life-long pancreatic organogenesis. *Stem Cells* 2013; **31**: 1966-1979 [PMID: [23847135](#) DOI: [10.1002/stem.1460](#)]
- 14 **Nakanuma Y**, Kakuda Y. Pathologic classification of cholangiocarcinoma: New concepts. *Best Pract Res Clin Gastroenterol* 2015; **29**: 277-293 [PMID: [25966428](#) DOI: [10.1016/j.bpg.2015.02.006](#)]
- 15 **Aishima S**, Kuroda Y, Nishihara Y, Iguchi T, Taguchi K, Taketomi A, Maehara Y, Tsuneyoshi M. Proposal of progression model for intrahepatic cholangiocarcinoma: clinicopathologic differences between hilar type and peripheral type. *Am J Surg Pathol* 2007; **31**: 1059-1067 [PMID: [17592273](#) DOI: [10.1097/PAS.0b013e31802b34b6](#)]
- 16 **Hayashi A**, Misumi K, Shibahara J, Arita J, Sakamoto Y, Hasegawa K, Kokudo N, Fukayama M. Distinct Clinicopathologic and Genetic Features of 2 Histologic Subtypes of Intrahepatic Cholangiocarcinoma. *Am J Surg Pathol* 2016; **40**: 1021-1030 [PMID: [27259014](#) DOI: [10.1097/PAS.0000000000000670](#)]
- 17 **Akita M**, Fujikura K, Ajiki T, Fukumoto T, Otani K, Azuma T, Itoh T, Ku Y, Zen Y. Dichotomy in intrahepatic cholangiocarcinomas based on histologic similarities to hilar cholangiocarcinomas. *Mod Pathol* 2017; **30**: 986-997 [PMID: [28338651](#) DOI: [10.1038/modpathol.2017.22](#)]
- 18 **Liau JY**, Tsai JH, Yuan RH, Chang CN, Lee HJ, Jeng YM. Morphological subclassification of intrahepatic cholangiocarcinoma: etiological, clinicopathological, and molecular features. *Mod Pathol* 2014; **27**: 1163-1173 [PMID: [24406866](#) DOI: [10.1038/modpathol.2013.241](#)]
- 19 **Cardinale V**, Wang Y, Carpino G, Reid LM, Gaudio E, Alvaro D. Mucin-producing cholangiocarcinoma might derive from biliary tree stem/progenitor cells located in peribiliary glands. *Hepatology* 2012; **55**: 2041-2042 [PMID: [22262236](#) DOI: [10.1002/hep.25587](#)]
- 20 **Nakanuma Y**, Uchida T, Sato Y, Uesaka K. An S100P-positive biliary epithelial field is a preinvasive intraepithelial neoplasm in nodular-sclerosing cholangiocarcinoma. *Hum Pathol* 2017; **60**: 46-57 [PMID: [27984121](#) DOI: [10.1016/j.humpath.2016.10.003](#)]
- 21 **Churi CR**, Shroff R, Wang Y, Rashid A, Kang HC, Weatherly J, Zuo M, Zinner R, Hong D, Meric-Bernstam F, Janku F, Crane CH, Mishra L, Vauthey JN, Wolff RA, Mills G, Javle M. Mutation profiling in cholangiocarcinoma: prognostic and therapeutic implications. *PLoS One* 2014; **9**: e115383 [PMID: [25536104](#) DOI: [10.1371/journal.pone.0115383](#)]
- 22 **Sia D**, Hoshida Y, Villanueva A, Roayaie S, Ferrer J, Tabak B, Peix J, Sole M, Tovar V, Alsinet C, Cornella H, Klotzle B, Fan JB, Cotsoglou C, Thung SN, Fuster J, Waxman S, Garcia-Valdecasas JC, Bruix J, Schwartz ME, Beroukhim R, Mazzaferro V, Llovet JM. Integrative molecular analysis of intrahepatic cholangiocarcinoma reveals 2 classes that have different outcomes. *Gastroenterology* 2013; **144**: 829-840 [PMID: [23295441](#) DOI: [10.1053/j.gastro.2013.01.001](#)]
- 23 **Cancer Genome Atlas Research Network**. Cancer Genome Atlas Research Network. Comprehensive and Integrative Genomic Characterization of Hepatocellular Carcinoma. *Cell* 2017; **169**: 1327-1341. e23 [PMID: [28622513](#) DOI: [10.1016/j.cell.2017.05.046](#)]
- 24 **Ahn KS**, O'Brien D, Kang YN, Mounajjed T, Kim YH, Kim TS, Kocher JA, Allotey LK, Borad MJ, Roberts LR, Kang KJ. Prognostic subclass of intrahepatic cholangiocarcinoma by integrative molecular-clinical analysis and potential targeted approach. *Hepatol Int* 2019; **13**: 490-500 [PMID: [31214875](#) DOI: [10.1007/s12072-019-09954-3](#)]
- 25 **Fujimoto A**, Furuta M, Shiraishi Y, Gotoh K, Kawakami Y, Arihiro K, Nakamura T, Ueno M, Ariizumi S, Nguyen HH, Shigemizu D, Abe T, Boroevich KA, Nakano K, Sasaki A, Kitada R, Maejima K, Yamamoto Y, Tanaka H, Shibuya T, Shibata T, Ojima H, Shimada K, Hayami S, Shigekawa Y, Aikata H, Ohdan H, Marubashi S, Yamada T, Kubo M, Hirano S, Ishikawa O, Yamamoto M, Yamaue H, Chayama K, Miyano S, Tsunoda T, Nakagawa H. Whole-genome mutational landscape of liver cancers displaying biliary phenotype reveals hepatitis impact and

- molecular diversity. *Nat Commun* 2015; **6**: 6120 [PMID: [25636086](#) DOI: [10.1038/ncomms7120](#)]
- 26 **Wang P**, Dong Q, Zhang C, Kuan PF, Liu Y, Jeck WR, Andersen JB, Jiang W, Savich GL, Tan TX, Auman JT, Hoskins JM, Misher AD, Moser CD, Yourstone SM, Kim JW, Cibulskis K, Getz G, Hunt HV, Thorgerirsson SS, Roberts LR, Ye D, Guan KL, Xiong Y, Qin LX, Chiang DY. Mutations in isocitrate dehydrogenase 1 and 2 occur frequently in intrahepatic cholangiocarcinomas and share hypermethylation targets with glioblastomas. *Oncogene* 2013; **32**: 3091-3100 [PMID: [22824796](#) DOI: [10.1038/nc.2012.315](#)]
 - 27 **Jiao Y**, Pawlik TM, Anders RA, Selaru FM, Streppel MM, Lucas DJ, Niknafs N, Guthrie VB, Maitra A, Argani P, Offerhaus GJA, Roa JC, Roberts LR, Gores GJ, Popescu I, Alexandrescu ST, Dima S, Fassan M, Simbolo M, Mafficini A, Capelli P, Lawlor RT, Ruzzenente A, Guglielmi A, Tortora G, de Braud F, Scarpa A, Jarnagin W, Klimstra D, Karchin R, Velculescu VE, Hruban RH, Vogelstein B, Kinzler KW, Papadopoulos N, Wood LD. Exome sequencing identifies frequent inactivating mutations in BAP1, ARID1A and PBRM1 in intrahepatic cholangiocarcinomas. *Nat Genet* 2013; **45**: 1470-1473 [PMID: [24185509](#) DOI: [10.1038/ng.2813](#)]
 - 28 **Goyal L**, Govindan A, Sheth RA, Nardi V, Blaszkowsky LS, Faris JE, Clark JW, Ryan DP, Kwak EL, Allen JN, Murphy JE, Saha SK, Hong TS, Wo JY, Ferrone CR, Tanabe KK, Chong DQ, Deshpande V, Borger DR, Iafrate AJ, Bardeesy N, Zheng H, Zhu AX. Prognosis and Clinicopathologic Features of Patients With Advanced Stage Isocitrate Dehydrogenase (IDH) Mutant and IDH Wild-Type Intrahepatic Cholangiocarcinoma. *Oncologist* 2015; **20**: 1019-1027 [PMID: [26245674](#) DOI: [10.1634/theoncologist.2015-0210](#)]
 - 29 **Graham RP**, Barr Fritcher EG, Pestova E, Schulz J, Sitailo LA, Vasmatzis G, Murphy SJ, McWilliams RR, Hart SN, Halling KC, Roberts LR, Gores GJ, Couch FJ, Zhang L, Borad MJ, Kipp BR. Fibroblast growth factor receptor 2 translocations in intrahepatic cholangiocarcinoma. *Hum Pathol* 2014; **45**: 1630-1638 [PMID: [24837095](#) DOI: [10.1016/j.humpath.2014.03.014](#)]
 - 30 **Mahipal A**, Tella SH, Kommalapati A, Anaya D, Kim R. FGFR2 genomic aberrations: Achilles heel in the management of advanced cholangiocarcinoma. *Cancer Treat Rev* 2019; **78**: 1-7 [PMID: [31255945](#) DOI: [10.1016/j.ctrv.2019.06.003](#)]
 - 31 **Nakamura H**, Arai Y, Totoki Y, Shiota T, Elzawahry A, Kato M, Hama N, Hosoda F, Urushidate T, Ohashi S, Hiraoka N, Ojima H, Shimada K, Okusaka T, Kosuge T, Miyagawa S, Shibata T. Genomic spectra of biliary tract cancer. *Nat Genet* 2015; **47**: 1003-1010 [PMID: [26258846](#) DOI: [10.1038/ng.3375](#)]
 - 32 **Borad MJ**, Gores GJ, Roberts LR. Fibroblast growth factor receptor 2 fusions as a target for treating cholangiocarcinoma. *Curr Opin Gastroenterol* 2015; **31**: 264-268 [PMID: [25763789](#) DOI: [10.1097/MOG.0000000000000171](#)]
 - 33 **Mecklin JP**, Järvinen HJ, Virolainen M. The association between cholangiocarcinoma and hereditary nonpolyposis colorectal carcinoma. *Cancer* 1992; **69**: 1112-1114 [PMID: [1310886](#) DOI: [10.1002/cncr.2820690508](#)]
 - 34 **Kayhanian H**, Smyth EC, Braconi C. Emerging molecular targets and therapy for cholangiocarcinoma. *World J Gastrointest Oncol* 2017; **9**: 268-280 [PMID: [28808500](#) DOI: [10.4251/wjgo.v9.i7.268](#)]
 - 35 **Putra J**, de Abreu FB, Peterson JD, Pipas JM, Mody K, Amos CI, Tsongalis GJ, Suriawinata AA. Molecular profiling of intrahepatic and extrahepatic cholangiocarcinoma using next generation sequencing. *Exp Mol Pathol* 2015; **99**: 240-244 [PMID: [26189129](#) DOI: [10.1016/j.yexmp.2015.07.005](#)]
 - 36 **Borger DR**, Tanabe KK, Fan KC, Lopez HU, Fantin VR, Straley KS, Schenkein DP, Hezel AF, Ancukiewicz M, Liebman HM, Kwak EL, Clark JW, Ryan DP, Deshpande V, Dias-Santagata D, Ellisen LW, Zhu AX, Iafrate AJ. Frequent mutation of isocitrate dehydrogenase (IDH)1 and IDH2 in cholangiocarcinoma identified through broad-based tumor genotyping. *Oncologist* 2012; **17**: 72-79 [PMID: [22180306](#) DOI: [10.1634/theoncologist.2011-0386](#)]
 - 37 **Louis C**, Papoutsoglou P, Coulouarn C. Molecular classification of cholangiocarcinoma. *Curr Opin Gastroenterol* 2020; **36**: 57-62 [PMID: [31895230](#) DOI: [10.1097/MOG.0000000000000611](#)]
 - 38 **Feinberg AP**, Ohlsson R, Henikoff S. The epigenetic progenitor origin of human cancer. *Nat Rev Genet* 2006; **7**: 21-33 [PMID: [16369569](#) DOI: [10.1038/nrg1748](#)]
 - 39 **Goeppert B**, Konermann C, Schmidt CR, Bogatyrova O, Geiselhart L, Ernst C, Gu L, Becker N, Zucknick M, Mehrabi A, Hafezi M, Klauschen F, Stenzinger A, Warth A, Breuhahn K, Renner M, Weichert W, Schirmacher P, Plass C, Weichenhan D. Global alterations of DNA methylation in cholangiocarcinoma target the Wnt signaling pathway. *Hepatology* 2014; **59**: 544-554 [PMID: [24002901](#) DOI: [10.1002/hep.26721](#)]
 - 40 **Xiaofang L**, Kun T, Shaoping Y, Zaiqiu W, Hailong S. Correlation between promoter methylation of p14(ARF), TMS1/ASC, and DAPK, and p53 mutation with prognosis in cholangiocarcinoma. *World J Surg Oncol* 2012; **10**: 5 [PMID: [22230750](#) DOI: [10.1186/1477-7819-10-5](#)]
 - 41 **Selaru FM**, Olaru AV, Kan T, David S, Cheng Y, Mori Y, Yang J, Paun B, Jin Z, Agarwal R, Hamilton JP, Abraham J, Georgiades C, Alvarez H, Vivekanandan P, Yu W, Maitra A, Torbenson M, Thuluvath PJ, Gores GJ, LaRusso NF, Hruban R, Meltzer SJ. MicroRNA-21 is overexpressed in human cholangiocarcinoma and regulates programmed cell death 4 and tissue inhibitor of metalloproteinase 3. *Hepatology* 2009; **49**: 1595-1601 [PMID: [19296468](#) DOI: [10.1002/hep.22838](#)]
 - 42 **O'Rourke CJ**, Munoz-Garrido P, Aguayo EL, Andersen JB. Epigenome dysregulation in cholangiocarcinoma. *Biochim Biophys Acta Mol Basis Dis* 2018; **1864**: 1423-1434 [PMID: [28645654](#) DOI: [10.1016/j.bbdis.2017.06.014](#)]

- 43 **Salati M**, Braconi C. Noncoding RNA in Cholangiocarcinoma. *Semin Liver Dis* 2019; **39**: 13-25 [PMID: [30536290](#) DOI: [10.1055/s-0038-1676097](#)]
- 44 **Li J**, Huang L, Li Z, Zhong X, Tai S, Jiang X, Cui Y. Functions and roles of long noncoding RNA in cholangiocarcinoma. *J Cell Physiol* 2019; **234**: 17113-17126 [PMID: [30888066](#) DOI: [10.1002/jcp.28470](#)]
- 45 **Angenard G**, Merdrignac A, Louis C, Edeline J, Coulouarn C. Expression of long non-coding RNA ANRIL predicts a poor prognosis in intrahepatic cholangiocarcinoma. *Dig Liver Dis* 2019; **51**: 1337-1343 [PMID: [31040073](#) DOI: [10.1016/j.dld.2019.03.019](#)]
- 46 **Loilome W**, Bungkanjana P, Techasen A, Namwat N, Yongvanit P, Puapairoj A, Khuntikeo N, Riggins GJ. Activated macrophages promote Wnt/ β -catenin signaling in cholangiocarcinoma cells. *Tumour Biol* 2014; **35**: 5357-5367 [PMID: [24549785](#) DOI: [10.1007/s13277-014-1698-2](#)]
- 47 **Oishi N**, Kumar MR, Roessler S, Ji J, Forgues M, Budhu A, Zhao X, Andersen JB, Ye QH, Jia HL, Qin LX, Yamashita T, Woo HG, Kim YJ, Kaneko S, Tang ZY, Thorgeirsson SS, Wang XW. Transcriptomic profiling reveals hepatic stem-like gene signatures and interplay of miR-200c and epithelial-mesenchymal transition in intrahepatic cholangiocarcinoma. *Hepatology* 2012; **56**: 1792-1803 [PMID: [22707408](#) DOI: [10.1002/hep.25890](#)]



Published by **Baishideng Publishing Group Inc**
7041 Koll Center Parkway, Suite 160, Pleasanton, CA 94566, USA

Telephone: +1-925-3991568

E-mail: bpgoffice@wjgnet.com

Help Desk: <https://www.f6publishing.com/helpdesk>

<https://www.wjgnet.com>

