

A new optical coherence tomography method for subfoveal choroidal thickness measurement

A single-center observational study

Kyung Tae Kang, MD, PhD, Ji Hye Jang, MD, PhD, Yu Cheol Kim, MD, PhD*

Abstract

Several macular pathologies are associated with choroidal vascular supply and thus require choroidal thickness evaluation. However, there is no standard subfoveal choroidal thickness (SFCT) measurement method. This study investigated a new method of SFCT measurement, using optical coherence tomography.

This is a single-center observational study. Eighty-two senior medical students participated as observers and independently measured the SFCT on 5 standard optical coherence tomography images of healthy adults in a tertiary care setting. They used 3 different methods: the observer's own method, the conventional method, perpendicular to the retinal pigment epithelium, and the new method, along a virtual line connecting the umbo with the most elevated point of the ellipsoid. Additionally, the SFCT angle—the angle between the measurement line and the vertical line of the image—was measured and compared between methods. The intraclass correlation coefficient was used to determine interpersonal variability.

The intraclass correlation coefficients for SFCT, measured using methods 1, 2, and 3, were 0.853, 0.880, and 0.896, respectively ($P < .001$ for all). Method 3 was the highest. The intraclass correlation coefficients of the SFCT angles were 0.647, 0.842, and 0.307, respectively ($P < .001$ for all).

The new method showed the lowest interpersonal variability and could therefore be a reliable standard for SFCT measurement, even in foveae with a steep slope on optical coherence tomography.

Trial registration: Not applicable.

Abbreviations: EDI-OCT = enhanced depth imaging spectral-domain optical coherence tomography, ICC = intraclass correlation coefficient, OCT = optical coherence tomography, RPE = retinal pigment epithelium, SE = spherical equivalent, SFCT = subfoveal choroidal thickness, SS-OCT = swept-source OCT.

Keywords: choroid, fovea, optical coherence tomography, retina

Editor: Michele Figus.

This research was supported by the National Research Foundation of Korea grant (NRF-2019R1G1A1011559). The sponsor had no role in the design or conduct of this research.

Posted history: This manuscript was previously posted to <https://doi.org/10.21203/rs.3.rs-87168/v1>.

Ethical approval and consent to participate: The institutional review board of Keimyung University approved this study. All study procedures adhered to the tenets of the Declaration of Helsinki. Informed consent was obtained from all study participants and observers.

Consent for publication: Written informed consent for publication of clinical details and/or clinical images was obtained from the participants.

Availability of data and materials: The dataset used and/or analyzed during the current study are available from the corresponding author on reasonable request. There are no confidential data or any restrictions on accessing the original data.

Competing interests: KTK has no competing interests. JHJ reports personal fees from Bayer and Novartis unrelated to the submitted work. YCK reports personal fees from Bayer, Novartis, and Allergan, all unrelated to the submitted work.

The authors have no conflicts of interest to disclose.

The datasets generated during and/or analyzed during the current study are available from the corresponding author on reasonable request.

Department of Ophthalmology, Keimyung University School of Medicine, Keimyung University Dongsan Hospital, Daegu, Republic of Korea.

* Correspondence: Yu Cheol Kim, Department of Ophthalmology, Keimyung University School of Medicine, Keimyung University Dongsan Hospital, 1035 Dalgubeol-daero, Dalseo-gu, Daegu, 42601, Republic of Korea (e-mail: eyedr@dsmc.or.kr).

Copyright © 2021 the Author(s). Published by Wolters Kluwer Health, Inc.

This is an open access article distributed under the terms of the Creative Commons Attribution-Non Commercial License 4.0 (CCBY-NC), where it is permissible to download, share, remix, transform, and buildup the work provided it is properly cited. The work cannot be used commercially without permission from the journal.

How to cite this article: Kang KT, Jang JH, Kim YC. A new optical coherence tomography method for subfoveal choroidal thickness measurement: a single-center observational study. *Medicine* 2021;100:24(e26355).

Received: 29 January 2021 / Received in final form: 26 May 2021 / Accepted: 29 May 2021

<http://dx.doi.org/10.1097/MD.00000000000026355>

1. Introduction

The choroid is a vascular layer between the retina and sclera. It provides blood supply to most ocular tissues, including the outer retinal structures.^[1] Choroidal abnormalities, including its loss, thinning, and hyperpermeability, are implicated in various retinal and macular pathologies, such as central serous chorioretinopathy, Vogt-Koyanagi-Harada disease, neovascular age-related macular degeneration, polypoidal choroidal vasculopathy, and diabetic retinopathy.^[2–6] Choroidal thickness is a commonly studied parameter,^[7] along with other choroidal biomarkers such as choroidal volume, choroidal vessel layer thickness, and the choroidal vascularity index. Choroidal thickness is conventionally measured on optical coherence tomography (OCT) from the hyperreflective posterior edge of the retinal pigment epithelium (RPE) to the choroidoscleral interface where the reflectivity changes.^[8]

Subfoveal choroidal thickness (SFCT), most frequently used to calculate choroidal thickness, can vary widely from 191.5 to 354 μm .^[8–11] Such variations could be attributed to the software programs used in the OCT systems to map the choroidal thicknesses^[8] and a lack of standardization in the measurement techniques. For example, Chhablani et al^[12] measured the choroidal thickness perpendicularly to the RPE layer, while Ikuno et al^[9] calculated the choroidal thickness, using the vertical distance starting from the RPE layer, on the OCT images. These limitations preclude the ability to define the normal cutoff value in participants without any ocular abnormalities. Hence, there is a need for a standardized choroidal thickness measurement technique to establish the baseline, allow comparisons, and enhance the understanding of disease mechanisms. This study aimed to evaluate a new method of SFCT measurement, using a swept-source OCT (SS-OCT), and compare the interpersonal variability among different methods.

2. Methods

Senior medical students ($n=82$) at the Keimyung University Medical School volunteered for this non-interventional study during their ophthalmology rotation between January and August 2019. During their attendance, the students were

introduced to ophthalmic examination devices, including the OCT system. They reviewed the OCT images of healthy participants and those with various ophthalmic pathologies with the attending professors (KTK and JHJ). Following the introduction and OCT, the students were asked to measure the SFCT on OCT images of 5 pre-selected standard participants, using the 3 methods described below. We have obtained written informed consent from all students before starting the measurements.

2.1. Standard participants

For the standard images, 5 eyes of 5 preselected healthy participants with no proven ophthalmic or systemic ailments were examined with a SS-OCT (DRI TRITON, Topcon Corp., Tokyo, Japan). All participants underwent a complete ocular examination, including refraction, slit-lamp biomicroscopy, intraocular pressure, and funduscopy, to exclude ophthalmic abnormalities. The participants included a 60-year-old man with a spherical equivalent (SE) of +1 diopter as image 1 (Fig. 1A), a 67-year-old man with an SE of +2 diopter as image 2 (Fig. 1B), a 46-year-old man with an SE of -3.25 diopter as image 3 (Fig. 1C), a 43-year-old woman with an SE of -0.375 diopter as image 4 (Fig. 1D), and a 58-year-old man with an SE of -11 diopter as image 5 (Fig. 1E). These images were chosen as standards because the OCT quality was better than 86/100 as defined by the OCT software. We obtained informed consent from all participants. The institutional review board of Keimyung University approved the study procedures (IRB: 2019–12–056), which adhered to the tenets of the Declaration of Helsinki.

2.2. SS-OCT and scan protocols

After pupillary dilation, 64 to 128 averaged horizontal scan images in a 12-mm transverse scan range were obtained with the SS-OCT system for each standard image. The single images were averaged by the system software to improve the image quality. The wavelength-swept laser light source was centered at 1050 nm. The transverse resolution of the OCT was 20 μm , the in-depth, in-tissue resolution was 8 μm , and the maximum scan velocity was 100,000 A-scans per second.

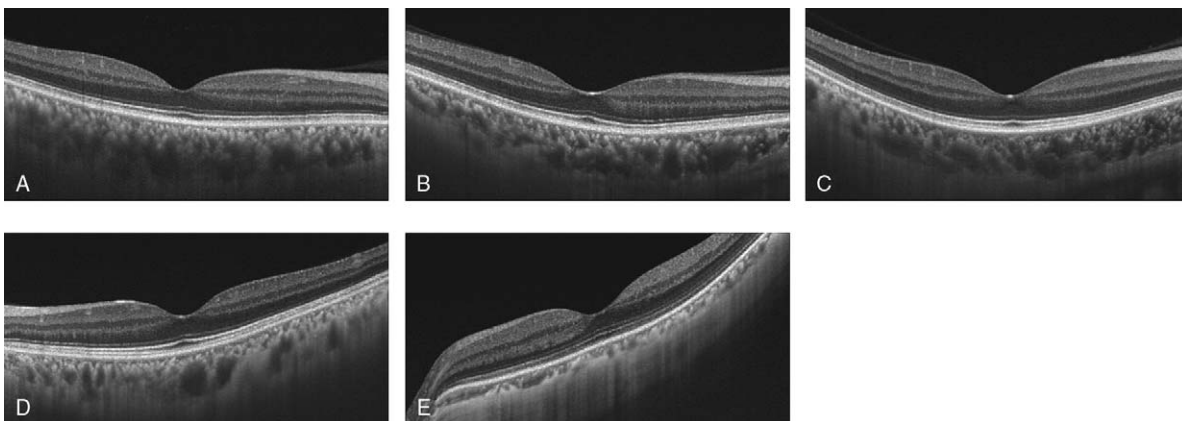


Figure 1. Standard multi-averaged horizontal swept-source optical coherence tomography images. The 12-mm transverse scan range images of 5 preselected standard healthy participants are presented (A–E). Each image was obtained by averaging 64 to 128 single optical coherence tomography images to improve the quality.

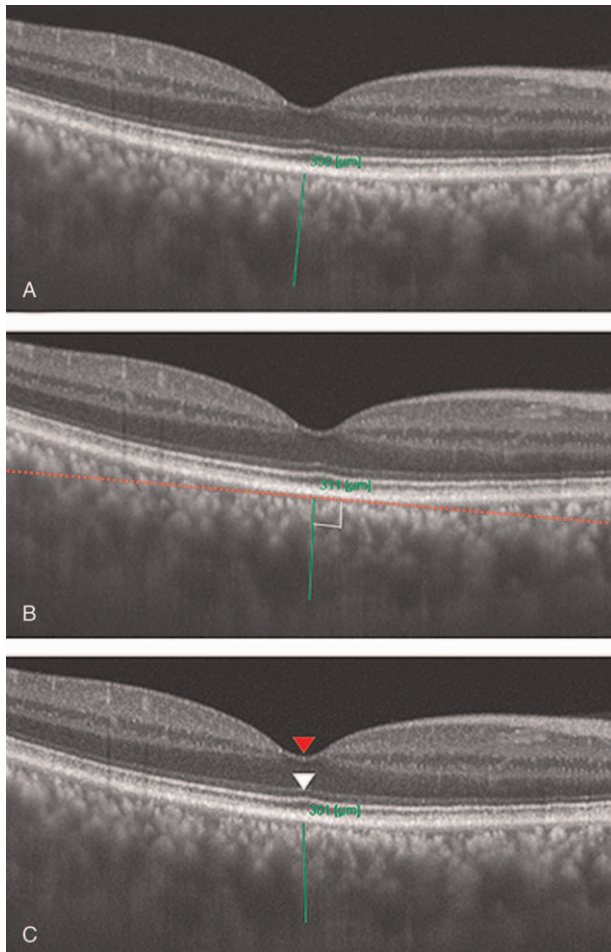


Figure 2. Three methods of subfoveal chorioidal thickness measurement using a representative image. (A) Method 1, the measurement (green line) between retinal pigment epithelium and the choroidoscleral interface was done by the observer's own method. (B) Method 2, the measurement (green line) was done perpendicular to the retinal pigment epithelium (red dots). (C) Method 3, the measurement (green line) was done along a virtual line connecting the deepest point of the fovea (the umbo, red arrowhead) and the most elevated point of the ellipsoid zone (the elevation, white arrowhead).

2.3. Chorioidal thickness measurement

SFCT was defined as the distance between the outer border of the hyperreflective line representing the RPE and the choroidoscleral interface. The automated built-in calibration software of the IMAGEnet 6 viewer (Topcon, Tokyo, Japan) was used to determine the distance between these lines. The students were asked to measure the SFCT with the caliper tool embedded in the viewer program. Measurements were performed in 3 different ways. In method 1, to see an intuitive measurement method, students who were not yet exposed to the other known methods were asked to measure the SFCT using their own methods without receiving any specific instructions from the authors (Fig. 2A). For method 2, the conventional method, commonly used in previous studies, was followed. The students were asked to measure the SFCT perpendicular to the RPE (Fig. 2B). Finally, the new method, or method 3, measured SFCT along a virtual line connecting the deepest point of the fovea (the umbo) and the most elevated point of the ellipsoid zone (the elevation) (Fig. 2c). With

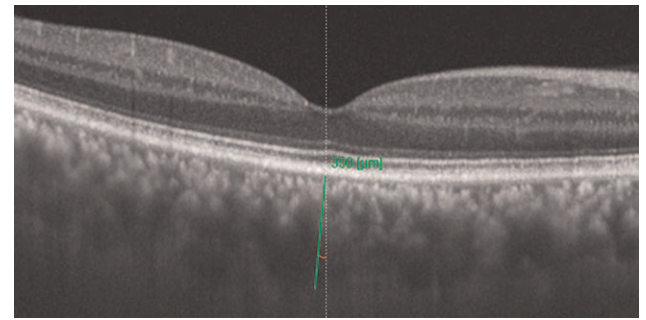


Figure 3. Angle measurement: measurement of the angle (red marking) between the vertical line (white dashed line) on the image and the subfoveal chorioidal thickness measurement line (green line).

the extension of this virtual line towards the choroid and sclera, the SFCT was measured as the distance between the RPE and the choroidoscleral interface. The students were provided a separate room and enough time to perform the SFCT measurements. For inter-image and inter-method comparisons, the angle between the SFCT measurement line and the vertical line on the OCT image was calculated using ImageJ ver. 1.50i (National Institutes of Health, Bethesda, MD) (Fig. 3).

2.4. Interpersonal variability and statistical analyses

We obtained SFCTs, measured by the 82 independent observers, using 3 methods in 5 standard OCT images. The interpersonal variability among the 3 SFCT measurement methods was assessed using the intraclass correlation coefficient (ICC). Statistical analysis was performed using the Statistical Package for the Social Sciences version 19.0.1 (IBM Corp., Armonk, NY). Statistical significance was defined as $P < .05$.

3. Results

The ICC for the SFCT measurements, using the 3 methods, was 0.853, 0.880, and 0.896 for methods 1, 2, and 3, respectively ($P < .001$ for all). The interpersonal variability for the SFCT measurements was the lowest with method 3 (Table 1), indicating a high similarity (ICC) between the SFCT values in this group. The angle between the vertical line on the OCT images and the measurement line, termed the SFCT angle, was also compared within each method. The ICC for the SFCT angle was 0.647, 0.842, and 0.307 for methods 1, 2, and 3, respectively ($P < .001$ for all). Method 2 had the highest similarity in the ICC for the SFCT angle (Table 1).

The standard deviation of the SFCT was compared between the methods for each standard OCT image. The standard deviation was the smallest in all standard images when method 3 was used, while the results of methods 1 and 2 varied between standard images (Table 2).

4. Discussion

Noninvasive imaging is widely used to evaluate inaccessible chorioidal structures as the RPE light-scattering tendency limits clear choroid visualization.^[13] Recent advances in imaging technology, such as enhanced depth imaging spectral-domain optical coherence tomography (EDI-OCT), allow in vivo

Table 1
Intraclass correlation coefficient of subfoveal choroidal thickness measured by 82 observers using optical coherence tomography.

	Method 1 [*]		Method 2 [†]		Method 3 [‡]	
	ICC	P-value	ICC	P-value	ICC	P-value
Subfoveal choroidal thickness, μm	0.853	<.001	0.880	<.001	0.896	<.001
Angle between the vertical line and measurement line, $^{\circ}$	0.647	<.001	0.842	<.001	0.307	<.001

ICC = intraclass correlation coefficient.

^{*} Observers' own methods.

[†] Perpendicular to the retinal pigment epithelium.

[‡] The virtual line connecting the deepest point of the fovea and the most elevated point of the ellipsoid zone.

assessment of the choroidal layers.^[8,12,13] EDI, introduced by Spaide et al,^[13] is obtained by shifting the zero-delay line toward the choroid, leading to improved image resolution and better delineation of the choroidal structures. Many studies analyzing the choroidal thickness used manual measurements that lack standardization.^[7-9,13] Moreover, manual segmentation is time-consuming and is prone to intra- and interobserver variations. Automated segmentation with various machine learning and gradient-based probabilistic methods was developed to overcome this limitation.^[14-16] However, these attempts do not directly show the structural dissimilarity between the choroid and the sclera.^[7] Therefore, the current study examined a new method to manually measure the SFCT with lower interobserver variability than the conventional method.

The authors suggest measuring the SFCT along the virtual line connecting the foveal umbo and the elevation as it represents the central anatomical point of the fovea. In this study, the measurement of the SFCT along this virtual line had the least interpersonal variability among the 3 evaluated methods. The new method presented the least interobserver variability regardless of the standard image used, as indicated by its standard deviation, which was the smallest for all images. Methods 1 and 2, on the other hand, presented inconsistent results when assessing the different standard images, as manifested by larger standard deviations.

The mean SFCT in standard images 1, 2, and 3 presented no evident differences between the 3 measurement methods, but differences were apparent when images 4 and 5 were measured. The SFCT was shorter when measured using method 3. The fovea had a steep slope in these images, while it was gradual in images 1, 2, and 3. When the fovea has a steep slope, SFCT measurement perpendicular to the RPE can be difficult and might result in overestimating the distance because the slope makes the measurement line longer than the actual distance. Since method 3 presented the least interobserver variability, even in the images

with a steep slope, it can be safely assumed to be more reliable than the other 2 methods.

Another interesting observation was the high interobserver variability in the SFCT angle when measurements were done by the new method. We suspected that the high variability was because the definition of "the deepest point of the fovea" and "the most elevated point of the ellipsoid zone" can be ambiguous to the observers. Method 2 had the most consistent results regarding the SFCT angle because it had a defined angle for SFCT measurement on the images. The SFCT was measured after the observers were introduced to the OCT scans and the structure of the eye as reconstructed on the OCT images. When measuring the SFCT by their own method (method 1), the observers had no information regarding the conventional measurement method. About one-third of them intuitively measured the SFCT perpendicular to the RPE. This could explain why the angle measured using method 1 was less variable than that measured using method 3. However, since the SFCT measurement by method 3 showed the least variability, the influence of the angle on the actual SFCT measurement could be considered insignificant.

The authors acknowledge that there can be methods by which the choroidal thickness can be measured automatically, and it can represent the choroidal thickness more precisely. The mean choroidal thickness in this study was auto-segmented and averaged by the OCT system's viewer program in a 1-mm circular area around the foveal center.^[8] The authors, however, noticed that the automatic segmentation program failed to delineate the choroidoscleral border between the inner and outer boundaries and to present a valid value for standard images 4 and 5, so the process could not be completed automatically. Until further advanced algorithms could accurately and reproducibly measure the SFCT in every case, the authors insist that manual SFCT segmentation is required when analyzing OCT images, which has been stated in the previous researches.^[14-16]

Table 2
Method-based mean subfoveal choroidal thickness measured from optical coherence tomography by 82 observers.

SFCT measurement method	Image 1		Image 2		Image 3		Image 4		Image 5	
	Mean	SD	Mean	SD	Mean	SD	Mean	SD	Mean	SD
Method 1 [*]	349.25	27.812	273.86	32.324	253.78	21.432	290.53	32.026	121.11	54.049
Method 2 [†]	351.73	27.637	278.14	26.092	250.77	30.217	299.00	27.622	124.44	42.759
Method 3 [‡]	339.44	25.144	258.30	24.071	253.52	20.605	268.52	25.635	104.16	42.271

SD = standard deviation, SFCT = subfoveal choroidal thickness.

^{*} Observers' own methods.

[†] Perpendicular to the retinal pigment epithelium.

[‡] The virtual line connecting the deepest point of the fovea and the most elevated point of the ellipsoid zone.

The selection of the medical students as observers was due to the following reasons: the observers had to have sufficient knowledge of the structure of the retina and choroid, but not well informed enough to know the conventional way to measure it; and that they could be relatively homogenous in terms of the level of intelligence, leading to more reliable results.

This study has several limitations: small number of standard images; lack of standard images with chorioretinal pathology; sequential analysis from method 1 to method 3, which could influence the results because the observers became increasingly familiar with the viewer program; and since the proposed method is designed to use the foveal umbo as the deepest point of the fovea, and ellipsoid zone elevation as the guide measuring the SFCT, in the eye with pathologic conditions where inner retinal structures are indistinguishable such as in epiretinal membrane, macular edema, or ellipsoid zone disruption presents such as in central serous chorioretinopathy, it should have difficulty to perform the proposed method. However, even in eyes with such pathologies, we believe the new SFCT measurement method could guide the development of better measurement methods in cases with a relatively well-preserved ellipsoid zone.

Further studies are warranted to assess the new method's interobserver variability in patients with various chorioretinal pathologies. Regardless, the strengths of the present study include the large number and relative uniformity of the observers, the presence of standard images, and the measurement independence among observers. We considered senior medical students to be well educated to understand the structure of the eye and its appearance on the OCT images to provide reliable SFCT measurements, yet unfamiliar, professionally, with the conventional methods to bias the results. They worked independently to prevent mutual influence during the measurement.

5. Conclusions

Measuring the SFCT by the proposed novel method, along the line connecting the deepest foveal point (the umbo) and the most elevated point of the ellipsoid zone (elevation), shows lower interpersonal variability than the conventional method, even when the fovea has a steep slope on the OCT image, as is the case in myopic eyes. Therefore, the proposed novel method measures SFCT more reliably than the conventional method.

Acknowledgments

The authors would like to express their special gratitude to the senior medical students of the Keimyung University Medical School who volunteered to participate in this study.

Author contributions

Conceptualization: Yu Cheol Kim.

Data curation: Kyung Tae Kang, Ji Hye Jang.

Formal analysis: Kyung Tae Kang.

Funding acquisition: Yu Cheol Kim.

Investigation: Kyung Tae Kang, Ji Hye Jang, Yu Cheol Kim.

Methodology: Yu Cheol Kim.

Project administration: Yu Cheol Kim.

Resources: Kyung Tae Kang, Ji Hye Jang, Yu Cheol Kim.

Software: Kyung Tae Kang, Ji Hye Jang, Yu Cheol Kim.

Supervision: Yu Cheol Kim.

Validation: Kyung Tae Kang, Ji Hye Jang, Yu Cheol Kim.

Visualization: Kyung Tae Kang, Ji Hye Jang, Yu Cheol Kim.

Writing – original draft: Kyung Tae Kang.

Writing – review & editing: Kyung Tae Kang, Ji Hye Jang, Yu Cheol Kim.

References

- [1] Linsenmeier RA, Padnick-Silver L. Metabolic dependence of photoreceptors on the choroid in the normal and detached retina. *Invest Ophthalmol Vis Sci* 2000;41:3117–23.
- [2] Ross A, Ross AH, Mohamed Q. Review and update of central serous chorioretinopathy. *Curr Opin Ophthalmol* 2011;22:166–73.
- [3] Read RW, Rao NA, Cunningham ET. Vogt-Koyanagi-Harada disease. *Curr Opin Ophthalmol* 2000;11:437–42.
- [4] Chung SE, Kang SW, Lee JH, Kim YT. Choroidal thickness in polypoidal choroidal vasculopathy and exudative age-related macular degeneration. *Ophthalmology* 2011;118:840–5.
- [5] Yannuzzi LA, Sorenson J, Spaide RF, Lipson B. Idiopathic polypoidal choroidal vasculopathy (IPCV). *Retina* 2012;32:1–8.
- [6] Adhi M, Brewer E, Waheed NK, Duker JS. Analysis of morphological features and vascular layers of choroid in diabetic retinopathy using spectral-domain optical coherence tomography. *JAMA Ophthalmol* 2013;131:1267–74.
- [7] Singh SR, Vupparaboina KK, Goud A, Dansingani KK, Chhablani J. Choroidal imaging biomarkers. *Surv Ophthalmol* 2019;64:312–33.
- [8] Hirata M, Tsujikawa A, Matsumoto A, et al. Macular choroidal thickness and volume in normal subjects measured by swept-source optical coherence tomography. *Invest Ophthalmol Vis Sci* 2011;52:4971–8.
- [9] Ikuno Y, Kawaguchi K, Nouchi T, Yasuno Y. Choroidal thickness in healthy Japanese subjects. *Invest Ophthalmol Vis Sci* 2010;51:2173–6.
- [10] Manjunath V, Taha M, Fujimoto JG, Duker JS. Choroidal thickness in normal eyes measured using Cirrus HD optical coherence tomography. *Am J Ophthalmol* 2010;150:325.E1–9.E1.
- [11] Margolis R, Spaide RF. A pilot study of enhanced depth imaging optical coherence tomography of the choroid in normal eyes. *Am J Ophthalmol* 2009;147:811–5.
- [12] Chhablani J, Srinivasa PR, Venkata A, et al. Choroidal thickness profile in healthy Indian subjects. *Indian J Ophthalmol* 2014;62:1060–3.
- [13] Spaide RF, Koizumi H, Pozzoni MC. Enhanced depth imaging spectral-domain optical coherence tomography. *Am J Ophthalmol* 2008;146:496–500.
- [14] Danesh H, Kafieh R, Rabbani H, Hajizadeh F. Segmentation of choroidal boundary in enhanced depth imaging OCTs using a multiresolution texture based modeling in graph cuts. *Comput Math Methods Med* 2014;2014:1–9.
- [15] Alonso-Caneiro D, Read SA, Collins MJ. Automatic segmentation of choroidal thickness in optical coherence tomography. *Biomed Opt Express* 2013;4:2795–812.
- [16] Kajić V, Esmacelpour M, Považay B, Marshall D, Rosin PR, Drexler W. Automated choroidal segmentation of 1060nm OCT in healthy and pathologic eyes using a statistical model. *Biomed Opt Express* 2012;3:86–103.