

Research Article

The value of magnetic resonance imaging and ultrasonography (MRI/US)-fusion biopsy in clinically significant prostate cancer detection in patients with biopsy-naïve men according to PSA levels: A propensity score matching analysis

Hye J. Byun ^a, Teak J. Shin ^a, Wonho Jung ^a, Ji Y. Ha ^a, Byung H. Kim ^{a,*}, Young H. Kim ^b

^a Department of Urology, Keimyung University School of Medicine, Dongsan Hospital, Daegu, South Korea

^b Department of Radiology, Keimyung University School of Medicine, Dongsan Hospital, Daegu, South Korea

ARTICLE INFO

Article history:

Received 21 July 2021

Received in revised form

3 October 2021

Accepted 26 October 2021

Available online 4 November 2021

Keywords:

Magnetic resonance imaging

Prostate cancer

Prostate-specific antigen

ABSTRACT

Objectives: To evaluate the detection rate of clinically significant prostate cancer (csPCa) in Magnetic resonance imaging and ultrasonography (MRI/US) fusion biopsy in patients with biopsy-naïve men for varying prostate-specific antigen (PSA) levels. Since MRI can efficiently detect csPCa compared to standard transrectal ultrasound (TRUS) guided biopsy; however, the optimal PSA threshold for its use is unclear.

Materials and methods: We retrospectively reviewed those who underwent MRI/US-fusion and standard biopsy from January 2016 to June 2018. Patients were divided into three groups: PSA <4, 4–10, >10 ng/mL. Propensity scoring was performed to balance the characteristics of the different biopsy groups, and the detection rate of csPCa was compared.

Results: Data from a total of 670 males were included in the analysis (standard TRUS, $n = 333$; MRI/US fusion, $n = 337$). Prior to matching, patients who received MRI/US-fusion biopsy had lower prostate volume. Propensity score matching balanced this characteristic and generated a cohort comprising 195 patients from each group. In the matched cohort, patients with PSA 4–10 ng/mL had a significantly increased risk of csPCa by MRI/US-fusion vs. standard biopsy (35.0% vs. 26.6%, $P = 0.033$). However, patients with PSA <4 ng/mL had csPCa found by MRI/US-fusion versus standard biopsy (12.0% vs. 16.0%, $P = 0.342$), whereas, patients with PSA >10 ng/mL had csPCa found by MRI/US-fusion versus standard biopsy (78.0% vs. 80.0%, $P = 0.596$). In multivariate logistic analysis among patients with PSA 4–10 ng/mL, MRI/US-fusion biopsy (odds ratio: 2.46, 95% confidence interval = 1.31–4.60, $P = 0.005$) were significantly associated with a detection of csPCa.

Conclusions: Detection of csPCa by MRI/US-fusion biopsy is more efficient in patients with biopsy-naïve men with PSA 4–10 ng/mL. However, standard TRUS biopsy may identify csPCa in patients with PSA <4 ng/mL and ≥ 10 ng/mL, emphasizing the importance of performing a standard biopsy in conjunction with MRI/US-fusion biopsy in such populations.

© 2022 Asian Pacific Prostate Society. Publishing services by Elsevier B.V. This is an open access article under the CC BY-NC-ND license (<http://creativecommons.org/licenses/by-nc-nd/4.0/>).

1. Introduction

Prostate cancer (Pca) is the second most common cancer in men worldwide [1]. Population-based screening programs such as prostate-specific antigen (PSA) test, digital rectal examination are

being increasingly adopted worldwide for prostate cancer detection. Patients that are positive for such risk factors undergo routine transrectal ultrasound (TRUS)-guided systematic biopsy, which is the current diagnostic standard for Pca. However, systematic biopsies suffer from poor sensitivity with nearly 75% of males, with PSA in the gray zone of 4–10 ng/mL, undergoing an unnecessary biopsy, resulting in increased patient morbidity [2].

Multiparametric magnetic resonance imaging (MRI) of the prostate has significantly improved the diagnostic accuracy of clinically significant prostate cancer (csPCa) by MRI-guided

* Corresponding author. Department of Urology, Keimyung University School of Medicine, Dongsan hospital, 1035 Dalgubeoldae-ro, Dalseo-gu, Daegu, 42601, South Korea.

E-mail address: blackporori@gmail.com (B.H. Kim).

targeted biopsies [3–6]. However, multiparametric MRI (mpMRI) is expensive and not commonly used in a clinical setting. Instead, a simplified biparametric MRI (bpMRI) protocol, comprising of only T2-weighted and diffusion-weighted imaging, has been proposed for the diagnosis of csPCa, [7, 8].

Therefore, we conducted MRI/US-fusion biopsy in patients with biopsy-naïve men with elevated PSA levels and compared the results of standard TRUS biopsy (TRUSbx), and we further compared the detection rate of csPCa in males with PSA in the gray zone in order to minimize overdiagnosis and unnecessary treatment.

2. materials and Methods

2.1. Study Subjects

We retrospectively reviewed the medical records of a total of 670 males that underwent either MRI/US-fusion ($n = 337$) biopsy or standard TRUSbx ($n = 333$) at the Keimyung University Dongsan Medical Center, from January 2016 to June 2018 (Fig. 1). The Institutional Review Board approved this study (DSMC 2020-11-033). We compared the following clinical variables: age (years), PSA (ng/mL), prostate volume (PV) (cc), Gleason score (GS, the greatest grade), clinical T stage, and lymph node metastasis and distant metastasis. All histopathological biopsies were reported (core length, cancer length, and GS) by a pathologist with at least 10 years of experience in genitourinary pathology. We defined csPCa with a GS 3 + 4 or greater [9]. The patients were then divided into three groups as follows; PSA <4 ng/mL, 4–10 ng/mL, and >10 ng/mL.

2.2. MRI protocol

The bpMRI examination was performed using a 3.0-T scanner with a 32-channel phased-array coil (Ingenia 3T CX Quasar Dual; Philips, The Netherlands). The Prostate Imaging Reporting and Data System version 2.1 (PI-RADSv2.1) scores were assigned by a radiologist (with at least 3 years of prostate MRI experience) on a scale from 1 to 5 [10]. In a case of a suspicious lesion on MRI (PI-RADS 3–5), a targeted biopsy (TBx) was conducted (from one to three cores) using the MRI-TRUS fusion software-assisted system

(BioJET®, D&K Technologies, Barum, Germany) followed by six plus six systemic biopsy (SBx) cores [11]. All biopsies were performed by an experienced radiologist through a transrectal route with an enema and prophylactic antibiotics.

2.3. Statistical Analysis

The propensity score matching was performed to adjust for significant imbalances in baseline characteristics between two biopsy methods. This approach can be applied to minimize selection bias in observational data [12]. Categorical variables were compared between the groups using the chi-square, Fisher's exact test, or linear-by-linear association, where appropriate. One-way analysis of variance or Student's t-test was used for continuous variables. Binary logistic regression was used to estimate the odds of csPCa among males with PSA 4–10 ng/mL. The probability of csPCa was modeled by the stepwise regression of the following four predetermined potential risk factors. The 95% profile likelihood ratio confidence intervals (95% CIs) were calculated for the adjusted odds ratios (ORs). All statistical analyses were performed using SPSS version 25.0 software (IBM, Armonk, NY, USA). *P*-values less than 0.05 were considered to be statistically significant.

3. Results

3.1. Subjects Characteristics

A total of 670 males were included in the analysis (MRI/US fusion, $n = 337$; standard TRUS, $n = 333$) (Fig. 1). Among them, 348 (51.9%) were diagnosed with PCa, and 258 (38.5%) were diagnosed with csPCa. Details of descriptive statistics for the entire cohort ($n = 670$), as well as the propensity score-matched cohort ($n = 390$), are summarized in Table 1. In the entire cohort, there was a significant imbalance in prostate volume between the two groups. Mean PV in the standard TRUSbx group was higher than that of the MRI/US-fusion biopsy group (50.2 vs. 45.0; $P = 0.002$). Propensity score matching resulted in a cohort of 195 patients in each group. In the matched cohorts, there were no between-group differences with respect to patient baseline characteristics.

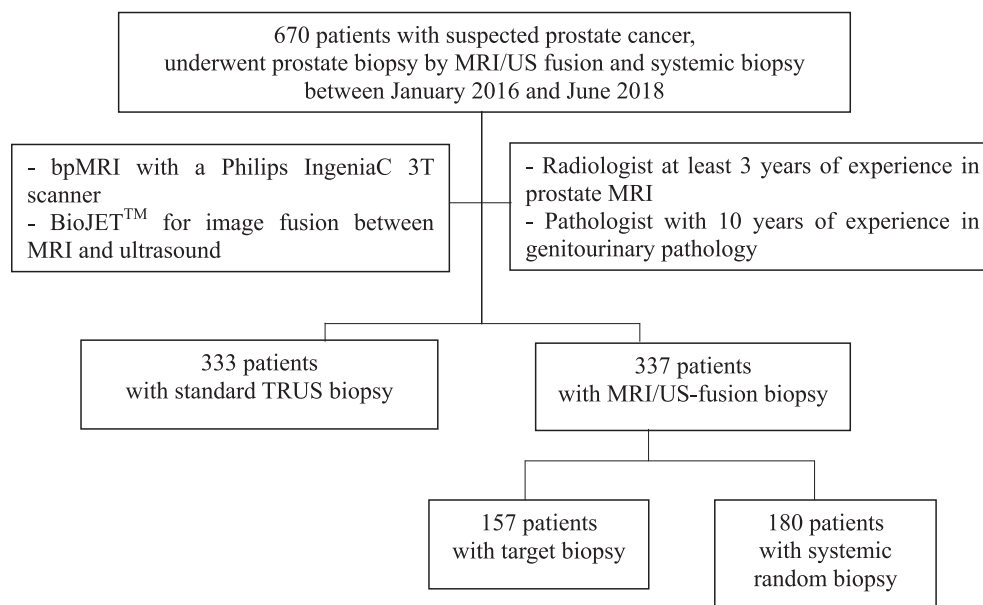


Fig. 1. Flowchart of inclusion criteria of the final patient cohort.

Table 1
Characteristics of the patients, stratified by the method of biopsy

Characteristics	Entire cohort			Propensity score-matched cohort		
	Standard TRUS (n = 333)	MRI-fusion (n = 337)	P-value	Standard TRUS (n = 195)	MRI-fusion (n = 195)	P-value
Mean age, yr (SD)	68.5 (8.3)	67.9 (8.9)	0.339	68.2 (8.6)	68.1 (8.5)	0.899
Mean PSA, ng/mL (SD)	45.1 (31.5)	35.6 (15.0)	0.619	40.3 (24.6)	40.2 (20.7)	0.990
Mean PV, cc (SD)	50.2 (23.7)	45.0 (19.3)	0.002	47.6 (21.7)	47.5 (17.3)	0.946
Mean total biopsy core, n	12.3 (1.4)	13.0 (2.1)	<0.001	12.3 (1.3)	12.7 (1.6)	0.502
PCa diagnosis, n (%)	184 (55.3)	164 (48.7)	0.088	112 (57.4)	103 (52.8)	0.089
Gleason score, n (%)			0.744			0.642
6	60 (18.0)	30 (8.9)		41 (21.0)	28 (14.3)	
7	47 (14.1)	53 (15.7)		38 (19.4)	39 (20.0)	
8-10	77 (23.1)	81 (24.0)		33 (16.9)	36 (18.4)	
Clinical T stage, n (%)			0.340			0.678
T1	51 (15.3)	32 (9.5)		25 (12.8)	20 (10.2)	
T2	91 (27.3)	94 (27.9)		57 (29.2)	58 (29.7)	
T3 – T4	42 (12.6)	38 (11.3)		30 (15.3)	25 (12.8)	
Lymph node metastases, n (%)	19 (5.7)	25 (7.4)	0.371	10 (5.1)	15 (7.6)	0.240
Distant metastases, n (%)	21 (6.3)	20 (5.9)	0.841	5 (2.5)	6 (3.0)	0.657
csPCa, n (%)	124 (37.2)	134 (39.8)	0.502	76 (38.9)	84 (43.0)	0.163

PSA, prostate-specific antigen; PV, prostate volume; TRUS, transrectal ultrasound; MRI, magnetic resonance image; PCa, prostate cancer; csPCa, clinically significant prostate cancer.

Table 2
The detection rate of total PCa and csPCa according to PSA thresholds, stratified by the method of biopsy

	Entire cohort			Propensity score-matched cohort		
	Standard TRUS (n = 333)	MRI-fusion (n = 337)	P-value	Standard TRUS (n = 195)	MRI-fusion (n = 195)	P-value
csPCa, n (%)	124 (37.2)	134 (39.8)	0.502	76 (38.9)	84 (43.0)	0.163
PSA <4 ng/mL (n, %)						
Total PCa	20/54 (37.0)	15/54 (27.8)	0.304	11/25 (44.0)	9/25 (36.0)	0.089
csPCa	9/54 (16.7)	6/54 (11.1)	0.404	4/25 (16.0)	3/25 (12.0)	0.342
PSA 4 – 10 ng/mL (n, %)						
Total PCa	89/194 (45.9)	83/196 (42.3)	0.483	58/120 (48.3)	53/120 (44.1)	0.396
csPCa	45/194 (23.2)	63/196 (32.1)	0.048	32/120 (26.6)	42/120 (35.0)	0.033
PSA >10 ng/mL (n, %)						
Total PCa	75/85 (88.2)	66/87 (75.9)	0.035	43/50 (86.0)	41/50 (82.0)	0.156
csPCa	70/85 (82.4)	65/87 (74.7)	0.223	40/50 (80.0)	39/50 (78.0)	0.596

PSA, prostate-specific antigen; TRUS, transrectal ultrasound; MRI, magnetic resonance image; PCa, prostate cancer; csPCa, clinically significant prostate cancer.

3.2. Detection of csPCa Among Patients with PSA level

Table 2 shows the detection rate of PCa and csPCa in the entire and matched cohort. The overall detection rate of csPCa of MRI/US-fusion versus standard TRUSbx groups was no significantly different in the unmatched (39.8% vs. 37.2%, $P = 0.502$) and matched cohort (43.0% vs. 38.9%, $P = 0.163$). In the matched cohort, in males with PSA 4–10 ng/mL, the detection rate of csPCa in the MRI/US-fusion biopsy was higher compared to the standard biopsy group (35.0% vs. 26.6%, $P = 0.033$). The detection rate of csPCa in the standard biopsy group was not statistically different compared to the MRI/US-fusion group in males with PSA <4 ng/mL (12.0% vs. 16.0%, $P = 0.342$) and in males with PSA >10 ng/mL (78.0% vs. 80.0%, $P = 0.596$) (Fig. 2).

Table 3 summarizes the results of univariate and multivariate analysis for the csPCa in males with PSA 4–10 ng/mL. In a multivariate analysis, older age (OR = 1.10, 95% CI = 1.06–1.15, $P < 0.001$), smaller PV (OR = 0.96, 95% CI = 0.93–0.98, $P < 0.001$), and MRI/US-fusion biopsy (OR = 2.46, 95% CI = 1.31–4.60, $P = 0.005$) were significantly associated with csPCa.

3.3. Presence of Suspicious Lesions on bpMRI

Subgroup analyses were performed to identify the presence of suspicious lesions on bpMRI. Among subjects that underwent

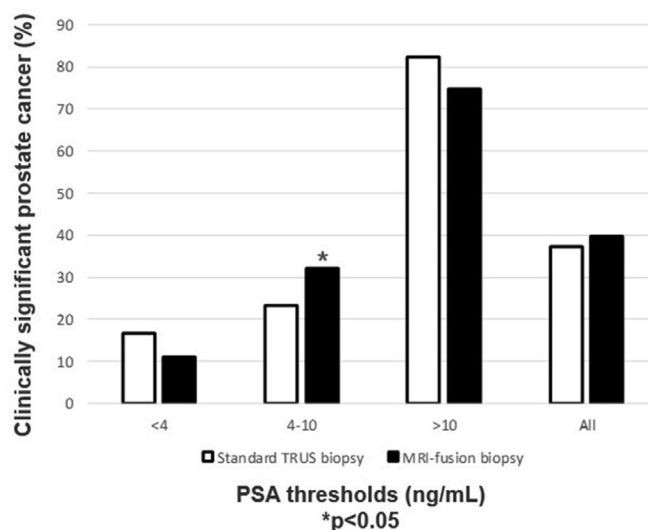


Fig. 2. Incidence of clinically significant prostate cancer between standard TRUS-guided biopsy and MRI/US-fusion biopsy according to PSA thresholds, PSA, prostate-specific antigen; TRUS, transrectal ultrasound; MRI, magnetic resonance image; PCa, prostate cancer; csPCa, clinically significant prostate cancer.

Table 3
Logistic regression analysis for the csPCa among patients with PSA 4–10 ng/mL

	Univariate		Multivariate	
	OR (95% CI)	P-value	OR (95% CI)	P-value
Age ^{a)}	1.10 (1.05–1.14)	<0.001	1.10 (1.06–1.15)	<0.001
PSA ^{b)}	1.13 (0.99–1.30)	0.073		
Prostate volume***	0.95 (0.93–0.97)	<0.001	0.96 (0.93–0.98)	<0.001
Prostate biopsy				
Standard TRUS	1 (Referent)		1 (Referent)	
MRI/US-fusion	2.32 (1.30–4.13)	0.004	2.46 (1.31–4.60)	0.005

PSA, prostate-specific antigen; TRUS, transrectal ultrasound; MRI, magnetic resonance image; csPCa, clinically significant prostate cancer.

*** ORs are for every 1 cc in prostate volume.

^{a)} ORs are for every 1 year in age.

^{b)} ORs are for every 1 ng/mL in PSA.

MRI/US-fusion biopsy ($n = 337$), 46.6% ($n = 157$) with suspicious cancer lesion underwent a combined TBx, whereas the other 53.4% ($n = 180$) with no suspicious cancer lesion underwent only a SBx. The detection rate of csPCa in the TBx was significantly higher compared to the SBx in males with PSA 4–10 ng/mL (TBx vs. SBx, 41.7% vs. 25.0%, $P = 0.013$). Meanwhile, bpMRI conferred no benefit in patients with PSA level <4 ng/mL and >10 ng/mL (Table 4).

4. Discussion

MRI is an important tool in the diagnosis, staging, surgical planning of prostate cancer recently. The 2020 European Association of Urology guidelines recommends an MRI for all males (biopsy-naïve and previous negative biopsy patients) with a clinical suspicion for PCa [13]. However, the use of MRI can place a significant financial and resource burden on the healthcare system. The addition of serum and urine biomarkers, such as PHI (Prostate Health Index) [14], 4K score [15], ExoDx [16], SelectMDx [15], PCA3 [17], and ConfirmMDx [18], can further improve the risk modeling for csPCa; however, these tests are too expensive and not always available in a routine clinical setting. Moreover, the use of these biomarkers does not exclude the need for a prostate MRI, which allows for TBx.

Multiple prior models based on clinical, laboratory, and TRUS finding parameters have been developed for improving detection rates and reducing unnecessary biopsies. The added value of mpMRI for the clinical variables in predicting biopsy outcome has already been demonstrated (PROMIS [3], PRECISION [4], MRI-FIRST [5], and 4M [6] trials). More recently, various settings for MRI findings have been developed. In a study by Lee et al. MRI without an intravenous contrast agent was able to accurately predict PCa

and csPCa in a transperineal prostate biopsy [19]. Boesen et al. developed an internally validated nomogram for predicting prostate biopsy outcome based on bpMRI [20].

In the present study, we demonstrated the reasonable performance and the potential clinical benefit of prebiopsy bpMRI findings with clinical variables for the detection of csPCa in males compared to the SBx. Previously, we used the mpMRI, including all MRI sequences (T2-weighted, diffusion-weighted, and dynamic contrast-enhanced imaging). It cost approximately 750 US dollars and took around 45 min to obtain all the necessary images. Although we demonstrated the efficacy of MRI for detecting csPCa, the cost and extended time made it difficult in a clinical setting. Thus, the use of a more rapid and cost-effective prostate MRI protocol, without the use of intravenous contrast agent, was required. The MRI protocol alteration consisted of only two sequences: axial T2-weighted and diffusion-weighted image. These sequences were acquired within 4 min and 8 min, respectively. The cost of the MRI was reduced to 250 US dollars from 750 US dollars. De Rooij et al. further reported the cost-effective MRI strategy compared to the standard TRUSbx [21].

We further analyzed how to optimize patient guidance according to the PSA levels. In males with the “gray zone” 4–10 ng/mL, the detection rate of csPCa in the MRI/US-fusion biopsy was higher compared to the standard TRUSbx after propensity score matching (35.0% vs. 26.6%, $P = 0.033$). Furthermore, the multivariate logistic regression analysis identified that age, PV, and MRI-fusion biopsy to be associated with csPCa. Wei et al. demonstrated that patients with a large PV (>50 mL) had a 5.22% risk of csPCa compared to males with the smallest PV (<30 mL) that had a 41.18% risk of csPCa. The risk of csPCa decreased significantly with increased PV ($P < 0.05$), and the combination of PI-RADS v2 and PV improved the diagnostic specificity and sensitivity (84.1% and 83.4%, respectively) of csPCa compared with that of PI-RADS v2 alone with PSA levels in the gray zone [7]. Al-Azab et al. showed that a smaller PV was the strongest predictor of PCa when the PSA level was in the 2–9 ng/mL range [22]. Polanec et al. showed that the combination of PI-RADS v2 scores with age and PSAD could help avoid unnecessary biopsies while still detecting the majority of csPCa cases [23]. In contrast, Cuocolo et al. confirmed that bpMRI was a powerful tool for detecting csPCa, while the combination of bpMRI with PSAD demonstrated no significant improvement compared to bpMRI alone [24]. The outcomes based on a larger PV corresponding to a lower risk of PCa were the result of a higher proportion of low-volume cancers in larger prostates. The relative contribution of detectable cancer to elevated PSA levels would be greater in patients with smaller prostate glands.

Table 4
The association between systemic and targeted biopsy in MRI-fusion biopsy ($n = 337$)

	MRI ($n = 337$)		P-value
	Suspicious cancer lesion (–) ($n = 180$)	Suspicious cancer lesion (+) ($n = 157$)	
Total PCa, n (%)	87 (48.3)	77 (49.0)	
csPCa, n (%)	63 (35)	71 (45.2)	
PSA category			
PSA <4 ng/mL ($n = 54$)			
Total PCa, n (%)	9/29 (31.0)	6/25 (24.0)	0.565
csPCa, n (%)	2/29 (6.9)	4/25 (16.0)	0.399
PSA 4–10 ng/mL ($n = 196$)			
Total PCa, n (%)	44/112 (39.3)	39/84 (46.4)	0.317
csPCa, n (%)	28/112 (25.0)	35/84 (41.7)	0.013
PSA >10 ng/mL ($n = 87$)			
Total PCa, n (%)	34/39 (87.2)	32/48 (66.7)	0.042
csPCa, n (%)	33/39 (84.6)	32/48 (66.7)	0.055

PSA, prostate specific antigen; TRUS, transrectal ultrasound; MRI, magnetic resonance image; PCa, prostate cancer; csPCa, clinically significant prostate cancer.

For males with PSA <4 ng/mL, there was no significant difference between the method of biopsy for csPCa. For this PSA level, the detection rate of csPCa was only 11.8% (15/108), and therefore, MRI/US-fusion biopsy did not affect the results. For males with PSA >10 ng/mL, the detection rate of PCa and csPCa in the standard biopsy group was higher compared to the TBx; SBx was sufficient for diagnosing of PCa in patients with PSA >10 ng/mL. For this PSA level, the detection rate of csPCa was 78.4% (135/172), and therefore, MRI-fusion biopsy did not affect the results. Thereby, we suggest that TRUS-guided systemic random biopsy is sufficient for males with PSA <4 ng/mL or >10 ng/mL.

There are several limitations to our study. First, this is a retrospective, single-center study that may lead to a selection bias. Adjustment for possible confounding factors was made by propensity score matching, although it is possible that unknown confounding factors may persist. Further multicenter large cohort studies are required to confirm our findings. Second, the actual detection rates of csPCa may have been underestimated compared to studies using whole-gland prostatectomy or template mapping biopsy. Third, data were interpreted using PI-RADS v2 on MRI by an experienced radiologist; it is also possible that one person interpreted the MRI findings, and there was bias in that interpretation.

5. Conclusion

In conclusion, we report that the MRI/US-fusion biopsy has a high accuracy for detecting csPCa compared to standard TRUSbx in patients with biopsy-naïve men with PSA levels in the gray zone of 4–10 ng/mL. This technique, considering the good performance and cost-effectiveness of the bpMRI, is a good option for initial prostate biopsy in a clinical setting.

Author's Contribution

Hye Jin Byun: Project development, Data Collection, Manuscript writing. Teak Jun Shin: Project development, Data analysis. Wonho Jung: Data collection. Ji Yong Ha: Data collection. Byung Hoon Kim: Project development, Manuscript editing. Young Hwan Kim: Project development.

Conflicts of interest

There is no conflict of interest.

References

- Sung H, Ferlay J, Siegel RL, Laversanne M, Soerjomataram I, Jemal A, et al. Global Cancer Statistics 2020: GLOBOCAN Estimates of Incidence and Mortality Worldwide for 36 Cancers in 185 Countries. *Ca - Cancer J Clin* 2021;71(3):209–249.
- Dwivedi DK, Kumar R, Dwivedi AK, Bora GS, Thulkar S, Sharma S, et al. Pre-biopsy multiparametric MRI-based risk score for predicting prostate cancer in biopsy-naïve men with prostate-specific antigen between 4–10 ng/mL. *J Magn Reson Imag* 2018;47(5):1227–1236.
- Ahmed HU, El-Shater Bosaily A, Brown LC, Gabe R, Kaplan R, Parmar MK, et al. Diagnostic accuracy of multi-parametric MRI and TRUS biopsy in prostate cancer (PROMIS): a paired validating confirmatory study. *Lancet* 2017;389(10071):815–822.
- Kasivisvanathan V, Rannikko AS, Borghi M, Panebianco V, Mynderse LA, Vaarala MH, et al. MRI-targeted or standard biopsy for prostate-cancer diagnosis. *N Engl J Med* 2018;378(19):1767–1777.
- Rouviere O, Puech P, Renard-Penna R, Claudon M, Roy C, Mege-Lechevallier F, et al. Use of prostate systematic and targeted biopsy on the basis of multiparametric MRI in biopsy-naïve patients (MRI-FIRST): a prospective, multi-centre, paired diagnostic study. *Lancet Oncol* 2019;20(1):100–109.
- van der Leest M, Cornel E, Israel B, Hendriks R, Padhani AR, Hoogenboom M, et al. Head-to-head comparison of transrectal ultrasound-guided prostate biopsy versus multiparametric prostate resonance imaging with subsequent magnetic resonance-guided biopsy in biopsy-naïve men with elevated prostate-specific antigen: a large prospective multicenter clinical study. *Eur Urol* 2019;75(4):570–578.
- Wei CG, Chen T, Zhang YY, Pan P, Dai GC, Yu HC, et al. Erratum to “Biparametric prostate MRI and clinical indicators predict clinically significant prostate cancer in men with “gray zone” PSA levels” [Eur. J. Radiol. 127 (2020) 108977]. *Eur J Radiol* 2020;129:109129.
- Cho J, Ahn H, Hwang SI, Lee HJ, Choe G, Byun SS, et al. Biparametric versus multiparametric magnetic resonance imaging of the prostate: detection of clinically significant cancer in a perfect match group. *Prostate Int* 2020;8(4):146–151.
- Mehralivand S, Bednarova S, Shih JH, Mertan FV, Gaur S, Merino MJ, et al. Prospective evaluation of PI-RADS version 2 using the International Society of Urological Pathology Prostate Cancer Grade Group System. *J Urol* 2017;198(3):583–590.
- Barrett T, Rajesh A, Rosenkrantz AB, Choyke PL, Turkbey B. PI-RADS version 2.1: one small step for prostate MRI. *Clin Radiol* 2019;74(11):841–852.
- Tewes S, Peters I, Tiemeyer A, Peperhove M, Hartung D, Pertschky S, et al. Evaluation of MRI/ultrasound fusion-guided prostate biopsy using transrectal and transperineal approaches. *BioMed Res Int* 2017;2017:2176471.
- D'Agostino Jr RB, D'Agostino Sr RB. Estimating treatment effects using observational data. *JAMA* 2007;297(3):314–316.
- Mottet N, Cornford P, Bergh RCNvd, Briers E, Santis MD, Gillissen S, et al. The prostate cancer guidelines. European Association of Urology [Internet] [cited 2020 Mar 26]. Available from: <https://uroweb.org/guideline/prostate-cancer/>.
- Chiu PK, Ng CF, Semjonow A, Zhu Y, Vincendeau S, Houlgate A, et al. A multicentre evaluation of the role of the prostate health index (PHI) in regions with differing prevalence of prostate cancer: adjustment of PHI reference ranges is needed for European and Asian settings. *Eur Urol* 2019;75(4):558–561.
- Wysocki JS, Becher E, Persily J, Loeb S, Lepor H. Concordance and performance of 4Kscore and SelectMDx for informing decision to perform prostate biopsy and detection of prostate cancer. *Urology* 2020;141:119–124.
- Tutrone R, Donovan MJ, Torkler P, Tadigotla V, McLain T, Noerholm M, et al. Clinical utility of the exosome based ExoDx prostate(IntelliScore) EPI test in men presenting for initial Biopsy with a PSA 2–10 ng/mL. *Prostate Cancer Prostatic Dis* 2020.
- Rodriguez SVM, Garcia-Perdomo HA. Diagnostic accuracy of prostate cancer antigen 3 (PCA3) prior to first prostate biopsy: A systematic review and meta-analysis. *Can Urol Assoc J* 2020;14(5):E214–9.
- Wojno KJ, Costa FJ, Cornell RJ, Small JD, Pasin E, Van Crielinge W, et al. Reduced rate of repeated prostate biopsies observed in ConfirmMDx clinical utility field study. *Am Health Drug Benefits* 2014;7(3):129–34.
- Lee SM, Liyanage SH, Wulaningsih W, Wolfe K, Carr T, Younis C, et al. Toward an MRI-based nomogram for the prediction of transperineal prostate biopsy outcome: a physician and patient decision tool. *Urol Oncol* 2017;35(11):664 e11–e18.
- Boesen L, Thomsen FB, Norgaard N, Logager V, Balslev I, Bisbjerg R, et al. A predictive model based on biparametric magnetic resonance imaging and clinical parameters for improved risk assessment and selection of biopsy-naïve men for prostate biopsies. *Prostate Cancer Prostatic Dis* 2019;22(4):609–616.
- de Rooij M, Crienens S, Witjes JA, Barentsz JO, Rovers MM, Grutters JP. Cost-effectiveness of magnetic resonance (MR) imaging and MR-guided targeted biopsy versus systematic transrectal ultrasound-guided biopsy in diagnosing prostate cancer: a modelling study from a health care perspective. *Eur Urol* 2014;66(3):430–436.
- Al-Azab R, Toi A, Lockwood G, Kulkarni GS, Fleshner N. Prostate volume is strongest predictor of cancer diagnosis at transrectal ultrasound-guided prostate biopsy with prostate-specific antigen values between 2.0 and 9.0 ng/mL. *Urology* 2007;69(1):103–107.
- Polanec SH, Bickel H, Wengert GJ, Arnoldner M, Clauser P, Susani M, et al. Can the addition of clinical information improve the accuracy of PI-RADS version 2 for the diagnosis of clinically significant prostate cancer in positive MRI? *Clin Radiol* 2020;75(2):157 e1–e7.
- Cuocolo R, Stanzione A, Rusconi G, Petretta M, Ponsiglione A, Fusco F, et al. PSA-density does not improve bi-parametric prostate MR detection of prostate cancer in a biopsy naïve patient population. *Eur J Radiol* 2018;104:64–70.