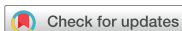

Case Report



# Infectious Spondylitis and Septicemia due to *Lactococcus garvieae*: a Literature Review of Non-Endocarditis Cases

Ji Yeon Lee , Miri Hyun , Hyun Ah Kim , and Seong Yeol Ryu   
Department of Infectious Diseases, Keimyung University Dongsan Hospital, Daegu, Korea

Open Access

## ABSTRACT

Lactococci are Gram-positive cocci that occur in short chains or pairs and are traditionally considered to be of low virulence in human. Most species are not associated with human disease. There are few reports regarding *Lactococcus* isolation in humans and the clinical significance of this rarely-encountered genus is unknown. Here, we report a case of infectious spondylitis due to *Lactococcus garvieae* confirmed by matrix-assisted laser desorption/ionization time-of-flight mass spectrometry (MALDI-TOFMS). A 77-year-old man was admitted to our hospital with back pain that had lasted 5 days. He had diabetes mellitus, hypertension, and histories of pulmonary tuberculosis and endovascular aneurysm repair due to an abdominal aortic aneurysm. Magnetic resonance imaging of his spine revealed paravertebral enhancement on T8-9 and a compression fracture on the lower endplate of T8. On blood cultures, *L. garvieae* was identified by MALDI-TOF MS. To our knowledge, this is the first report of spondylitis caused by *L. garvieae* in Korea. In this context, we reviewed non-endocarditis cases due to *L. garvieae* reported in the English-language literature to summarize its clinical features and outcomes.

**Keywords:** *Lactococcus garvieae*; Spondylitis; Bacteremia

## INTRODUCTION

Lactococci are Gram-positive, catalase-negative, facultative anaerobic cocci that occur in short chains or pairs and which are traditionally considered to be of low virulence to humans [1]. In 1985, based on genetic evidence of DNA-DNA and DNA-RNA relatedness, the genus *Lactococcus* was separated from that of *Streptococcus*. Most species are not associated with

human disease. There are few reports regarding *Lactococcus* isolation in humans and the clinical significance of this rarely-encountered genus is unknown. Among the eight species and subspecies, *L. garvieae* is responsible for the majority of reported cases of opportunistic human infections in the literature. The most well-recognized clinical syndrome of human *L. garvieae* infection is infective endocarditis [2-4]. Other reported cases included liver abscess, secondary peritonitis, diverticulitis, catheter-related urinary tract infection

**Received:** Feb 26, 2019  
**Accepted:** Jun 2, 2019  
**Published online:** Sep 1, 2020

**Corresponding Author:**  
Seong Yeol Ryu, MD, PhD  
Department of Infectious Diseases, Keimyung University Dongsan Hospital, Keimyung University School of Medicine, 1035, Dalgubeol-daero, Dalseo-gu, Daegu 42601, Korea.  
Tel: +82-53-258-7722, Fax: +82-53-258-4953  
Email: 121rsy@hanmail.net

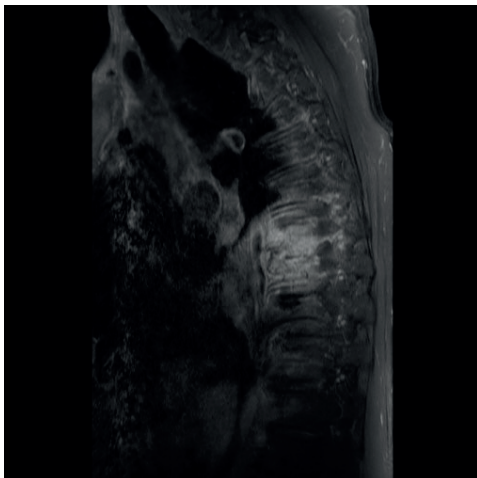
Copyright © 2023 by The Korean Society of Infectious Diseases, Korean Society for Antimicrobial Therapy, and The Korean Society for AIDS

This is an Open Access article distributed under the terms of the Creative Commons Attribution Non-Commercial License (<https://creativecommons.org/licenses/by-nc/4.0/>) which permits unrestricted non-commercial use, distribution, and reproduction in any medium, provided the original work is properly cited.

and infectious spondylitis associated with endocarditis [5-8]. Here we report a case of infectious spondylitis with septicemia due to *L. garvieae* that was confirmed by MALDI-TOFMS (bioMerieux, Marcy l'Étoile, France). To our knowledge, this is the first report in Korea of spondylitis caused by *L. garvieae*.

## CASE REPORT

A 77-year-old man was admitted to our hospital with back pain that had lasted for 5 days. He had diabetes mellitus, hypertension, and histories of pulmonary tuberculosis and endovascular aneurysm repair due to an abdominal aortic aneurysm. On examination, his vital signs included the following: temperature 36.5°C, blood pressure 120/80 mmHg, pulse rate 62/min, and respiratory rate 19/min. Laboratory evaluation revealed a white blood cell count of 6,840/mm<sup>3</sup> (neutrophil 87.3%), C-reactive protein of 3.75 mg/dL, blood urea nitrogen of 17 mg/dL, creatinine of 0.99 mg/dL, aspartate aminotransferase of 12 IU/L, alanine aminotransferase of 13 IU/L. Magnetic resonance imaging (MRI) of the spine revealed paravertebral enhancement on T8-9 and a compression fracture on the lower endplate of T8 (Fig. 1). No specific finding was observed in the chest and abdominal computed tomography. Two sets of blood cultures of samples drawn from two different peripheral sites were collected on admission. Two sets of blood cultures from the date of admission yielded growth of Gram-positive cocci in chains. *L. garvieae* was identified by MALDI-TOF MS. Antimicrobial susceptibilities were determined by disk



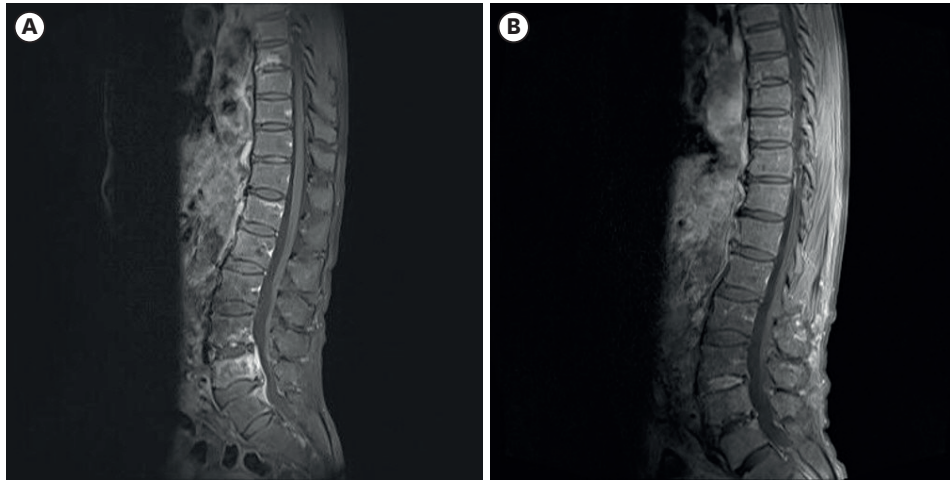
**Figure 1.** T1-weighted magnetic resonance imaging of the spine at first admission showing abnormal contrast enhancement in the paravertebral enhancement on T8-9 and a compression fracture on the lower endplate of T8.

**Table 1.** Antibiotic susceptibilities of *Lactococcus garvieae* isolate in this case report

Antimicrobial agent	Inhibition growth diameter (mm)	Susceptibility
Cefotaxime	28	S
Clindamycin	6	R
Erythromycin	24	S
Levofloxacin	20	S
Penicillin	10	R
Vancomycin	18	S
Cefepime	26	S

S, susceptible; R, resistant.

diffusion tests. Because the Clinical Laboratory Standards Institute (CLSI) has not yet established *Lactococcus* minimum inhibitory concentration (MIC) breakpoints, the susceptibilities were determined based on the CLSI recommendations for viridans streptococci. The isolate was susceptible to cefotaxime, cefepime, erythromycin, levofloxacin, and vancomycin were susceptible, and was resistant to penicillin and clindamycin (Table 1). The vertebral biopsy was not performed. A transthoracic echocardiogram showed normal heart valves without vegetation. Ampicillin/sulbactam was started as an empirical antibiotics (3 g every 6 hours). After confirmation of the susceptibilities, the antibiotics was changed to 2 g ceftriaxone, administered every 24 hours. A follow-up blood culture sample drawn on hospital day 6 was negative. Intravenous ceftriaxone was administered for 2 weeks and was then switched to oral cefditoren (100 mg three times daily). After 4 months of oral antibiotic administration, his back pain and laboratory findings were improved, and the patient stopped taking medication. One month later, his back pain was aggravated. Two sets of blood cultures of samples drawn from two different peripheral sites were collected on admission. *L. garvieae* bacteremia was again identified. The susceptibilities of antibiotics were same as previous. A spine MRI revealed vertebral enhancement on T6-7 and L4-5 as well as anterior epidural enhancement on L5-6 (Fig. 2A). Positron emission tomography-computed tomography (PET-CT) showed diffuse FDG uptake on L5-S2, and no evidence of graft infection on the abdominal aorta. A transesophageal echocardiogram showed normal heart valves without vegetation. Cefepime was started after confirmation of *L. garvieae* bacteremia. Intravenous cefepime was administered for 1 month and was then switched to oral levofloxacin (750 mg once a day). After 6 months of oral levofloxacin, follow-up MRI revealed improvement of the previous lesions as compared to the previous MRI findings (Fig. 2B). The antibiotics were stopped and the patient remained well at follow-up 4 months.



**Figure 2.** (A) T1-weighted magnetic resonance imaging of the lumbar spine at the second admission showing bone marrow signal abnormality and enhancement in T6-7 and L4-5 vertebral bodies as well as L5-6 anterior epidural enhancement. (B) Follow-up T1-weighted magnetic resonance imaging after 1 month of cefepime and 6 months of oral levofloxacin treatment, showing improvement of the previous lesions as compared to the previous image findings.

## DISCUSSION

The genus *Lactococcus* was separated from that of *Streptococcus* in 1985. It was first isolated from bovines with mastitis and then from fish and human specimens [9]. In summer, the higher water temperature is most suitable for breeding prawns, trout, and mullets, which carry the highest risk of lactococcosis [10]. In recent years, *L. garvieae* has been recognized as an emerging zoonotic pathogen, due to the increasing number of cases of human infections.

The suggested points of entry for *L. garvieae* are anatomic or physiologic defects of the gastrointestinal tract or the use of acid-suppressing medications; however often, no source of entry is identified. Wang et al. [5] suggested that the consumption of raw seafood during the summer by patients with underlying gastrointestinal diseases may be a potential predisposing factor for *L. garvieae* infection. The acid pH of the stomach, pancreatic enzymes, bile and intestinal secretions, peristalsis and the integrity of epithelial cells are important antimicrobial factors that prevent infection through the oral gastrointestinal route [5]. In addition, skin wounds can be a site of entry leading to *L. garvieae* infection [11]. Contaminated milk and unpasteurized dairy products can also be sources of infection. Moreover, *L. garvieae* have also been isolated in manufactured food due to their use in food products [12]. Our patient was exposed to raw fish. However, he did not suffer from any gastrointestinal disease and had not taken acid-

suppressing medication. He denied any consumption of unpasteurized dairy products.

*L. garvieae* can be easily misidentified as *Enterococcus* species. Automated microbial identification systems such as the VITEK-2 have been helpful for identification but the results should be confirmed with a different method, such as MALDI-TOFMS or 16S rRNA sequencing [2].

A previous report of *L. garvieae* spondylitis identified by percutaneous bone biopsy had L3-4 involvement without bacteremia. The clinical symptoms improved after 6 weeks of intravenous ampicillin. However, our patient was switched to oral antibiotics after 2 weeks of intravenous ceftriaxone. Back pain was aggravated one month after antibiotic termination, and the bacteremia recurred with worsening of the spondylitis. The cause of worsening was likely the short duration of intravenous antibiotics and more data are required to evaluate the prognosis of *L. garvieae* spondylitis. Including our case, a total of 10 cases of *L. garvieae* infection except for endocarditis have been reported in the English-language literature [5-7, 10-14]. Intraabdominal infection was the most common source (5/10, 50.0%), followed by bone and joint infection (4/10, 40.0%). Half of the cases had bacteremia. Seven cases (70.0%) had risk factors including gastrointestinal disease or history of exposure to raw fish. Only one patient died. Of *L. garvieae* endocarditis cases, 84.2% had risk factors for *L. garvieae* infection and the mortality rate was 21.1% [4]. The mean ages were  $63.3 \pm 13.6$  and  $68.7 \pm 11.4$  years in non-endocarditis and endocarditis patients, respectively.

**Table 2.** Characteristics of patients with infections other than endocarditis due to *Lactococcus garvieae*

Clinical syndrome	Age	Sex	Site	Raw fish	Underlying disease	Treatment	Outcome	Reference
Diverticulitis	56	F	Blood	None	Small bowel diverticulosis	Cefazolin, gentamicin → cotrimoxazole	Survival	[5]
Peritonitis	47	M	Ascite	Yes	Small bowel perforation	Piperacillin, amikacin	Survival	[5]
Osteomyelitis	56	F	Blood	UK	AS s/p AVR	Vancomycin → teicoplanin	Survival	[6]
Liver abscess	68	F	Blood	None	Cholangiocarcinoma Duodenal bleeding due to hemobilia	Amoxicillin, netilmicin, metronidazole	Death	[7]
PD peritonitis	38	M	PD effluent	None	IgAN s/p steroid on PD	IP cefazolin	Survival	[10]
Prosthetic hip joint infection	71	F	Joint fluid	UK	HTN, DM, IHD, osteonecrosis s/p THR	Ceftriaxone, levofloxacin	Survival	[11]
Spondylodiscitis	70	M	Bone	UK	Gastritis (long administration of H2 blocker)	Ampicillin	Survival	[12]
Primary bacteremia	81	M	Blood	UK	VHD CHF s/p MVR, AVR, pacemaker, HTN, CKD, diverticulitis, reflux esophagitis	Piperacillin/tazobactam → ampicillin, gentamicin	Survival	[13]
Acute cholecystitis	69	M	Gall bladder	Yes	Gastric ulcer perforation s/p gastrectomy	Cefminox → cefaclor	Survival	[14]
Spondylodiscitis	77	M	Blood	Yes	HTN, DM, AAA s/p EVAR	Ceftriaxone → cefditoren Cefepime → levofloxacin	Survival	Current case

F, female; M, male; UK, unknown; AS, aortic stenosis; s/p, status post operation; AVR, aortic valve replacement; IgAN, immunoglobulin A nephropathy; PD, peritoneal dialysis; IP, intraperitoneal; HTN, hypertension; DM, diabetes mellitus; IHD, ischemic heart disease; THR, total hip replacement; VHD, valvular heart disease; CHF, congestive heart failure; MVR, mitral valve replacement; CKD, chronic kidney disease; AAA, abdominal aortic aneurysm; EVAR, endovascular aneurysm repair.


Non-endocarditis cases had a lower incidence of risk factors and mortality rate but more data and studies are needed for statistical significance (Table 2).

In conclusion, the number of human infections by *L. garvieae* is expected to increase. *L. garvieae* should be considered a causative pathogen of spondylitis, especially in cases of gastrointestinal disorder or exposure to raw fish. Additional tests such as MALDI-TOFMS or 16S rRNA sequencing are required for the identification of *L. garvieae*.

#### ORCID iDs

Ji Yeon Lee 

<https://orcid.org/0000-0002-2788-1392>

Miri Hyun 

<https://orcid.org/0000-0003-0062-342X>

Hyun Ah Kim 

<https://orcid.org/0000-0002-9125-7156>

Seong Yeol Ryu 

<https://orcid.org/0000-0002-6023-8550>

#### Ethics statement

This study was approved by the Institutional Review Board at the Keimyung University Dongsan Hospital (IRB No. 2020-08-027). This research was approved for a waiver of consent by the IRB as it used retrospective data.

#### Conflict of Interest

No conflicts of interest.

#### Author Contributions

Conceptualization: SYR, JYL. Writing - original draft: JYL.

Writing - review & editing: SYR, JYL, MH, HAK.

## REFERENCES

- Collins MD, Farrow JA, Phillips BA, Kandler O. *Streptococcus garvieae* sp. nov. and *Streptococcus plantarum* sp. nov. J Gen Microbiol 1983;129:3427-31.  
[PUBMED](#)
- Fefer JJ, Ratzan KR, Sharp SE, Saiz E. *Lactococcus garvieae* endocarditis: report of a case and review of the literature. Diagn Microbiol Infect Dis 1998;32:127-30.  
[PUBMED](#) | [CROSSREF](#)
- Vinh DC, Nichol KA, Rand F, Embil JM. Native-valve bacterial endocarditis caused by *Lactococcus garvieae*. Diagn Microbiol Infect Dis 2006;56:91-4.  
[PUBMED](#) | [CROSSREF](#)
- Suh Y, Ja Kim M, Seung Jung J, Pil Chong Y, Hwan Kim C, Kang Y, Wook Sohn J, Kyung Yoon Y. Afebrile multi-valve infective endocarditis caused by *Lactococcus garvieae*: a case report and literature review. Intern Med 2016;55:1011-5.  
[PUBMED](#) | [CROSSREF](#)
- Wang CY, Shie HS, Chen SC, Huang JP, Hsieh IC, Wen MS, Lin FC, Wu D. *Lactococcus garvieae* infections in humans: possible association with aquaculture outbreaks. Int J Clin Pract 2007;61:68-73.  
[PUBMED](#) | [CROSSREF](#)
- James PR, Hardman SM, Patterson DL. Osteomyelitis and possible endocarditis secondary to *Lactococcus garvieae*: a first

- case report. *Postgrad Med J* 2000;76:301-3.  
[PUBMED](#) | [CROSSREF](#)
7. Mofredj A, Baraka D, Kloeti G, Dumont JL. *Lactococcus garvieae* septicemia with liver abscess in an immunosuppressed patient. *Am J Med* 2000;109:513-4.  
[PUBMED](#) | [CROSSREF](#)
  8. Choksi TT, Dadani F. Reviewing the emergence of *Lactococcus garvieae*: a case of catheter associated urinary tract infection caused by *Lactococcus garvieae* and *Escherichia coli* coinfection. *Case Rep Infect Dis* 2017;2017:5921865.  
[PUBMED](#) | [CROSSREF](#)
  9. Vela AI, Vázquez J, Gibello A, Blanco MM, Moreno MA, Liébana P, Albendea C, Alcalá B, Mendez A, Domínguez L, Fernández-Garayzábal JF. Phenotypic and genetic characterization of *Lactococcus garvieae* isolated in Spain from lactococcosis outbreaks and comparison with isolates of other countries and sources. *J Clin Microbiol* 2000;38:3791-5.  
[PUBMED](#) | [CROSSREF](#)
  10. Chao CT, Lai CF, Huang JW. *Lactococcus garvieae* peritoneal dialysis peritonitis. *Perit Dial Int* 2013;33:100-1.  
[PUBMED](#) | [CROSSREF](#)
  11. Aubin GG, Bémer P, Guillouzoic A, Crémet L, Touchais S, Fraquet N, Boutoille D, Reynaud A, Lepelletier D, Corvec S. First report of a hip prosthetic and joint infection caused by *Lactococcus garvieae* in a woman fishmonger. *J Clin Microbiol* 2011;49:2074-6.  
[PUBMED](#) | [CROSSREF](#)
  12. Chan JF, Woo PC, Teng JL, Lau SK, Leung SS, Tam FC, Yuen KY. Primary infective spondylodiscitis caused by *Lactococcus garvieae* and a review of human *L. garvieae* infections. *Infection* 2011;39:259-64.  
[PUBMED](#) | [CROSSREF](#)
  13. Nadrah K, Cerar T, Papst L, Volkar-Meglić J, Matičič M, Karner P, Vidmar L, Premru MM, Beović B. *Lactococcus garvieae* septicaemia in a patient with artificial heart valves. *Wien Klin Wochenschr* 2011;123:677-9.  
[PUBMED](#) | [CROSSREF](#)
  14. Kim JH, Go J, Cho CR, Kim JI, Lee MS, Park SC. First report of human acute acalculous cholecystitis caused by the fish pathogen *Lactococcus garvieae*. *J Clin Microbiol* 2013;51:712-4.  
[PUBMED](#) | [CROSSREF](#)