



# A prospective randomized controlled study comparing patient-reported scar evaluation of single-port versus multiport laparoscopic appendectomy for acute appendicitis

Kyeong Eui Kim<sup>1</sup>, In Soo Cho<sup>1</sup>, Sung Uk Bae<sup>1</sup>, Woon Kyung Jeong<sup>1</sup>, Hyung Jin Kim<sup>2</sup>,  
Seong Kyu Baek<sup>1</sup>

<sup>1</sup>Department of Surgery, Keimyung University Dongsan Medical Center, Keimyung University School of Medicine, Daegu, Korea

<sup>2</sup>Division of Colorectal Surgery, Department of Surgery, St. Vincent's Hospital, College of Medicine, The Catholic University of Korea, Suwon, Korea

**Purpose:** This study aimed to compare the postoperative outcomes and patient-surveyed scar assessments of single-port laparoscopic appendectomy (SPLA) with the outcomes of multiport laparoscopic appendectomy (MPLA).

**Methods:** Between August 2014 and November 2017, the prospective randomized study comprised 98 patients diagnosed with acute appendicitis and indicated for surgery. Fifty-one patients had MPLA and 47 patients received SPLA. The primary endpoint was the total score of Patient Scar Assessment Questionnaire (PSAQ) administered to patients 6 weeks after surgery.

**Results:** SPLA involved a shorter median operative time than MPLA (47.5 minutes vs. 60.0 minutes,  $p = 0.02$ ). There were no apparent differences in the time before diet tolerance, length of hospital stay, and postoperative complication. SPLA patients had shorter total incision length (2.0 cm vs. 2.5 cm,  $p < 0.01$ ) and required fewer analgesics on the day of surgery than MPLA patients ( $p = 0.011$ ). The PSAQ favored the SPLA approach, revealing significant differences in total score (48 vs. 55,  $p = 0.026$ ), appearance (15 vs. 18,  $p = 0.002$ ), and consciousness (8 vs. 10,  $p = 0.005$ ), while satisfaction with appearance and symptoms scale did not ( $p = 0.162$  and  $p = 0.690$ , respectively).

**Conclusion:** The postoperative scar evaluated by the patient was better with SPLA than with MPLA, and patient satisfaction with the scar was comparable between the two techniques.

**Keywords:** Laparoscopy, Appendectomy, Natural orifice endoscopic surgery, Cosmetic techniques, Octyl 2-cyanoacrylate

**Received** April 27, 2023

**Revised** June 10, 2023

**Accepted** June 11, 2023

#### Corresponding author

Sung Uk Bae

Department of Surgery, Keimyung University Dongsan Medical Center, Keimyung University School of Medicine, 1035 Dalgubeol-daero, Dalseo-gu, Daegu 42601, Korea

E-mail: hispower@dsmc.or.kr

<https://orcid.org/0000-0002-7876-4196>

© 2023 The Korean Society of Endo-Laparoscopic & Robotic Surgery  
This is an Open Access article distributed under the terms of the Creative Commons Attribution Non-Commercial License (<http://creativecommons.org/licenses/by-nc/4.0/>) which permits unrestricted non-commercial use, distribution, and reproduction in any medium, provided the original work is properly cited.

## INTRODUCTION

Laparoscopic surgery is replacing laparotomy for the treat-

ment of various types of abdominal surgery and offers several advantages over open surgery, including lower blood loss, fewer analgesic needs, fewer problems, quicker postoperative

resuming, and a shorter hospital stay [1,2]. Since Semm [3] introduced laparoscopic appendectomy in 1983, its applicability has extended to include more complicated patients, such as complicated appendicitis [4,5].

As minimally invasive surgery has rapidly developed in recent years, novel efforts have been aimed at minimizing surgical trauma and improving cosmetic outcomes. These concepts have led to the development of single-port laparoscopic surgery for various diseases [6,7]. Esposito developed single-port laparoscopic appendectomy (SPLA) for the first time in 1998 [8], and its potential benefits include improved cosmetic outcome, less postoperative pain, and avoidance of potentially hemorrhagic consequences from injury to epigastric arteries [9,10].

Considered crucial to postoperative quality of life are cosmetic outcomes and postoperative pain control. SPLA requires a larger transumbilical incision and some have questioned if SPLA might actually cause better cosmesis and less pain compared with multiport laparoscopic appendectomy (MPLA). To date, several studies have described the cosmetic and clinical results of SPLA; however, there is insufficient information to answer these questions.

The objective of our study was to compare the patient-reported scar evaluation at 6 weeks after SPLA with the outcomes of MPLA.

## METHODS

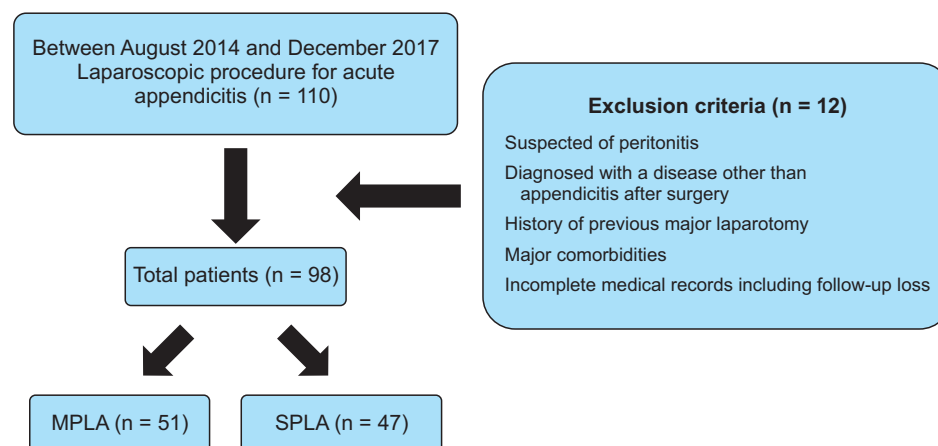
### Patients

This investigator-initiated randomized controlled trial was performed between August 2014 and December 2017 at Keimyung University Dongsan Medical Center, Daegu, Korea. A total of 110 patients were screened for eligibility for this trial (Fig. 1). Appendicitis was diagnosed based on the following criteria: a

history of right lower quadrant pain or periumbilical pain migrating to the right lower quadrant with nausea and/or vomiting, a fever of greater than 38 °C and/or leukocytosis of greater than 10,000 cells/mm, and right lower quadrant tenderness on physical examination. In addition, abdominal computed tomography was performed to confirm the diagnoses. All individuals involved in the study were younger than 75 years old. Utilizing computerized random number tables, patients were assigned to research groups at random. A flowchart of the study process is provided in Fig. 1. Four colorectal surgeons who participated in this study performed more than 100 cases of MPLA and SPLA over a period of more than 3 years. The study's exclusion criteria for the 110 patients evaluated were as follows: (1) one patient with suspected panperitonitis, (2) four patients diagnosed with a disease other than appendicitis after surgery, (3) two patients with history of previous major laparotomies such as gastrectomy and hepatectomy, (4) one patient with comorbidities such as cardiopulmonary failure, liver failure, or chronic kidney disease, and (5) four patients with incomplete medical records were excluded from this study. Finally, 51 patients were assigned to the MPLA group and 47 to the SPLA group. The primary endpoints were total score of Patient Scar Assessment Questionnaire (PSAQ) at 6 weeks postoperatively, and the secondary endpoints were postoperative pain score using a standard visual analog scale (VAS) after 6 hours, 12 hours, and 24 hours postoperatively and the number of use of analgesics on the day of surgery and on the first day after surgery. Before the surgery, a single dose of cefotetan 1 mg was administered prior to the incision. Following the surgery, cefotetan 1 mg was administered twice as a routine treatment.

### Evaluation parameters

Age, sex, preoperative white blood cell (WBC) and C-reactive



**Fig. 1.** Flowchart of patient selection. MPLA, multiport laparoscopic appendectomy; SPLA, single-port laparoscopic appendectomy.

protein (CRP), body mass index, type and location of appendicitis, presence of periappendiceal abscess, and onset of abdominal pain were recorded as patient demographics. Surgical outcomes included operative time, intraoperative blood loss, total incision length, appendix diameter and length, adhesion, intraabdominal fluid collection, intraabdominal drainage, and extra port use. In this study, the port insertion time was defined as the time from skin incision to port placement, the laparoscopic procedure time was defined as the time from completion of port placement to port removal after appendectomy, and the skin closure time was defined as the time required to close the port site incisions. Postoperative outcomes consisted of time to gas out and soft diet, length of stay, pain score using VAS 6, 12, and 24 hours after operation, total number of analgesics used on postoperative days 0 and 1, and inflammatory serum markers such as WBC and CRP 12 and 24 hours after operation.

### Surgical technique

MPLA necessitated the insertion of a videoscope through an umbilical incision and two further incisions in the suprapubic region and left lower abdominal quadrant. The patient was positioned in a supine position with their head facing down and their left side facing down. The appendix was exposed, and the mesoappendix was separated using a rigid laparoscopic instrument and an advanced energy device or a monopolar energy device with clipping. The appendix's base was ligated using two Endoloop (Ethicon Endosurgery) or the Endo-GIA stapler (Covidien). Specimens were extracted through the umbilical incision using a sterile bag. Following removal of the trocar, the fascia was closed with interrupted 2-0 vicryl sutures (B. Braun

Aesculap AG & Co KG). The skin was closed using interrupted suture with 3-0 nylon or a skin stapler, or 4-0 absorbable monofilament suture with a sterile strip.

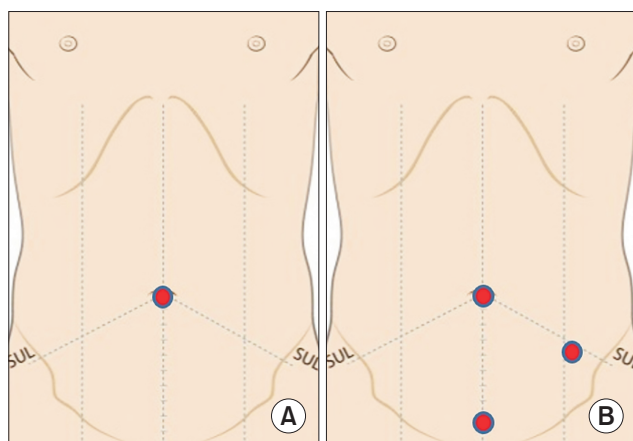
After the base of the umbilical stalk was severed using Allis tissue forceps, a single 2.0-cm vertical incision was made through the umbilical skin in SPLA (Fig. 2). The subcutaneous tissue was dissected in the direction of the linea alba, and the peritoneum was opened. Through the transumbilical incision, a single port was inserted into the abdominal cavity. After pneumoperitoneum had been achieved, a 5-mm diameter rigid telescope, with a fiber-optic light transmission and a 30° angled view, was inserted through the 5-mm channel of the single-port. The separation of mesoappendix was undergone using rigid laparoscopic instruments and an advanced energy device or a monopolar energy device with clipping. The other procedure was similar to that of the MPLA. The appendix was removed via the sterile bag component of the single port without the use of endo-bag. The skin was closed with 3-0 nylon or a skin stapler, or 4-0 monofilament absorbable suture with sterile strip.

### Patient Scar Assessment Questionnaire scores at 6 weeks postoperatively

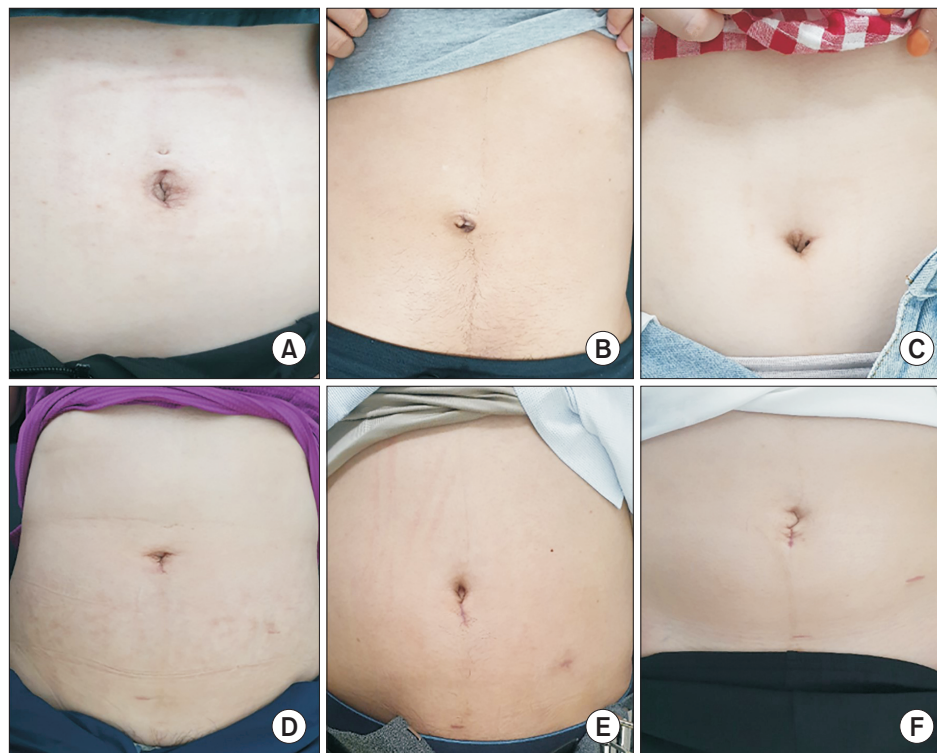
At 6 weeks postoperatively, patients completed the PSAQ via telephone (Fig. 3). Four subitems comprise the PSAQ: appearance, consciousness, satisfaction with appearance, and satisfaction with symptoms [11]. Scar color, width, flatness, texture, sheen, and overall appearance were evaluated for the appearance subitem. The subitem for consciousness was further subdivided into itching, pain, discomfort, numbness, strange sensations, and the general bothersomeness of symptoms. Satisfaction with appearance subitem was determined based on how obvious the scar was to the patient and others, as well as the patient's overall self-consciousness regarding the scar. The satisfaction with symptoms subitem was evaluated based on the scar's numbness, color, likeness to the surrounding skin, and overall appearance. Each subitem consists of a set of four-point categorical responses with scores ranging from one to four points (one point is assigned to the most favorable response and four points are assigned to the least favorable response).

### Statistical analysis

The main analyses will be based on the intention-to-treat principle. The intention-to-treat population will include all randomized participants who start on treatment, excluding consent withdrawals. The prospective randomized trial used parallel



**Fig. 2.** Port placement for single-port (A) and multiport (B) laparoscopic appendectomy.



**Fig. 3.** Postoperative scar of single-port (A–C) and multiport (D–F) laparoscopic appendectomy.

group on superiority design and the sample size was obtained before study initiation. The sample size calculation was based on the difference in PSAQ at 6 weeks after surgery between the MPLA and SPLA groups of four points with  $\alpha$ -error of 0.05,  $\beta$ -power of 80%, and 10% follow-up loss rate; the sample size was 110 patients (55 patients in each arm). The results were reported as means and standard deviations for continuous outcomes, and as frequencies and percentages for categorical outcomes. Categorical variables were analyzed using the chi-square statistic and continuous variables were examined with an independent *t*-test. A *p*-value of less than 0.05 was regarded as statistically significant. IBM SPSS version 25 was used for the statistical analysis (IBM Corp.).

## RESULTS

### Baseline characteristics

Table 1 describes the baseline characteristics of the MPLA and SPLA groups. There were no statistically significant differences between the two groups in terms of sex, body mass index, or age distribution. In both groups, suppurative appendicitis was the most prevalent kind, and the proportions of suppurative, gangrenous, and perforated appendicitis did not differ significantly. The retrocecal position of the appendix tip was statisti-

cally the most prevalent in both groups. Two patients in the MPLA group (3.9%) and one patient in the SPLA group (2.1%) suffered periappendiceal abscess. The onset of symptoms (1 day vs. 2 days,  $p = 0.780$ ), preoperative WBC (12,480 cells/mL vs. 12,560 cells/mL,  $p = 0.663$ ), and CRP (1.74 mg/dL vs. 1.46 mg/dL,  $p = 0.661$ ) did not differ significantly between the two groups.

### Perioperative outcomes

The MPLA group had considerably longer median total operative times than the SPLA group (60 minutes vs. 47.5 minutes,  $p = 0.02$ ) (Table 2). In detail, the median of port insertion time and laparoscopic procedure time were shorter in the SPLA group than in the MPLA group (5 and 27.5 minutes vs. 6 and 41 minutes;  $p = 0.05$  and  $p < 0.01$ , respectively), whereas the mean of skin closure time was significantly longer in the SPLA group than in the MPLA group (13 minutes vs. 10 minutes,  $p < 0.01$ ). The diameter and length of the appendix did not differ substantially across groups. Total incision length was less in the SPLA group than in the MPLA group (20.1 mm vs. 27.3 mm,  $p < 0.001$ ). In nine patients in each group, intraabdominal drainage was required. Due to severe inflammation and adhesion, seven patients (14.9%) treated with SPLA required an additional 2-mm port insertion and one patient (1.9%) treated with MPLA

**Table 1.** Baseline characteristics

Characteristic	MPLA group	SPLA group	p-value
No. of patients	51	47	
Age (yr)	40.9 ± 14.3	42.6 ± 14.3	0.545
Sex, n (%)			
Male	31 (56.4)	24 (43.6)	0.440
Female	20 (46.5)	23 (53.5)	
Body mass index (kg/m <sup>2</sup> )	24.3 ± 4.4	23.5 ± 3.4	0.281
ASA PS grade			0.427
I	46 (90.2)	41 (87.2)	
II	3 (5.9)	5 (10.6)	
III	2 (3.9)	1 (2.1)	
Type of appendicitis			0.213
Suppurative	37 (72.5)	29 (61.7)	
Gangrenous	6 (11.8)	12 (25.5)	
Perforated	8 (15.7)	6 (12.8)	
Location of appendicitis			0.443
Retrocecal	37 (72.5)	34 (72.3)	
Pelvic	4 (7.8)	2 (4.3)	
Retroperitoneal	1 (2.0)	4 (8.5)	
Antececal	9 (17.6)	7 (14.9)	
Periappendiceal abscess	2 (3.9)	1 (2.1)	0.607
Duration of pain (day)	4.8 ± 13.2	4.2 ± 11.1	0.778
Preoperative WBC (cells/mL)	12,390 ± 3,987	12,918 ± 5,241	0.578
Preoperative CRP (mg/dL)	3.4 ± 4.7	3.9 ± 5.6	0.697

Values are presented as number only, mean ± standard deviation, or number (%).

MPLA, multiport laparoscopic appendectomy; SPLA, single-port laparoscopic appendectomy; ASA, American Society of Anesthesiologists; PS, physical status; WBC, white blood cell; CRP, C-reactive protein.

**Table 2.** Perioperative outcomes

Variable	MPLA group (n = 51)	SPLA group (n = 47)	p-value
Total operative time (min)	63.0 ± 21.0	52.2 ± 19.4	0.010
Port insertion time (min)	8.5 ± 8.5	6.0 ± 2.8	0.053
Laparoscopic procedure time (min)	44.2 ± 20.5	33.8 ± 18.5	0.010
Skin closure time (min)	6.8 ± 5.8	6.4 ± 7.4	0.756
Intraoperative bleeding (mL)	9.2 ± 10.4	7.9 ± 8.3	0.486
Total incision length (mm)	27.3 ± 8.9	20.1 ± 6.6	<0.001
Diameter of appendix (mm)	12.2 ± 5.6	11.6 ± 3.5	0.558
Length of appendix (mm)	66.1 ± 19.0	66.6 ± 22.1	0.901
Intraabdominal drainage	9 (17.6)	9 (19.1)	0.848
Additional port insertion			0.011
5 mm	1	0	
2 mm	0	7	

Values are presented as mean ± standard deviation, number (%), or number only.

MPLA, multiport laparoscopic appendectomy; SPLA, single-port laparoscopic appendectomy.

required an additional 5-mm port placement for effective surgical traction.

### Postoperative outcomes

There were no significant differences between groups in terms of time to gas out and soft diet and length of stay (Table 3). Inflammatory test results, including WBC and CRP, were statistically identical 12 and 24 hours after surgery. Four patients in the MPLA group (7.8%) experienced superficial surgical site infection (SSI), one of them was readmitted for intravenous antibiotics treatment and wound management. Two patients (4.2%)

experienced superficial SSI and one patient (2.1%) had postoperative ileus in the SPLA group. Two patients with superficial SSI were treated with daily dressings, and one patient with ileus was managed conservatively with hydration and nasogastric tube placement. Concerning postoperative pain, VAS scores 6, 12, and 24 hours after surgery did not differ significantly between two groups (3 vs. 3,  $p = 0.672$ ; 4 vs. 3,  $p = 0.319$ ; 3 vs. 3,  $p = 0.380$ , respectively) (Table 4). The MPLA group used more analgesics on postoperative day ( $p = 0.011$ ); however, the two groups used equivalent amounts on postoperative day 1.

**Table 3.** Postoperatively clinical and hematological outcomes

Variable	MPLA group (n = 51)	SPLA group (n = 47)	p-value
Gas out (day)	1.17 ± 0.58	1.43 ± 0.88	0.078
Time to soft diet (day)	1.39 ± 1.50	1.53 ± 1.33	0.626
Length of stay (day)	2.71 ± 1.89	2.89 ± 1.56	0.592
White blood cell			
After 12 hr	10,200 ± 3,841	10,637 ± 3,456	0.564
After 24 hr	8,560 ± 2,878	9,092 ± 2,730	0.391
C-reactive protein			
After 12 hr	7.34 ± 5.36	8.09 ± 6.91	0.555
After 24 hr	9.76 ± 8.55	9.11 ± 7.45	0.715
Morbidity within 28 days after surgery	4 (7.8)	3 (6.4)	0.779
Superficial SSI	4 (7.8)	2 (4.2)	
Ileus	0 (0)	1 (2.1)	
Clavien-Dindo classification			0.987
<IIIa	4 (7.8)	2 (4.2)	
≥IIIa	0 (0)	1 (2.1)	

Values are presented as mean ± standard deviation or number (%).

MPLA, multiport laparoscopic appendectomy; SPLA, single-port laparoscopic appendectomy; SSI, surgical site infection.

**Table 4.** Assessment of the pain after taking appendectomy

Variable	MPLA group (n = 51)	SPLA group (n = 47)	p-value
VAS score			
After 6 hr	3.73 ± 1.55	3.71 ± 1.95	0.968
After 12 hr	3.46 ± 1.49	3.28 ± 1.50	0.547
After 24 hr	2.88 ± 1.37	3.30 ± 1.49	0.182
Analgesics use			
On POD 0	1.67 ± 0.93	1.23 ± 0.70	0.011
On POD 1	0.90 ± 1.02	0.98 ± 1.19	0.734

Values are presented as mean ± standard deviation.

MPLA, multiport laparoscopic appendectomy; SPLA, single-port laparoscopic appendectomy; VAS, visual analog scale; POD, postoperative day.

**Table 5.** Patient Scar Assessment Questionnaire scores at 6 weeks postoperatively

Variable	MPLA group (n = 51)	SPLA group (n = 47)	p-value
Appearance	21.1 ± 49.5	17.4 ± 5.2	0.001
Consciousness	11.1 ± 3.8	9.2 ± 3.8	0.020
Satisfaction with appearance	14.1 ± 3.7	13.3 ± 4.2	0.364
Satisfaction with symptoms	9.7 ± 3.3	9.5 ± 3.3	0.768
Total	57.7 ± 15.7	49.4 ± 49.3	0.047

Values are presented as mean ± standard deviation.

MPLA, multiport laparoscopic appendectomy; SPLA, single-port laparoscopic appendectomy.

### Patient Scar Assessment Questionnaire scores at 6 weeks postoperatively

The comparison of PSAQ ratings at 6 weeks postoperatively between the two groups is presented in Table 5. The PSAQ scores revealed that the SPLA group performed better than the MPLA group in terms of total score (49.4 vs. 57.7,  $p = 0.047$ ). Statistically significant changes were reported for the appearance and consciousness subitems of the questionnaire ( $p = 0.001$  and  $p = 0.020$ , respectively), but not for the satisfaction with appearance and symptoms subitems ( $p = 0.364$  and  $p = 0.768$ , respectively).

## DISCUSSION

In this prospective randomized trial, our evaluation of body image perception and satisfaction showed superior outcomes with the SPLA than with MPLA at the 6-week follow-up visits, although satisfaction with the scar was comparable between the two techniques. Additionally, our findings demonstrate the technical feasibility and safety of SPLA. The SPLA group required significantly shorter operative times and fewer analgesics on the day of surgery. These results demonstrate that SPLA can be used alongside MPLA as a standard treatment option for acute appendicitis.

Recent studies between MPLA and SPLA have revealed divergent results regarding operation time. Some studies demonstrated a longer duration of SPLA operation [12,13], whereas others showed similar outcomes between two groups [14,15]. In this study, MPLA operation times were significantly longer than SPLA operation times (60 minutes vs. 47.5 minutes). Port insertion time was significantly shorter in the SPLA group, as the method of using the natural orifice as the port insertion site made pneumoperitoneum easy to achieve without the need for additional port insertions in other quadrants. We did not require the use of endo-bag and the specimen was extracted through

the single incision site during the SPLA, which could reduce the operation time.

In general, postoperative pain is typically caused by muscle and parietal peritoneum trauma [16,17]. Since no trocar is inserted through the muscle, patients undergoing SPLA are expected to experience less pain than those undergoing MPLA [18,19]. Jategaonkar and Yadav [19] and Kye et al. [15] demonstrated that pain scores on days 0 and 1 were considerably lower in the SPLA group. The other study, however, found considerably higher pain levels in the first 24 hours after SPLA [13]. In that study, the authors believed that a longer fascia incision in the umbilicus caused the higher pain associated with the single-port technique. In our study, the SPLA group used significantly fewer analgesics on the day of surgery, although postoperative VAS scores and the number of analgesics used on the next day after surgery were not statistically different between the two groups.

Regarding postoperative complications, SSI rate was clearly decreased in laparoscopic approach compared to open method in previous studies [20,21]. SPLA was associated with a higher incidence of wound complications in the umbilicus, although the effect of SPLA on SSI is controversial. One study revealed a wound infection rate of 8% with SPLA and 5% for the standard three-port approach, although there was no significant difference between the two approaches [22]. St Peter et al. [23] reported 3.3% and 1.7% wound infection rates for SPLA and MPLA. In our study, there was lower SSI rate in SPLA group than MPLA group, although there was no significant difference. We think that re-cleansing the everted umbilicus with betadine after surgical draping is important for preventing SSI in SPLA.

The cosmetic result of postoperative scarring is an essential aspect of postoperative quality of life, particularly for patients with benign abdominal illnesses. Recently, not only benign but also malignant disorders have been the subject of intensive

study on cosmetic results [24]. Using the body image questionnaire and cosmetic appearance scale, Carter et al. [14] reported that after 6 months, the SPLA and MPLA groups had similar cosmetic effects. On the other hand, Jategaonkar and Yadav [19] demonstrated favorable cosmetic outcomes in the SPLA group using the easy-to-use scar grade, which was based on patients' subjective feelings on their postoperative scars (1 = thrilled, 2 = happy, 3 = unconcerned, 4 = sad). In the current study, patients who underwent SPLA reported better cosmetic outcomes in the appearance and consciousness subitems and total score than outcomes of MPLA group, although patients' satisfaction with the appearance and consciousness subitems of their scars did not differ significantly. We think that a positive perception of a postoperative scar can have a positive effect on postoperative quality of life, although we do not have data on the association between cosmesis and postoperative quality of life in this study.

Our study is limited by small sample size and lack of long-term cosmetic effects. In addition, PSAQ relies on the subjective thoughts of the patient. Further research is required to compare the cosmetic outcome and pain assessment of SPLA with MPLA using more objective measures.

In conclusion, the postoperative scar evaluated by the patient was better with SPLA than with MPLA, and patient satisfaction with the scar was comparable between the two techniques.

## NOTES

### Ethical statements

A study proposal was finalized and approved by our Institutional Review Board of the Keimyung University Dongsan Medical Center (No. 2014-06-026). Written informed consent was obtained from all patients prior to any study-specific screening procedures.

### Authors' contributions

Conceptualization, Formal analysis, Methodology: KEK, SUB

Writing—original draft: KEK, SUB

Writing—review & editing: ISC, WKJ, SKB, HJK

All authors read and approved the final manuscript.

### Conflict of interest

All authors have no conflicts of interest to declare.

### Funding/support

None.

## ORCID

Kyeong Eui Kim, <https://orcid.org/0000-0001-9984-9976>

In Soo Cho, <https://orcid.org/0000-0002-0086-3493>

Sung Uk Bae, <https://orcid.org/0000-0002-7876-4196>

Woon Kyung Jeong, <https://orcid.org/0000-0001-8421-218X>

Seong Kyu Baek, <https://orcid.org/0000-0001-6427-8675>

Hyung Jin Kim, <https://orcid.org/0000-0002-6315-714X>

## REFERENCES

1. Bae SU, Yang CS, Kim S, et al. Long-term oncologic outcomes of laparoscopic versus open resection following stent insertion for obstructing colon cancer: a multi-center retrospective study. *Surg Endosc* 2019;33:3937-3944.
2. Bae SU, Saklani AP, Lim DR, et al. Laparoscopic-assisted versus open complete mesocolic excision and central vascular ligation for right-sided colon cancer. *Ann Surg Oncol* 2014;21:2288-2294.
3. Semm K. Endoscopic appendectomy. *Endoscopy* 1983;15:59-64.
4. Mentula P, Sammalkorpi H, Leppäniemi A. Laparoscopic surgery or conservative treatment for appendiceal abscess in adults? A randomized controlled trial. *Ann Surg* 2015;262:237-242.
5. Bae SU, Jeong WK, Baek SK. Single-port laparoscopic interval appendectomy for perforated appendicitis with a periappendiceal abscess. *Ann Coloproctol* 2016;32:105-110.
6. Bae SU, Jeong WK, Baek SK. Single-port laparoscopic complete mesocolic excision and central vascular ligation for caecal cancer with apical lymph node metastasis: a video vignette. *Colorectal Dis* 2018;20:643-644.
7. Lee YS, Kim JH, Kim HJ, et al. Short-term outcomes of single-port versus multiport laparoscopic surgery for colon cancer: the SIMPLE multicenter randomized clinical trial. *Ann Surg* 2021;273:217-223.
8. Esposito C. One-trocar appendectomy in pediatric surgery. *Surg Endosc* 1998;12:177-178.
9. Cardinali L, Mazzetti CH, Cadenas Febres A, Repullo D, Bruyns J, Dapri G. Prospective randomized study comparing single-incision laparoscopic versus multi-trocar laparoscopic totally extraperitoneal (TEP) inguinal hernia repair at 2 years. *Surg Endosc* 2018;32:3262-3272.
10. Yang JJ, Seo M, Oh HK, et al. Surgical outcomes of single-port laparoscopic surgery compared with conventional laparoscopic surgery for appendiceal mucinous neoplasm.



- Ann Coloproctol 2021;37:239-243.
11. Gasior AC, Knott EM, Holcomb GW 3rd, Ostlie DJ, St Peter SD. Patient and parental scar assessment after single incision versus standard 3-port laparoscopic appendectomy: long-term follow-up from a prospective randomized trial. *J Pediatr Surg* 2014;49:120-122.
  12. Vidal O, Valentini M, Ginestà C, et al. Laparoendoscopic single-site surgery appendectomy. *Surg Endosc* 2010;24:686-691.
  13. Park JH, Hyun KH, Park CH, et al. Laparoscopic vs transumbilical single-port laparoscopic appendectomy; results of prospective randomized trial. *J Korean Surg Soc* 2010;78:213-218.
  14. Carter JT, Kaplan JA, Nguyen JN, Lin MY, Rogers SJ, Harris HW. A prospective, randomized controlled trial of single-incision laparoscopic vs conventional 3-port laparoscopic appendectomy for treatment of acute appendicitis. *J Am Coll Surg* 2014;218:950-959.
  15. Kye BH, Lee J, Kim W, Kim D, Lee D. Comparative study between single-incision and three-port laparoscopic appendectomy: a prospective randomized trial. *J Laparoendosc Adv Surg Tech A* 2013;23:431-436.
  16. Chouillard E, Dache A, Torcivia A, Helmy N, Ruseykin I, Gumbs A. Single-incision laparoscopic appendectomy for acute appendicitis: a preliminary experience. *Surg Endosc* 2010;24:1861-1865.
  17. Jeong H. The effort to reduce vasovagal reaction and abdominal pain during stapled hemorrhoidopexy. *Ann Coloproctol* 2020;36:291-292.
  18. Kim WJ, Jin HY, Lee H, et al. Comparing the postoperative outcomes of single-incision laparoscopic appendectomy and three port appendectomy with enhanced recovery after surgery protocol for acute appendicitis: a propensity score matching analysis. *Ann Coloproctol* 2021;37:232-238.
  19. Jategaonkar PA, Yadav SP. Single site multiport umbilical laparoscopic appendectomy versus conventional multiport laparoscopic appendectomy in acute settings. *Ann R Coll Surg Engl* 2014;96:452-457.
  20. Biondi A, Di Stefano C, Ferrara F, Bellia A, Vacante M, Piazza L. Laparoscopic versus open appendectomy: a retrospective cohort study assessing outcomes and cost-effectiveness. *World J Emerg Surg* 2016;11:44.
  21. Takami T, Yamaguchi T, Yoshitake H, et al. A clinical comparison of laparoscopic versus open appendectomy for the treatment of complicated appendicitis: historical cohort study. *Eur J Trauma Emerg Surg* 2020;46:847-851.
  22. Teoh AY, Chiu PW, Wong TC, et al. A double-blinded randomized controlled trial of laparoendoscopic single-site access versus conventional 3-port appendectomy. *Ann Surg* 2012;256:909-914.
  23. St Peter SD, Adibe OO, Juang D, et al. Single incision versus standard 3-port laparoscopic appendectomy: a prospective randomized trial. *Ann Surg* 2011;254:586-590.
  24. Bae SU, Jegon WK, Baek SK. Single plus one-port robotic surgery using the da Vinci Single-Site Platform versus conventional multi-port laparoscopic surgery for left-sided colon cancer. *Wideochir Inne Tech Maloinwazyjne* 2022;17:179-187.