

Fibrosis by Cyanate via TGF- β in the Peritoneum of Rats

Mi Young Yeo, M.D., Kyo Cheol Mun, M.D., Eun Ju Chang, Ph.D., Hye Jung Choi, M.S.,
Sang Pyo Kim, M.D., Nam Hyuk Lee, M.D.*, Yu Hyun Kim, B.S.,
Chun Sik Kwak, Ph.D., Hyun Chul Kim, M.D.

Dongsan Kidney Institute, Keimyung University, Daegu, Korea
Department of Surgery, Yeungnam University Colledge of Medicine, Daegu, Korea*

Abstract : During peritoneal dialysis, the peritoneum is exposed to waste products including urea. Urea is converted to spontaneously cyanate at physiological body temperature and pH, and cyanate carbamylates amino acids, peptides, and proteins. Our previous experiment, showed that cyanate from urea can induce chronic inflammation in the peritoneum. This experiment was undertaken to find out whether cyanate can stimulate transforming growth factor (TGF)- β , thus resulting in the biosynthesis of collagen in the peritoneum. Experiments were performed on two groups of seven rats each. In cyanate-treated group, each rat intraperitoneally received 1 mL of 1.5 μ M potassium cyanate dissolved in 40 mM sodium bicarbonate solution everyday. In control group, each rat received 1 mL of 1.5 μ M potassium bicarbonate instead of potassium cyanate. All the rats were sacrificed on the 85th day after the 1st injection. The tissue samples were stained with Masson's trichrome, and also stained for TGF- β . In the control group, a single layer of flattening mesothelial cells and thin layer of collagen with a few fibroblasts were seen, and there were positive reactions for TGF- β in the mesothelial cells and a few submesothelial fibrocytes. In the cyanate-treated group, partly sloughing off mesothelial cells, increased submesothelial collagen layers, many fibroblasts in the submesothelial space, and many TGF- β positive fibroblasts among the submesothelial collagen layers were shown. These results indicate that cyanate can induce fibrosis via stimulation of TGF- β in the peritoneum.

Key Words : Collagen, Cyanate, Peritoneal dialysis, TGF- β

Introduction

Peritoneal fibrosis is one of the most common morphological changes observed in

continuous ambulatory peritoneal dialysis patients [1,2]. Long-term exposure of the peritoneum to several factors including dialysis solutions containing high concentration of

glucose contributes to peritoneal injury [3–5]. The peritoneum is also exposed to the waste products including urea during peritoneal dialysis.

In aqueous solution, there is partial and spontaneous decomposition of urea to ammonia, carbonate, and cyanate [6]. Cyanate then subsequently reacts irreversibly with the N-terminal groups of amino acids, peptides, and many proteins by a process known as carbamylation [7–9]. Under physiological pH and body temperature conditions, 0.8% of the molar concentration of urea is spontaneously converted to cyanate at equilibrium [10]. In chronic renal failure and end stage renal diseases, proteins are known to be easily carbamylated as a result of reactions with urea-derived high levels of cyanate concentration [8–13].

Peritoneum is always exposed to the urea which forms cyanate spontaneously [6] during peritoneal dialysis. And according to our previous experiment [14], cyanate from urea can induce chronic inflammation in the peritoneum. This experiment was done to know whether cyanate can stimulate transforming growth factor (TGF)- β , and thus results in the biosynthesis of collagen in the peritoneum.

Materials & Methods

1. Reagents

Potassium cyanate with 97% purity, was purchased from Acros Organics (Fair Lawn, NJ, USA). Sodium bicarbonate and potassium bicarbonate were purchased from Sigma (St Louis, MO, USA). Formalin was purchased from Yakuri Pure Chemicals (Osaka, Japan). The

other chemicals were of the highest purity commercially available.

2. Animals

Fourteen male rats of the Sprague–Dawley strain, weighing between 280 and 320 g were used in this experiment. All animals were fed on a standard rat chow and water ad libitum and kept in a temperature controlled environment (20 to 22°C) with an alternating cycle of 12 hour light and dark. All animals were maintained on commercial pellets purchased from Sam Yang Food Co. (Wonju, Korea). The care of the animals is consistent with the NIH Guides for the Care and Use of Laboratory Animals.

Experiments were performed on two groups. In cyanate-treated group with seven rats, each rats received 1 mL of 1.5 μ M potassium cyanate dissolved in 40 mM sodium bicarbonate solution everyday intraperitoneally for 12 weeks. In control group with seven rats, each rats received 1 mL of 1.5 μ M potassium bicarbonate dissolved in 40 mM sodium bicarbonate solution intraperitoneally everyday. To avoid accidental infection during injection, shaving area of the abdomen was wiped with 70% ethanol and dried with sterile gauze before intraperitoneal injection. Rats were anesthetized with ether and sacrificed at 85th day after the first injection.

3. Histopathological preparation

After formalin fixation, the tissue samples from abdominal walls and livers were sliced, embedded in a standard manner and stained with hematoxylin and eosin.

All peritoneum were fixed in 10% neutral formalin for 72 hr and processed routinely for Masson's trichrome stain. The immunohisto

-chemistry was performed using avidin-biotin-peroxidase complex method. Formalin-fixed, paraffin-embedded sections were rehydrated and incubated overnight at 4°C with the diluted anti-TGF- β antibody, And then biotinylated anti-mouse and rabbit IgG (DAKO Corporation, Carpinteria, CA, USA), and a complex of peroxidase conjugated streptoavidin (DAKO Corporation, Carpinteria, CA, USA) were added (ABC method). They were reacted with 3,3'-diaminobenzidine tetrahydrochloride-H₂O₂ and then counterstained with hematoxylin.

Results

In control group, a single layer of flattening mesothelial cells and thin layer of collagen with a few fibroblasts were shown (Fig. 1), and there were positive reactions for TGF- β in the mesothelial cells and a few submesothelial fibroblasts (Fig. 2).

In cyanate-treated group, partly sloughing off mesothelial cells, increased submesothelial collagen layers, many fibroblasts in the

submesothelial space (Fig. 1), and many TGF- β positive fibroblasts among the submesothelial collagen layers were shown (Fig. 2).

Discussion

In patients with long-term peritoneal dialysis, various pathological changes such as denudation of peritoneal mesothelial cells, duplication of submesothelial and/or capillary basement membranes, submesothelial fibrin deposit, and peritoneal fibrosis have been reported [5]. The precise etiology of these changes remains unclear and may very well prove to be multifactorial. Although long-term exposure to any commercial PD fluid with different components leads to mesothelial cell damage, submesothelial fibrosis, and neoangiogenesis [15], the alterations in the peritoneal membrane are probably mainly caused by the continuous exposure to dialysis fluids which are acidic, hypertonic, and contain high concentrations of glucose and lactate, and is contaminated with bio-incompatible plastic

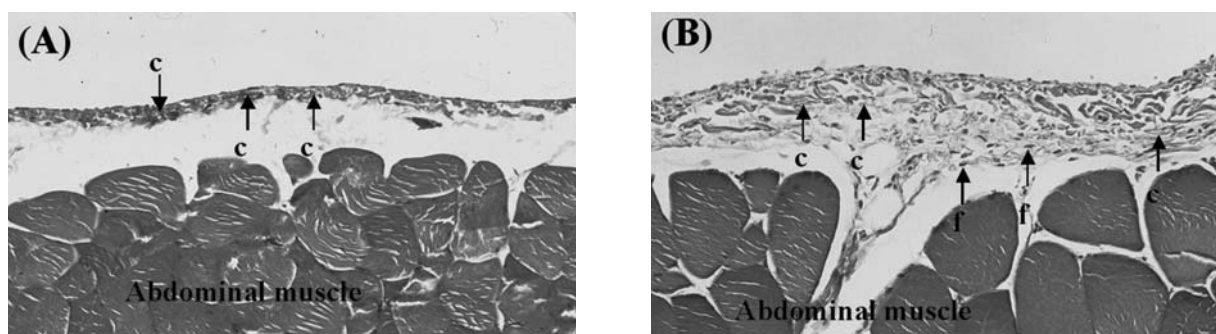


Fig. 1. Trichrome staining in the parietal peritoneum ($\times 100$). A (control group): 1 mL of 1.5 μ M potassium bicarbonate dissolved in 40 mM sodium bicarbonate solution was injected intraperitoneally. Note a single layer of flattening mesothelial cells and thin layer of collagen (c) with a few fibroblasts in control group. B (cyanate-treated group): 1 mL of 1.5 μ M potassium cyanate dissolved in 40 mM sodium bicarbonate solution was injected intraperitoneally. Note partly sloughing off mesothelial cells, increased submesothelial collagen (c) layers and many fibroblasts (f) in the submesothelial space of the cyanate-treated group.

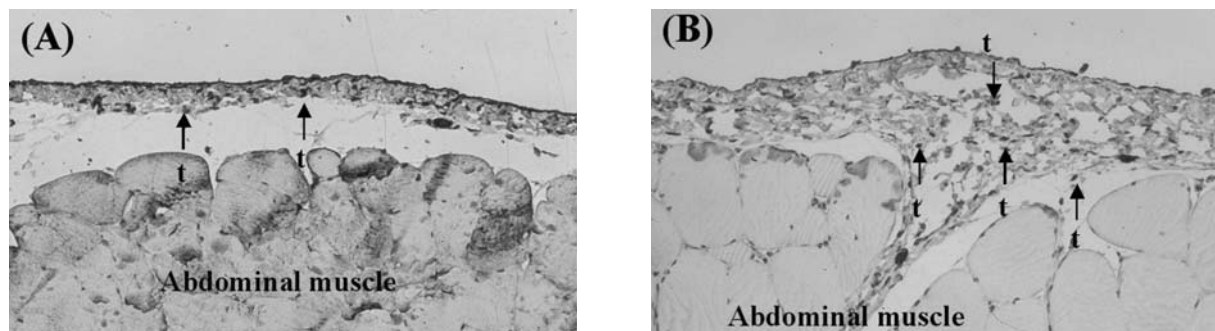


Fig. 2. TGF- β expression in the parietal peritoneum. A (control group): 1 mL of 1.5 μ M potassium bicarbonate dissolved in 40 mM sodium bicarbonate solution was injected intraperitoneally. Note positive immunoreactivity for TGF- β (t) in the mesothelial cells and a few submesothelial fibroblasts in the control group. B (cyanate group); 1 mL of 1.5 μ M potassium cyanate dissolved in 40 mM sodium bicarbonate solution was injected. Note many TGF- β positive fibroblasts (t) among the submesothelial collagen layers in the cyanate-treated group. ABC method, $\times 100$.

degradation products, and contain oxidant agents [3–5,16]. Among the several uremic toxins, cyanate from urea can carbamylate amino acids, peptides, and proteins [7–9].

Under physiological conditions, 0.8% of the molar concentration of urea is converted to cyanate at equilibrium *in vivo* [10]. Cyanate can react with proteins and carbamylates proteins including hemoglobin [8,11,12]. In chronic renal failure or end stage renal failure, proteins are carbamylated as a result of reactions with cyanate [8–13]. Cyanate may also carbamylate the proteins in the peritoneum. Because of this alteration, cyanate is known to contribute to peritoneal injury with morphological changes. In our previous paper [14], injection of cyanate showed early or mild advanced chronic inflammation in the peritoneum. This experiment was done to know whether cyanate can stimulate TGF- β , and thus result in the biosynthesis of collagen in the peritoneum.

Functional failure of the peritoneal membrane is the most serious problem in long-term continuous ambulatory peritoneal dialysis [1,2]. TGF- β is one of the key mediators of fibrosis in

some organs, and is thought to be involved in peritoneal alterations [2]. Although the cellular mechanisms explaining the stimulatory effects of cyanate on TGF- β in this study remain to be elucidated, the injection of cyanate caused the increased submesothelial collagen layers, the increased numbers of fibroblasts in the submesothelial space, and the increased numbers of TGF- β positive fibroblasts among the submesothelial collagen layers.

The results in this experiment suggest that cyanate may stimulate TGF- β , thus induces collagen synthesis in the peritoneum.

Summary

The peritoneum is exposed to the waste products including urea during peritoneal dialysis. Urea forms cyanate spontaneously at physiological body temperature and pH, and cyanate carbamylates amino acids, peptides, and proteins. According to our previous experiment, cyanate from urea can induce chronic inflammation in the peritoneum. This experiment

was done to know whether cyanate can stimulate transforming growth factor (TGF)- β , and thus result in the biosynthesis of collagen in the peritoneum. Experiments were performed on two groups. In cyanate-treated group, each rats received 1 mL of 1.5 μ M potassium cyanate dissolved in 40 mM sodium bicarbonate solution everyday intraperitoneally. In control group, each rats received 1 mL of 1.5 μ M potassium bicarbonate instead of potassium cyanate. Each group with seven rats was sacrificed at the 85th day after the 1st injection. The tissue samples were stained with Masson's trichome, and stained for TGF- β . In control group, a single layer of flattening mesothelial cells and thin layer of collagen with a few fibroblasts were shown. And there were positive reactions for TGF- β in the mesothelial cells and a few submesothelial fibrocytes in control group. In cyanate group, partly sloughing off mesothelial cells, increased submesothelial collagen layers, many fibroblasts in the submesothelial space, and many TGF- β positive fibroblasts among the submesothelial collagen layers were shown. These results indicate that cyanate can induce fibrosis via stimulation of TGF- β in the peritoneum.

References

1. Jimenez-Heffernan JA, Aguilera A, Aroeira LS, Lara-Pezzi E, Bajo MA, del Peso G, *et al.* Immunohistochemical characterization of fibroblast subpopulations in normal peritoneal tissue and in peritoneal dialysis-induced fibrosis. *Virchows Arch* 2004;**444**(3):247-56.
2. Naiki Y, Maeda Y, Matsuo K, Yonekawa S, Sakaguchi M, Iwamoto I, *et al.* Involvement of TGF-beta signal for peritoneal sclerosing in continuous ambulatory peritoneal dialysis. *J Nephrol* 2003;**16**(1):95-102.
3. Krediet RT. Advances in peritoneal dialysis: towards improved efficacy and safety. *Blood Purif* 1998;**16**(1):1-14.
4. Krediet RT. Prevention and treatment of peritoneal dialysis membrane failure. *Adv Renal Replace Ther* 1998;**5**(3):212-7.
5. Park MS. Factors increasing severity of peritonitis in long-term peritoneal dialysis patients. *Adv Renal Replace Ther* 1998;**5**(3):185-93.
6. Marier JR, Rose D. Determination of cyanate, a study of its accumulation in aqueous solutions of urea. *Anal Biochem* 1964;**7**:304-14.
7. Knochel JP, Seldin DW. The pathophysiology of uremia. In: Brenner BM, Rector FC, editors. *The Kidney*. Philadelphia: Saunders; 1976, p.1448-85.
8. Fluckiger R, Harmon W, Meier W, Gabbay KH. Hemoglobin carbamylation in uremia. *N Engl J Med* 1981;**304**(14):823-7.
9. Kraus LM, Jones MR, Kraus AP Jr. Essential carbamoyl-amino acids formed *in vivo* in patients with end-stage renal disease managed by continuous ambulatory peritoneal dialysis: isolation, identification, and quantitation. *J Lab Clin Med* 1998;**131**(5):425-31.
10. Roxborough HE, Millar CA, McEneny J, Young IS. Carbamylation inhibits the ferroxidase activity of caeruloplasmin. *Biochem Biophys Res Commun* 1995;**214**(3):1073-8.
11. Stim J, Shaykh M, Anwar F, Ansari A, Arruda JAL, Dunea G. Factors determining hemoglobin carbamylation in renal failure. *Kidney Int* 1995;**48**(5):1605-10.
12. Balion CM, Draisey TF, Thibert RJ. Carbamylated hemoglobin and carbamylated plasma protein in hemodialyzed patients. *Kidney Int* 1998;**53**(2):488-95.
13. Nilsson L, Lundquist P, Kagedal B, Larsson R. Plasma cyanate concentrations in chronic renal failure. *Clin Chem* 1996;**42**(3):482-3.

14. Mun KC, Yeo MY, Kim SP, Kim HC, Kwak CS. Chronic peritoneal inflammation by cyanate in rats. *Perit Dial Int* 2000;**20**(6):699-702.
15. Musi B, Braide M, Carlsson O, Wieslander A, Albrektsson A, Ketteler M, *et al.* Biocompatibility of peritoneal dialysis fluids: long-term exposure of nonuremic rats. *Perit Dial Int* 2004;**24**(1):37-47.
16. Gotloib L, Wajsbrot V, Cuperman Y, Shostak A. Acute oxidative stress induces peritoneal hyperpermeability, mesothelial loss, and fibrosis. *J Lab Clin Med* 2004;**143**(1):31-40.