

## The Paradox of Hypertension; a pellet in hypertrophic myocardium

Yun Kyeong Cho, M.D., Hyung Seop Kim, M.D., Hyun Ok Cho, M.D.,  
Chang Wook Nam, M.D., Seong Wook Han, M.D., Seung Ho Hur, M.D.,  
Yoon Nyun Kim, M.D., Kwon Bae Kim, M.D.

*Department of Internal Medicine,  
Keimyung University School of Medicine, Daegu, Korea*

**Abstract :** In general, because hypertension is an important risk factor for cardiovascular disorders blood pressure should be adequately controlled. However, paradoxically, untreated hypertension revealed unexpected result in a patient of gunshot wound. A pellet embedded in the left ventricular myocardium did not cause to deteriorate any clinical course and after 1 week, any change in location of the pellet was not noticed on follow-up echocardiography. Herein we report a patient with a retained pellet in the heart who was discharged from hospital without operative therapy.

**Key Words :** Heart, Hypertension, Pellet

### Introduction

Recently there has been an increased incidence of gunshot injuries with increased use of guns in hunting. In general, it is known that all cardiac gunshot injuries demand operative therapies to prevent subsequent complications such as endocarditis, pericarditis, embolization, fistula formation and myocardial damage[1]. However we experienced one patient with gunshot injury in myocardium who was recovered without

surgical management because of the hypertrophic myocardium by long untreated hypertension.

### Case

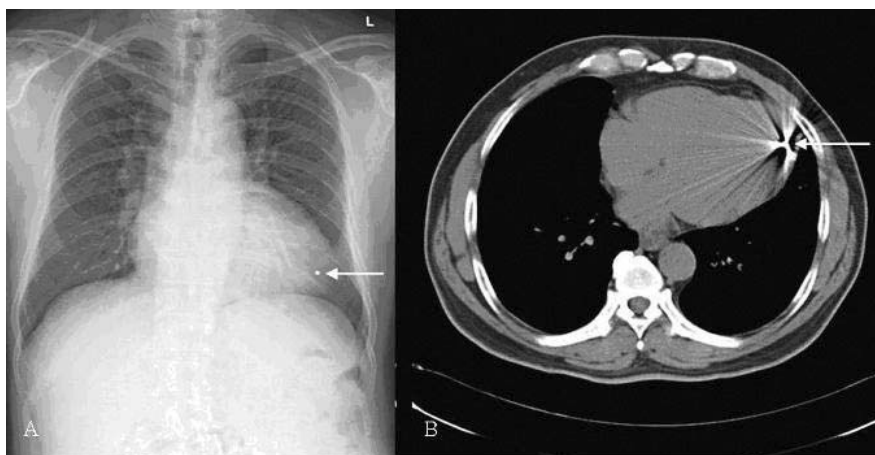
A 69-year-old man, who had history of hypertension for 13 years without treatment, was brought to emergency department after sustaining gunshot wound to face, left anterior chest and right thigh in a hunting accident. On

arrival to emergency department, the patient had no sign of respiratory distress and cardiac murmur with blood pressure of 180/100 mmHg, pulse rate of 98 beats/min, and respiratory rate of 16 breaths/min. In physical examination, he did not show any abnormalities except for 0.5 cm sized wounds over right eyebrow, right submandibular area, left mid-clavicular line at the 9th intercostal space, and medial side of right thigh. Electrocardiography showed a complete bundle branch block and chest radiography showed a small pellet that appeared to be within the heart (Fig. 1A). Chest computed tomography and transthoracic echocardiography revealed the intracardiac location of a pellet embedded in the apico-lateral wall of the left ventricle without pericardial effusion (Fig. 1B). Interestingly, echocardiography showed the pellet located at 1.0 cm below epicardium in the apico-lateral wall, which had thickened and hypertrophied myocardium with the resultant of

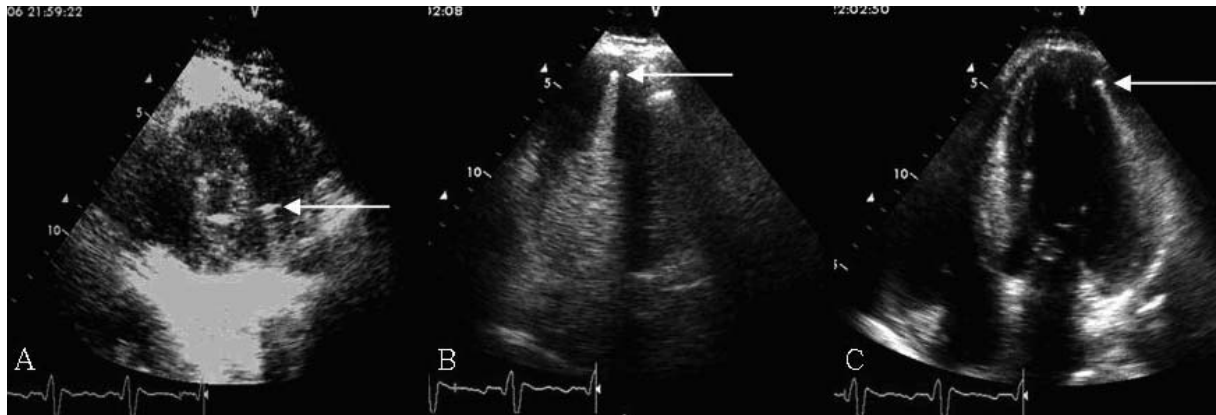
hypertension of long duration (Fig. 2). Because the patient was hemodynamically stable and showed no specific symptom, he was hospitalized in intensive care unit to evaluate the need of surgical intervention. After 1 week, on follow-up echocardiography, any change was not noted in the location of the pellet. Thus, he was discharged without any complication.

## Discussion

Hypertension is one of the most prevalent and powerful contributors to cardiovascular diseases and also contributes to pathogenesis of systolic or diastolic heart failure with increased ventricular mass and impaired filling [2]. In the untreated hypertensive patients, the progressive accumulation of interstitial collagen fibers in ventricular hypertrophy can be expected to cause ventricular dysfunction involving either the



**Fig. 1.** Radiological findings in a patient with gunshot wound in the heart. (A) The chest radiograph shows a round metallic opacity on the left side overlying the cardiac apex. (B) Computed tomographic scan shows intensely bright, metallic density within left ventricular myocardium associated with a stellate pattern of streak artifact.



**Fig. 2.** Echocardiographic findings in the view of parasternal short axis (A), apical 2 (B), and apical 4 (C) chamber showing a bright echogenic density at the apico-lateral wall in the left ventricle.

diastolic or systolic phase. Thus, hypertrophy has been shown to be an independent predictor of cardiovascular events which included new-onset coronary artery disease (myocardial infarction, unstable angina with documentation of ischemic electrocardiographic changes, sudden cardiac death, or coronary revascularization procedure), stroke, transient cerebral ischemic attack, symptomatic aortoiliac occlusive disease verified with angiography, thrombotic occlusion of a retinal artery documented with fluoroangiography, progressive heart failure that required hospitalization, and renal failure that required dialysis[3–5]. However, in the present case, the fortunate part about the gunshot injury to heart is that a pellet was not completely passed through the heart, although he was shot through the chest.

Management options including surgical, percutaneous and conservative therapy should be individualized after the risk evaluation of removal of foreign bodies[6]. Generally the clinical course was excellent except aorto-esophageal fistula, which was induced by

foreign bodies in the esophagus and was life-threatening, but no effective therapy is available now[6]. The proper timing of surgical management of these retained pellets or bullets in the heart was reported to be individualized according to the hemodynamic states such as tamponade or hemothorax[7]. Since Doctor Daniel Williams's first report of the operative management of penetrating injury to the heart in 1893, many authors have advocated operative therapy for all cardiac missile injuries. Fyfe *et al.*[1] advocated the surgical removal of all intracardiac foreign bodies to prevent the subsequent complications of endocarditis, pericarditis, embolization, fistula formation and myocardial damage. But the question remains whether to remove all intracardiac bullets. Symbas *et al.*[8] reported that large, intracavitary and intrapericardial missiles, including even those that were partially embedded in the myocardium, should be removed. Thompson *et al.*[9] suggested nonoperative management of intramyocardial pellet injuries in the stable patient with use of

immediate initial echocardiography to make an accurate diagnosis. They recommended 12 to 24 hour monitoring in the intensive care unit and hospitalization for 3 to 5 days to ensure stability. Repeated echocardiography should be performed before discharge to document the migration of bullets or the progress of pericardial effusion. Echocardiography and electrocardiography should be repeated at 2 weeks and then 3 months after discharge for complete follow-up.

Although there is no regular clinical follow-up after discharge, our limited experience supports expecting a benign clinical course from the retained pellet with no incidence of pericardial tamponade or rhythmic disturbances.

In the present case, it is tempting to speculate that this is a consequence of increased wall thickness from long-standing progression of hypertension without treatment that the pellet could not penetrate the whole myocardium into left ventricular cavity.

## References

1. Fyfe DA, Edgerton JR, Chaikhouni A, Kline CH. Preoperative localization of an intracardiac foreign body by two-dimensional echocardiography. *Am Heart J* 1987;**113**:210-2.
2. Fouad FM, Slominski JM, Tarazi RC. Left ventricular diastolic function in hypertension: relation to left ventricular mass and systolic function. *J Am Coll Cardiol* 1984;**3**:1500-6.
3. Levy D, Garrison RJ, Savage DD, Kannel WB, Castelli WP. Prognostic implications of echocardiographically determined left ventricular mass in the Framingham Heart Study. *N Engl J Med* 1990;**322**:1561-6.
4. Rossi MA. Pathologic fibrosis and connective tissue matrix in left ventricular hypertrophy due to chronic arterial hypertension in humans. *J Hypertens* 1998;**16**:1031-41.
5. Schillaci G, Verdecchia P, Porcellati C, Cuccurullo O, Cosco C, Perticone F. Continuous relation between left ventricular mass and cardiovascular risk in essential hypertension. *Hypertension* 2000;**35**:580-6.
6. Jiang CL, Gu TX, Wang C. Surgical treatment of posttraumatic foreign bodies in the heart or great vessels. *Chin Med J* 2006;**119**:2018-20.
7. Poston RS, Sloane RW Jr., Morgan BR, Smith DC, Smithson JB, Hickey MS. Elective removal of an intramyocardial bullet. *South Med J* 2001;**94**:464-6.
8. Symbas PN, Picone AL, Hatcher CR, Vlais-Hale SE. Cardiac missiles. A review of the literature and personal experience. *Ann Surg* 1990;**211**:639-47.
9. Thompson EC, Block EF, Mancini MC. Management of BB shot wounds to the heart. *J Trauma* 1996;**40**:168-70.