

Urothelial Carcinoma of the Renal Pelvis Mimicking Acute Pyelonephritis with Abscess

Ji Wook Choi, M.D., Il Hwan Ryu¹, M.D., Ki Tae Bang, M.D., Jong Ho Shin, M.D.,
Hye Kyung Lee¹, M.D., Jin Uk Jeong, M.D.

*Department of Internal Medicine, Department of Pathology¹, Eulji University College of Medicine,
Daejeon, Korea*

Abstract

Primary tumors of the renal pelvis and collecting system are relatively uncommon. Their clinical presentation is nonspecific and variable, and they can be mistaken for a variety of conditions, including acute pyelonephritis or renal abscesses. A 75-year-old man have had abdominal pain for one week. He was diagnosed for acute pyelonephritis based on the radiologic findings initially. Repeated abdominal computed tomography was done after 3 months later, because of the relapsed abdominal pain. Abdominal computed tomography revealed lobulated abscess in the left kidney with enlarged central necrotic para-aortic lymph nodes. Laparoscopic excisional biopsy was performed at necrotizing lymph node and the histologic evaluation revealed an urothelial carcinoma. This report presents an unusual case of urothelial carcinoma that initially mimicked acute pyelonephritis but presented as a renal abscess several months later.

Key Words : Pyelonephritis, Renal abscess, Urothelial carcinoma

Introduction

Urothelial tumors involving the renal pelvis and ureter are relatively uncommon and account for approximately 5% of all urologic malignancies [1]. Their clinical presentation is nonspecific and variable, and they can be mistaken for a variety of conditions, including infectious disease. They are sometimes detected in unsuspected cases with

urinary tract symptoms. In our case, there were no definite inflammatory or infective conditions, only radiological findings suggest infective disease and clinical improvement by empirical treatment confusing differential diagnosis. After 3-months later, patient had relapsed abdominal pain and additional evaluation revealed delayed diagnosis for urothelial carcinoma. The initial radiologic evaluation and clinical correlation are therefore

Corresponding Author: Jin Uk Jeong, M.D., Division of Nephrology, Department of Internal Medicine,
Eulji University College of Medicine, 1306 Dunsan-dong, Seo-gu, Daejeon 302-799, Korea
Tel : +82-42-611-3083 E-mail : jjo9428@gmail.com

critical for early detection. The association of renal tumors, particularly urothelial carcinoma, with abscess formation is a rare entity that can lead to misinterpretation on standard imaging procedures. It is important to obtain a correct diagnosis, because therapy for abscess formation differs from that for a malignant tumor. This report presents an unusual case of a 75-year-old man who had urothelial carcinoma that initially mimicked acute pyelonephritis but presented as a renal abscess several months later.

Case Report

A 75-year-old man who have had no specific medical history, except for a recurrent gastric ulcer, presented with a 1-week history of dull left flank pain. He was in apparent good health and in no apparent distress. A systematic review was completely negative, with the exception of left flank pain. Dysuria and gross hematuria were absent. He was neurologically intact, and his lungs were clear. He had no lymphadenopathy, and his abdomen was soft and nontender. He was a nonsmoker. His family history was unremarkable for urogenital cancer. His medications included a proton pump inhibitor. His urinalysis revealed no protein, red blood cells or with blood cells. A repeat urine cytologic examination revealed benign squamous cells with no evidence of malignancy. On admission, his blood pressure was 130/80 mmHg, heart rate was 88 beats/min and body temperature was 36.7 °C. Blood urea nitrogen was 13.4 mg/dl, and serum creatinine was 0.85 mg/dl. The estimated glomerular filtration rate was 100.1 ml/min/1.73 m² using the four-variable Modification of Diet in Renal Disease Study equation. WBC count was $7.0 \times 10^3/l$, and C-reactive protein was 0.5 mg/dl (normal: 0.8

mg/dl). Hemoglobin was 16.3 g/dl, hematocrit was 48.1%, and platelets were 196,000/ μ L. Prothrombin time was 12.0 s, and activated partial thromboplastin time was 38.2 s. Computed tomography revealed left renal pelvis and ureteral wall thickening with enhancement and mild hydronephrosis with multifocal wedge-shaped low enhanced lesions on Lt renal lower pole (Fig. 1).

Oral treatment with ciprofloxacin was administered for a 2-week period based on the radiologic diagnosis of acute pyelonephritis, and clinical improvement was observed. Three months later, the patient developed a relapse of abdominal pain in the left upper quadrant. A repeat abdominal computed tomography revealed an 8.8-cm lobulated abscess with septation in the lower pole of the left kidney, which could have been secondary to acute pyelonephritis (Fig. 2).

However, the irregularly thickened abscess wall with enlarged central necrotic para-aortic lymph nodes showing peripheral rim enhancement, and the absence of fever and elevated inflammatory markers, including C-reactive protein and white blood count, were believed to indicate malignancy or tuberculosis. Therefore, percutaneous nephrostomy was performed to both drain the abscess and make a diagnosis of the etiology. Approximately 200 ml/day of serosanguineous fluid were drained daily. The microbiologic evaluation of the fluid was negative and a Ziehl-Neelsen staining and a urine culture for tuberculosis were negative. The drained fluid contained 24,000 WBC/mm³, of which 82% were neutrophils. Urine cytologic examination showed many acute inflammatory cells without any cytologic evidence of malignancy. Thus, the patient underwent laparoscopic excisional biopsy of para-aortic lymph nodes for a definite diagnosis. The gross finding of laparoscopic biopsy showed no definite renal mass and about 2cm sized central

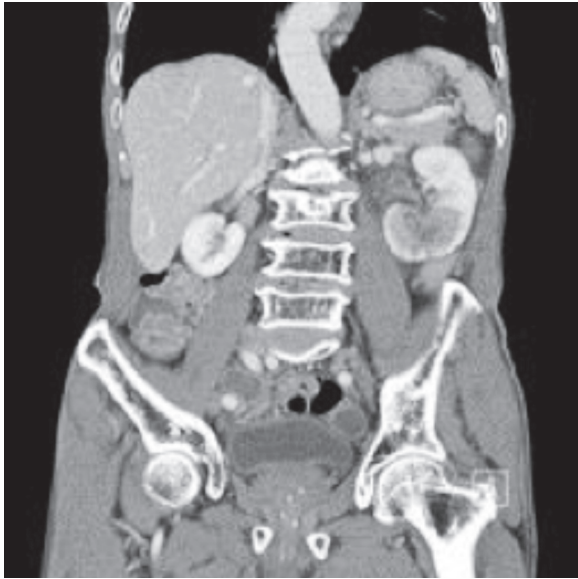

Fig. 1. Initial finding on computed tomography. CT scan revealed left renal pelvis and ureteral wall thickening with enhancement and mild hydronephrosis with multifocal wedge-shaped low enhanced lesions on Lt renal lower pole.

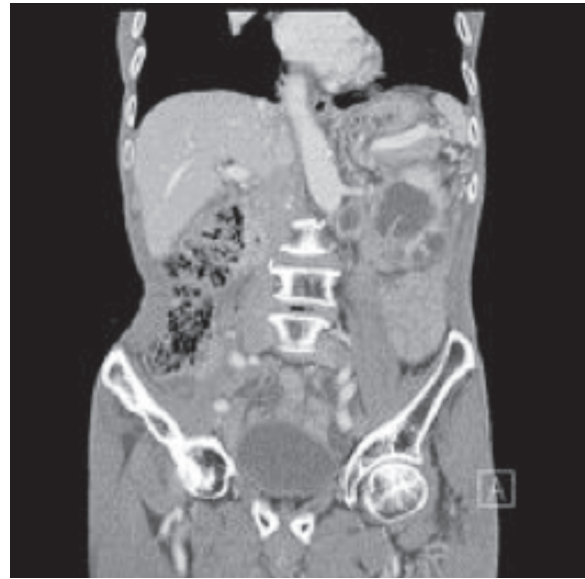

Fig. 2. Later finding on computed tomography. CT scan revealed an 8.8-cm lobulated abscess with septation in the lower pole of the left kidney. No discrete masses were identified in the renal parenchyma.

necrotic para-aortic lymph node at left side of aorta, and renal biopsy was not performed because of easy touch bleeding. Nephroure-terectomy was not underwent because positron emission tomography revealed hypermetabolic lesion suggesting metastasis at the lumbar spine area. The pathologic diagnosis was infiltrating urothelial carcinoma of the renal pelvis (Fig 3, 4).

Discussion

We present a rare case of delayed recognition of infiltrating urethelial carcinoma of the renal pelvis. Three months after the development of dull left flank pain, the patient had urothelial carcinoma that initially mimicked acute pyelonephritis but presented as a renal abscess several months later.

The most common presenting symptom of infiltrating urothelial tumors of the upper urinary

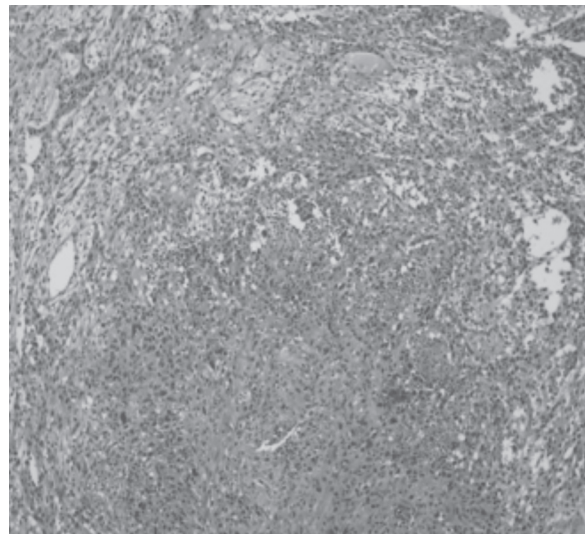


Fig. 3. Poorly differentiated carcinoma with squamoid differentiation in lymph node. The tumor shows ill defined nests reminiscent of high grade urothelial carcinoma. Hematoxylin and eosin stain, original magnification: (×100).

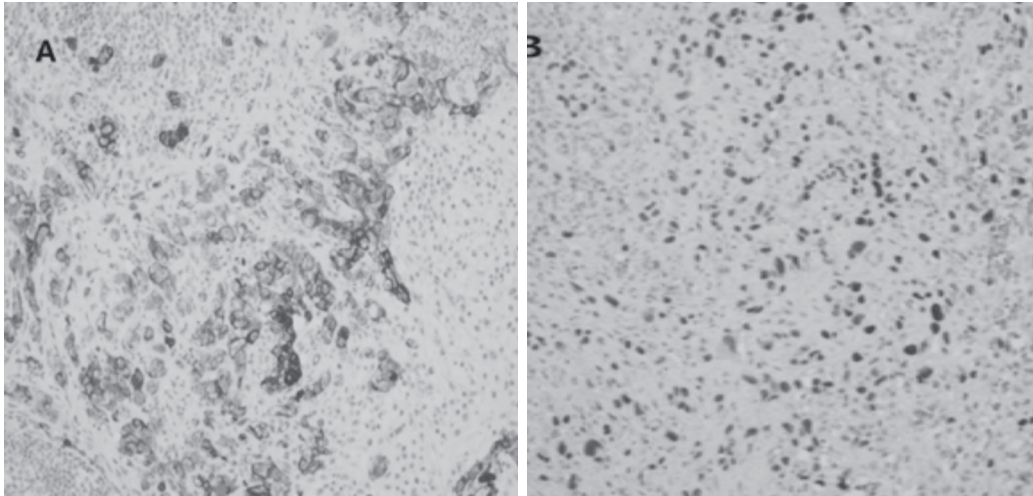


Fig. 4. Immunohistochemical expression of cytokeratin 7 and p63 in the infiltrative urothelial carcinoma tissue. A: Cytokeratin 7 was highly expressed in the cytosol of infiltrating tumor cells. B: p63 was expressed in the nuclei of tumor cells. Original magnification: ($\times 100$).

tract is hematuria, either gross or microscopic [2], which occurs in 56%-98% of patients. Flank pain is the second most common symptom, occurring in 30% of tumors. Our case revealed no hematuria but left flank pain, which led to a delayed diagnosis. This pain is typically dull and believed to be secondary to a gradual onset of obstruction and hydronephrotic distention. Flank pain in patients with tumors of the upper urinary tract does not correlate with either locally advanced tumor stage or a worse prognosis [2].

Radiolucent filling defects, obstruction or incomplete filling of a part of the upper urinary tract, and nonvisualization of the collecting system are the typical findings suggestive of a tumor of the upper urinary tract. Our case revealed no filling defect in the urinary tract. Neither a filling defect of the renal pelvis or hydronephrosis was revealed, which is explained by the predominantly intraparenchymal tumor growth. Although the associations of renal cell carcinoma with a renal or perinephric abscess and obstructing TCC with

pyonephrosis have been well established in published reports [3-6], few cases of urothelial carcinoma of the kidney with renal abscess formation have been reported [7-9].

Cancer may at times be also confused with renal infection on imaging procedures. Leukemia, lymphoma, or Castleman's disease can present as infiltrative processes of the kidneys with or without associated lymphadenopathy. Centrally based renal cell carcinoma, renal medullary carcinoma, and transitional cell carcinoma are also common mimics of pyelonephritis [10].

Our case demonstrates the importance of a physician's suspicion of urothelial cancer, particularly if the presentations of pyelonephritis and a renal abscess are atypical with the absence of fever, no evidence of inflammation in laboratory findings, and the presence of regional lymphadenopathy. In other words, based on imaging modalities, no fever and regional lymphadenopathy may be a crucial clue for the diagnosis of an urothelial cancer of the upper

urinary tract with atypical presentations, which mimicked an infectious condition.

Summary

Infiltrating urothelial carcinoma presents in a variety of ways, including renal or perinephric abscesses. It should be suspected if there are no inflammatory signs or symptoms along with acute pyelonephritis and a renal abscess on various imaging procedures, including CT. In addition, regional lymphadenopathy around the perihilar of the kidney may be a crucial clue for urothelial carcinoma.

References

1. Munoz JJ, Ellison LM. Upper tract urothelial neoplasms: incidence and survival during the last 2 decades. *J Urol* 2000;**164**:1523–5.
2. Sagalowsky AI. Urothelial Tumors of the Upper Urinary Tract and Ureter. In: Kavoussi LR, Novic AC, Patin AW, Peters CA, Wein AJ, editors. *Campbell-Walsh urology* 10th ed. Philadelphia: Saunders; 2012. p. 291–8.
3. Perimenis P. Pyonephrosis and renal abscess associated with kidney tumours. *Br J Urol* 1991;**68**:463–5.
4. Van Poppel H, Vereecken RL, and Wilms G. Bilateral renal cell carcinoma diagnosed as renal abscesses. *Urology* 1985;**25**:548–50.
5. Childs GJ, Pickleman J, Churchill RJ, Cassidy JE, Love L. Renal cell carcinoma complicated by perinephric abscess and colon perforation. *Urol Radiol* 1982;**4**:37–9.
6. Chintapalli K, Lawson TL, Foley DW, Berland LL. Perinephric abscess with renal cell carcinoma. *Urol Radiol* 1981;**3**:113–5.
7. Gillitzer R. Transitional cell carcinoma of the renal pelvis presenting as a renal abscess. *Urology* 2002;**1**:164–6.
8. Lee TY, Ko SF, Wan YL, Cheng YF, Yang WC, Hsieh HH, *et al.* Unusual imaging presentations in renal transitional cell carcinoma. *Acta Radiol* 1997;**38**:1015–9.
9. Salvatierra O Jr, Bucklew WB, and Morrow JW. Perinephric abscess: a report of 71 cases. *J Urol* 1967;**98**:296–302.
10. Demertzis J, Menias CO. State of the art: imaging of renal infections. *Emerg Radiol* 2007;**14**:13–22.