

The Effect of the REM Sleep on Peripheral Vestibular Imbalance

Hyun Ah Kim^{1,2}, M.D., Suh Yun Hong, M.D., Jun Gyu Yang, M.D., Hyon Ah Yi, M.D.,
Hyung Lee^{1,2}, M.D.

*Department of Neurology¹, Brain Research Institute², Keimyung University School of Medicine,
Daegu, Korea*

Abstract

Backgrounds and purpose: While it is known that sleep have influence on emergence of rapid eye movement (REM), namely saccades including fast component of nystagmus, whether spontaneous nystagmus due to vestibular imbalance presents during sleep is still unclear. The purpose of our study was to investigate whether tonic vestibular imbalance appeared as spontaneous nystagmus during the wakeful state could present during REM sleep.

Methods: Overnight polysomnography (PSG) was performed in 7 patients with spontaneous nystagmus due to vestibular neuritis (VN) and 7 controls without dizziness or any nystagmus. The numbers of horizontal saccades were counted, during 3 minutes samples of the alert state before and after the PSG, and the first and last REM sleep.

Results: All patients with VN showed significantly more saccades (fast phases of spontaneous nystagmus) towards the side contralateral to their vestibular lesion in the alert state before and after the PSG compared with control group. By contrast, during REM sleep the patients with VN showed no preponderance in saccade direction ($p < 0.05$). Some brief nystagmoid jerks showed during REM sleep in both patients and controls equally and also had no preponderance in direction.

Conclusions: The tonic vestibular imbalance at peripheral level observed during alert state does not appear at the brainstem level during REM sleep. It is suggested that a de-afferentation of the peripheral vestibular input to the REM sleep generating areas may explain an absence of nystagmus during REM sleep in patients with VN.

Key Words : Nystagmus, REM sleep, vestibular imbalance

Introduction

In animals, the generation of REM is usually explained in terms of ponto-geniculo-occipital (PGO) waves. The cells triggering or transmitting PGO wave may directly excite saccadic burst neurons within paramedian pontine reticular formation and thereby initiate horizontal saccades [1,2]. It is generally considered that the same pontine neurons burst with saccades during the alert state, REMs during REM sleep and fast phases of nystagmus, which are saccades [3–6]. Vestibular neuritis, a common peripheral vestibular syndrome, is characterized by severe vertigo, spontaneous unidirectional nystagmus, and no associated other neurological symptom or sign. In patients with vestibular neuritis (VN), nystagmus is shown during the alert state. But there is no fast eye movement during non-rapid eye movement (NREM) sleep in these patients. Because eye movements during REM sleep are considered to be saccades, nystagmus could also be expected to occur during REM sleep. Thus, we investigated whether spontaneous nystagmus during the alert state in patients with VN also occurs during REM sleep.

Patients and Methods

Overnight polysomnography (PSG) were performed in 7 patients with spontaneous nystagmus (slow phase velocity of at least 10 deg/sec in the dark) due to VN and 7 controls without nystagmus. Diagnosis of VN was based on standard well-accepted criteria [7]. The patients with sleep disorder was chosen as a control group who had no history of

vertigo and no spontaneous nystagmus during the awake state with Frenzel's glasses on. PSG was performed from 0 to 5 days after the onset of symptoms of VN (mean 49 hours, range 11–122 hours). An electrooculogram (EOG) was obtained from electrodes placed lateral to both eyes and to the infraorbital and supraorbital regions. EOG calibration was performed at the beginning of the PSG. Right and left (ipsilateral and contralateral) horizontal saccades were counted separately during 3 minutes samples of the wakeful state before sleep onset, the wakeful state after the nocturnal sleep period, and the first and the last continuous REM episodes of the nocturnal sleep. Horizontal eye movements with an excursion of 3° or more and a velocity of at least 50°/second was only calculated [8]. Any preponderance in saccade direction was considered potential nystagmus. The data were tested between and within the two study groups were compared using the Mann-Whitney U test for paired and independent samples. In the two groups, the numbers of right/ipsilateral and left/contralateral horizontal saccades were compared within awake and REM sections to detect directional preponderance of horizontal saccades and nystagmus. Significance was established at $p < 0.05$.

Results

Patients with VN were older than controls (VN: 62.29 ± 5.68 years, controls: 44.29 ± 19.31 years) and were the same with controls in sex distribution. Vestibular neuritis was located on the right in 5 patients and on the left in 2 patients. Controls were diagnosed as

having obstructive sleep apnea. All patients with VN had spontaneous nystagmus, which was best seen with Frenzel's glasses on. The videotapes showed that all patients and controls lay on their back without turning their heads extensively to the right or left side during the analyzed alert and REM periods. All patients with VN showed significantly more saccades to the side contralateral to their vestibular lesion in the wakeful state, indicating spontaneous nystagmus ($p < 0.05$) (see Table 1, Fig. 1-A). During REM sleep, none of the patients with VN showed either any nystagmus or any significant preponderance in saccade direction. No difference in saccade direction was found in controls during the wakeful state or REM sleep. Some brief duration (2~3 seconds long) of nystagmoid jerks (Fig. 1-B)

or slow horizontal eye movements with velocities between 10 to 20°/second with changing directions equally found with no directional preponderance in both patients with VN and controls during REM sleep. Saccadic eye movements were not found in NREM sleep in both groups.

Discussion

If tonic vestibular imbalance occurred at the peripheral level is successfully transmitted to the medial vestibular nucleus that is known to have an important role producing REM sleep [9,10], any nystagmus or significant preponderance in saccade direction would be observed during REM period in our patients with VN. During REM

Table 1. Saccades during wakefulness and REM sleep of patients with vestibular neuritis and control patients.

	Number of saccades/s	VN	Control	<i>p</i> -value
Initial Wakefulness	Contralateral/Left	0.54 (0.21)	0.04 (0.02)	0.002
	Ipsilateral/Right	0.07 (0.03)	0.04 (0.02)	0.106
	<i>p</i> value	0.002	0.795	
Last Wakefulness	Contralateral/Left	0.66 (0.42)	0.03 (0.02)	0.002
	Ipsilateral/Right	0.11 (0.09)	0.03 (0.02)	0.116
	<i>p</i> value	0.013	0.743	
Initial REM	Contralateral/Left	0.34 (0.32)	0.07 (0.05)	0.040
	Ipsilateral/Right	0.35 (0.39)	0.07 (0.06)	0.029
	<i>p</i> value	0.749	0.948	
Last REM	Contralateral/Left	0.29 (0.26)	0.08 (0.02)	0.017
	Ipsilateral/Right	0.30 (0.22)	0.07 (0.01)	0.012
	<i>p</i> value	0.798	0.646	

Contralateral and ipsilateral refers to the side of the vestibular lesion in patients with vestibular neuritis; right and left refers to controls. VN: vestibular neuritis. Values are given as mean (SD)

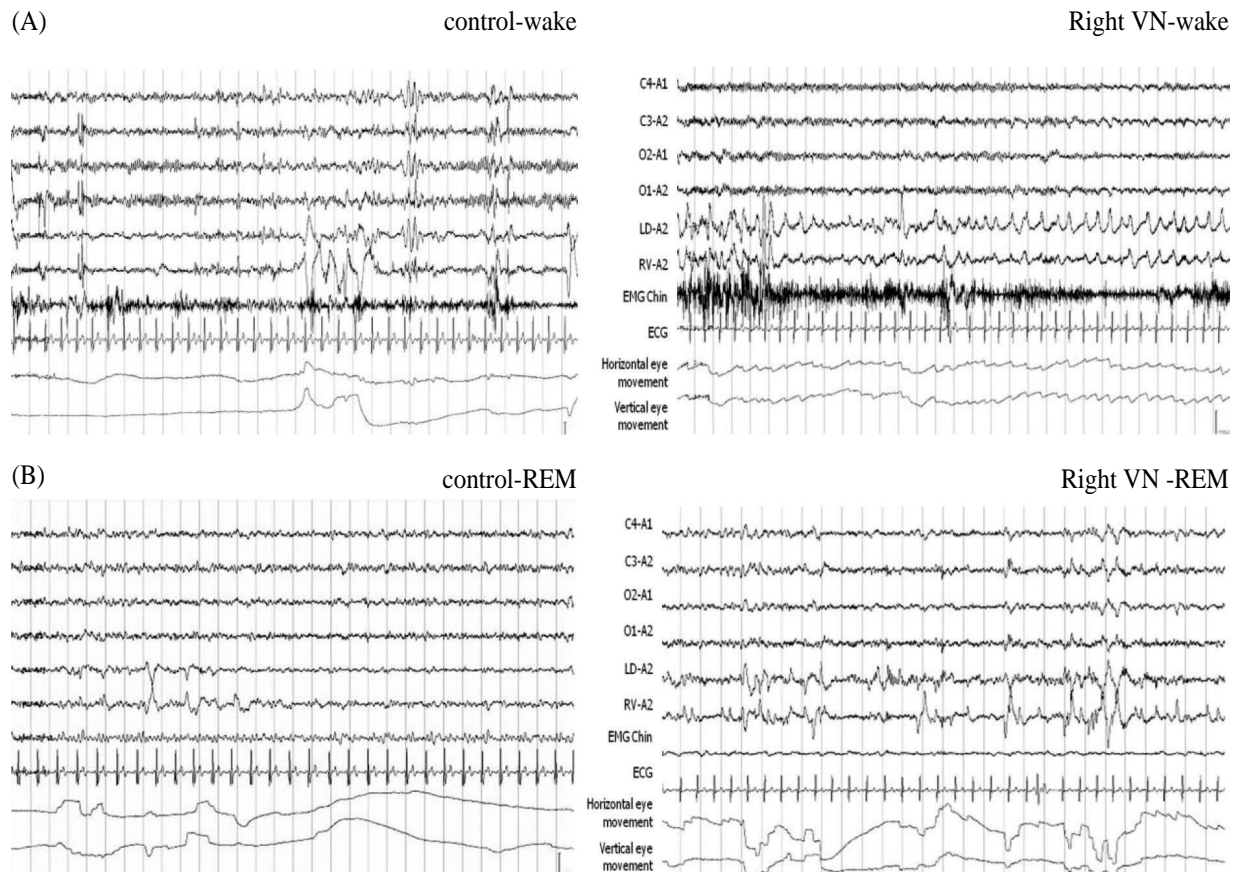


Fig. 1. A. Thirty seconds sample of the alert state before sleep onset of the polysomnography for a control and a patient with right-sided VN. The polysomnography of patient with right-sided VN showed significantly more saccades to the left side in the awake state, indicating spontaneous nystagmus. B. Thirty seconds sample of the first REM period of the polysomnography for a control and a patient with right-sided VN. During the REM sleep, the polysomnography of right-sided VN patient did not show any nystagmus. Some brief duration (2~3 seconds long) of nystagmoid jerks equally found with in both patient with VN and control during REM sleep (arrows). VN: vestibular neuritis.

sleep, however, none of the patients with VN showed either any nystagmus or significant preponderance in saccade direction, which suggested that the tonic vestibular imbalance at peripheral level due to VN during wake state was not active at the brainstem level during REM period. This also indicated that the neuronal discharges related to REM during desynchronized sleep are not influenced by mechanism producing nystagmus in VN.

In NREM sleep, so called quiet sleep or

synchronized sleep, there is no rapid eye movement. Several reports have shown that spontaneous nystagmus during wakefulness due to peripheral or central lesions were completely abolished during NREM sleep [11–16]. We also found the absence of nystagmus during NREM sleep in VN. During REM sleep, it has been reported that spontaneous nystagmus due to a unilateral labyrinthectomy during wakefulness was largely depressed or completely abolished in

cats [11], which is in agreement with our result. However, human studies investigating eye movements during REM sleep of patients with nystagmus in the alert state due to CNS lesion have reported contradictory findings. Previous studies reported that the nystagmus generated by CNS lesions in the alert state disappeared during REM sleep [12,13]. By contrast, other studies described brief phases of nystagmoid jerks during REM sleep in patients with nystagmus in the alert state due to CNS lesions [14,15]. However, these nystagmoid jerks have also been described in healthy subjects [13]. We also found brief nystagmoid jerks that had no directional preponderance in patients and controls. These nystagmoid jerks may be normal findings during REM sleep. This discrepant finding are probably explained by 1) the different definition on suppression of rapid eye movement (i.e., loss of both nystagmus and nystagmoid jerk or only nystagmoid jerk), 2) poor description of direction and pattern of nystagmus, and 3) no description of lesions producing nystagmus.

The neurophysiological basis for disappearance of nystagmus during REM sleep in our patients with VN is still unclear. Like motor atonia presumably due to deafferentation of the motor output during REM sleep, it might be reasonably assumed that there is a deafferentation of the peripheral vestibular input to the REM sleep generating areas including saccadic burst neurons, which may inhibit peripheral input to the medial vestibular nucleus. Neurons in the medial vestibular nucleus have discharge that is synchronized with the rapid eye movements during REM sleep [9,10]. Previous reports on the influence of vestibular stimulation on eye

movements during sleep in normal subjects have also shown similar results that vestibuloocular reflex or optokinetic nystagmus was not elicited during REM sleep [17,18]. It can also be explained as deafferentation of the peripheral vestibular input.

Our study was limited in that the number of both groups was relatively small and age in both groups was not similar. Also controls was not normal but had obstructive sleep apnea that may have REM sleep changes. A further study including both a large number of patients with peripheral or central nystagmus and controls with no sleep disorder is required to confirm these findings.

References

1. Hobson JA, McCarley RW. The brain as a dream state generator: an activation-synthesis hypothesis of the dream process. *Am J Psychiatry* 1977;**134**:1335-48.
2. Hobson JA, Pace-Schott EF, Stickgold R. Dreaming and the brain: toward a cognitive neuroscience of conscious states. *Behav Brain Sci* 2000;**23**:793-842.
3. Hoshino K, Pompeiano O, Magherini PC, Mergner T. The oscillatory system responsible for the oculomotor activity during the bursts of REM. *Arch Ital Biol* 1976;**114**:278-309.
4. Kamogawa H, Ohki Y, Shimazu H, Suzuki I, Yamashita M. Inhibitory input to pause neurons from pontine burst neuron area in the cat. *Neurosci Lett* 1996;**203**:163-6.
5. Bizzi E, Pompeiano O, Somogyi I. Vestibular nuclei: activity of single neurons during natural sleep and wakefulness. *Science* 1964;**145**:414-5.
6. Bizzi E, Pompeiano O, Somogyi I. Spontaneous activity of single vestibular neurons of unrestrained cats during sleep and wakefulness. *Arch Ital Biol*

- 1964;**102**:308-30.
7. Strupp M, Brandt T. Vestibular neuritis. *Adv Otorhinolaryngol* 1999;**55**:111-36.
 8. Neetens A, Van den Ende P. Eye movements during sleep. *Bull Soc Belge Ophthalmol* 1989;**237**:227-44.
 9. Pompeiano O, Morrison AR. Vestibular influences during sleep. I. Abolition of the rapid eye movements of desynchronized sleep following vestibular lesions. *Arch Ital Biol* 1965;**103**:569-95.
 10. Nelson JP, McCarley RW, Hobson JA. REM sleep burst neurons, PGO waves, and eye movement information. *J Neurophysiol* 1983;**50**:784-97.
 11. Baldissera F, Broggi G, Mancina M. Nystagmus induced by unilateral labyrinthectomy affected by sleep-wakefulness cycle. *Nature* 1967;**215**:62-3.
 12. Tauber ES, Weitzman ED, Herman J, Pessah M. Absence of nystagmus during REM sleep in a patient with waking nystagmus and oscillopsia. *J Neurol Neurosurg Psychiatry* 1973;**36**:833-8.
 13. Kawahara R, Hazama H, Fukuhara T, Matsushita T, Makino H. Nystagmus and REM density during sleep in patients with various brain lesions. *Waking sleeping* 1980;**4**:205-10.
 14. Gordon CR, Oksenberg A. Spontaneous nystagmus across the sleep-wake cycle in vegetative state patients. *Electroencephalogr Clin Neurophysiol* 1993;**86**:132-7.
 15. Appenzeller O, Fischer AP. Disturbances of rapid eye movements during sleep in patients with lesions of the nervous system. *Electroencephalogr Clin Neurophysiol* 1968;**25**:29-35.
 16. Eisensehr I, Noachtar S, Strupp M, Von Lindeiner H, Brandt T, Buttner U. Absence of nystagmus during REM sleep in patients with vestibular neuritis. *J Neurol Neurosurg Psychiatry* 2001;**71**:386-9.
 17. Flandrin JM, Courjon JH, Jeannerod M, Schmid R. Vestibulo-ocular responses during the states of sleep in the cat. *Electroencephalogr and Clin Neurophysiol* 1979;**46**:521-30.
 18. Gardner R, Weitzman ED. Examination for optokinetic nystagmus in sleep and waking. *Arch Neurol* 1967;**16**:415-20.