

Salmonella

1

Hemolytic Uremic Syndrome Associated with Salmonella Food Poisoning in Adult: A Case Report

Mi Jung Kang, M.D., Min Kyung Kang, M.D., Jung Hun Sung, M.D.,
Seung Yeup Han, M.D., Sung Bae Park, M.D., Hyun Chul Kim, M.D.

*Dongan Kindey Institute, Keimyung University and Department of Internal
Medicine, Keimyung University School of Medicine, Taegu, Korea*

Abstract : The hemolytic uremic syndrome (HUS) is a rare disorder in adults. It usually occurs in association with various drugs, pregnancy, hypertension, malignancy and collagen vascular diseases. We report here a case of adult HUS caused by Salmonella infection in a 52-year-old male renal allograft recipient who received a kidney from a living-related donor four years ago. He developed nausea, vomiting, abdominal pain and watery diarrhea after dining out. During hospitalization, he developed microangiopathic hemolytic anemia, thrombocytopenia and a rapid rise of serum creatinine. Stool culture revealed Salmonella group B, and urine and blood cultures were sterile. He was treated with intravenous fluids and antibiotics. The patient recovered without plasma exchange. The onset of HUS concomitant with Salmonella food poisoning and the prompt reversion of the HUS after antibiotic treatment of the Salmonella enteritis suggests the causal relationship between HUS and Salmonella infection.

Key Words : Hemolytic uremic syndrome, Salmonella infection, Diarrhea

1955 Gasser [1]

4
vero-

toxin

(, , cyclosporin),

, *Salmonella typhi*, Shigella species, nontyphoidal Samonella 가 [2].

[3]가

가
Salmonella

4
Salmonella group B

creatinine 1.5
1 6
(2 6) 2

creatinine
6.9 mg/dL

steroid

OKT3
가 5

cyclosporine tacrolimus
creatinine 7-8 mg/dL

tacrolimus,
steroid, mycophenolate mofetil

90/50 mmHg,
96 , 28 ,
37.8 가

가

가 :

14.8 g/dL,
49.3% , 17,960 /mm³, 178,000
/mm³ . 1.6% 가
가 2-3 /mm³
1.010, 30
mg/dL, 5-7 /HPF, 2-3
/HPF . 1 1.6 g, crea-
tinine 5.1 mL/min . BUN 89
mg/dL, creatinine 11.7 mg/dL,
Na⁺ 135 mEq/L, K⁺ 7.8 mEq/L
66 mg/dL,
AST 41 IU/L. ALT 9 IU/L, 7.0
mg/dL, 7.7 mg/dL, 3.1 g/dL,
LDH 500.5 IU . PT/aPTT, fibrinogen,
FDP 가 pH
7.156, PCO₂ 14 mmHg, PO₂ 111.8 mmHg,
HCO₃⁻ 5.6 mEq/L, O₂ sat 90%

Coomb's
haptoglobin 149.7 mg/dL

: 가 28.6%, 406,000 /mm³ 가
 ,
 (cephalosporin, isepamicin)
 4 1 7-8
 BUN
 89 mg/dL 108 mg/dL 가
 10.2 g/dL, 32.5%,
 98,000 /mm³ LDH 419.8
 IU
 가 7-10 /mm³ 가 .

28.6%, 406,000 /mm³ 가
 BUN 77 mg/dL, creatinine 8.0 mg/dL,
 LDH 371 IU,
 1-3 /mm³ (Fig. 2).
 14
 creatinine 7-8
 mg/dL

(Fig.

1). Widal test O H
 Samonella type B가 .

5

8

8.2 g/dL,

tacrolimus

2

[4].

tacrolimus

5

가

[4].

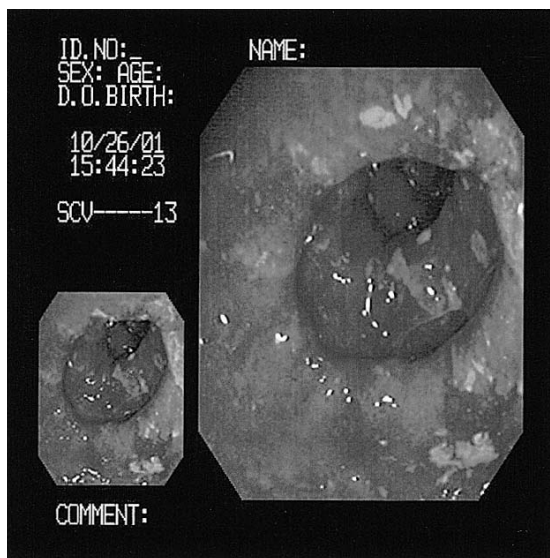


Fig. 1. Diffuse hyperemic and edematous mucosa with superficial erosions are noted in the descending colon.

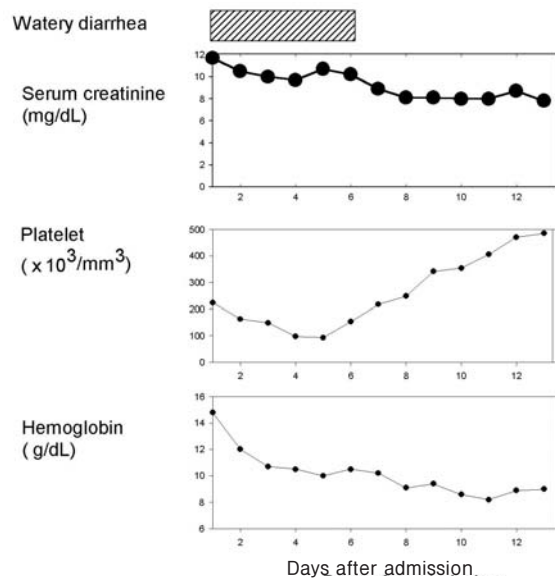


Fig. 2. Summary of the patient's clinical sign and laboratory data during hospitalization.

가 , 가
 , LDH 가

Salmonella B
 Salmonella B .
 5

O157:H7 가 Shigella,
 Salmonella, Yersinia, Campylobacter
 [5].

가

[3] 5

[6] 1987 10
 14
 (mitomycin, cyclosporin A)가 5 ,
 4 , 가 2 , 4

가

1989 4 [7]
 12
 가 3 2 1

1-5 , ,
 [2].
 1-6

가 , 1970
 Konowalchuk [8] Shigella
 dysenteriae DNA 70kDa
 Shiga-like toxins, verotoxin
 verotoxin
 [9].

[10]
 Campylobacter jejuni [11]
 Salmonella
 가

Salmonella
 type B가 2가 가
 가
 Shigella, 가
 , Salmonella type B 가

Shigellosis
 Salmonella type B
 Salmonella
 가
 , Srivastava [12] 73
 7
 Shigella , 9 nontyphoidal Salmonella,
 11
 Baker [13] 48
 6 (12.5%)
 Chaturverdi
 [14] 1 가
 Maudgil [15] 6 Salmonella
 typhimurium
 1 , Dutta [16] Salmonella
 typhimurium
 1
 Flores [17] Salmonella

Shiga like toxin-I II

O157:H7 (lipopolysaccha-
 ride, LPS)
 (ELISA)
 IgM IgG 가
 O157:H7

Chart Jenkins[18]
 O157 Brucella abortus, Yersinia
 enterocolitica 09, Vibrio cholerae 01 Inaba,
 group N Salmonella, Citrobacter freundii,
 E. hermanni epitope
 O157

prostacyclin

[20-23].

1. Gasser C, Gautier E, Steck A, Siebenmann RE, Oechslin R. Hemolytisch-uramische syndrome: bilaterale nierenrindennekrosen bei akuten erworbenen chenschr hamolutischen. *Schweiz Med Wochenschr* 1955; **85**: 905-6.
2. Remuzzi G, Ruggenti P. The hemolytic uremic syndrome. *Kidney Int* 1995; **47**: 2-19.

3. , , , , , , , .
 , .
 1998; **17**: 887-95.
4. Mor E, Lustig S, Tovar A, Bar-Nathan N, Shharabani E, Shapira Z, *et al.* Thrombotic microangiopathy early after kidney transplantation: hemolytic uremic syndrome of vascular rejection? *Transplant Proc* 2000; **32**: 686-7.
5. Kaplan BS, Meyers KE, Schulman SL. The pathogenesis and treatment of hemolytic uremic syndrome. *J Am Soc Nephrol* 1998; **9**: 1126-33.
6. , , , , .
 14
 1994; **13**: 586-94.
7. , , , , , .
 .
 1995; **48**: 10-9.
8. Konowalchuk J, Speirs JI, Stavric S. Vero response to a cytotoxin *E. coli*. *Infect Immun* 1977; **56**: 775.
9. Kaplan BS, Cleary TG, Obrig TG. Recent advances in understanding the pathogenesis of the hemolytic uremic syndrome. *Pediatr Nephrol* 1990; **4**: 276-83.
10. , , , , , , , .
 , .
 1 . 1997; **29**: 243-6.
11. , , , , , , , .
 , .
Campylobacter jejuni 1 .
 1997; **29**: 433-7.
12. Srivastava RN, Moudgil A, Bagga A, Vasudev AS. Hemolytic uremic syndrome. *Pediatr Nephrol* 1991; **75**: 284-8.
13. Baker NM, Mills AE, Rachman I, Thomas JEP. Haemolytic-uraemic syndrome in typhoid fever. *Brit Med J* 1974; **2**: 84-7.
14. Chaturverdi P, Dey SK, Agrawal M. Hemolytic uremic syndrome associated salmonella typhi. *Ind Pediatr* 1990; **27**: 209-10.
15. Maudgil A, Bhan MK, Khoshoo V. Hemolytic ure-

- mic syndrome associated with *Salmonella typhimurium*. *Ind Pediatr* 1987; **24**: 608-9.
16. Dutta P, Bhattacharya SK, Dutta D, Sen D, Nair GB, Mondal BC, *et al*. Hemolytic uremic syndrome following *Salmonella typhimurium* enteritis. *Ind J Pediatr* 1989; **56**: 409-10.
 17. Flores FX, Jabs K, Thorne GM, Linshaw MA, Somer MJ. Immune response to *Escherichia coli* O157 : H7 in hemolytic uremic syndrome following Salmonellosis. *Pediatr Nephrol* 1997; **11**: 488-90.
 18. Chart H, Jenkins C. The serodiagnosis of infections caused by verotoxin-producing *Escherichia coli*. *J Appl Microbiol* 1990; **86**: 731-40.
 19. Siegler RL, Favia AT, Hansen FL, Christofferson RD, Cook JB. Atypical hemolytic-uremic syndrome : a comparison with postdiarrheal disease. *J Pediatr* 1996; **128**: 505-11.
 20. Bell AR, Braine HG, Ness PM, Kickler TS. Improved survival in thrombocytopenic purpura-hemolytic uremic syndrome. *N Engl J Med* 1991; **425**: 398-403.
 21. Matsumae T, Takebayashi S, Naito S. The clinicopathological characteristics and outcome in hemolytic uremic syndrome of adults. *Clin Nephrol* 1996; **45**: 153-62.
 22. Ponticelli C, Rivolta E, Imbasciati E, Rossi E, Mannucci PM. Hemolytic uremic syndrome in adults. *Arch Intern Med* 1980; **140**: 353-7.
 23. Melynk A, Solez L, Kjellstrans CM. Adult hemolytic uremic syndrome: a review of 37 cases. *Arch Intern Med* 1995; **155**: 2077-84.