

Elephant trunk fabric bleeding during second-stage thoraco-abdominal aneurysm repair

Jae Hyun Kim* and Chan-Young Na

Department of Thoracic and Cardiovascular Surgery, Sejong Heart Institute, Sejong General Hospital, Bucheon, South Korea

* Corresponding author: 91-121, Sosabon2-dong, Sosa-gu, Bucheon-si, Gyeonggi-do 422-711, South Korea. Tel: +82-32-3401151; fax: +82-32-3401236; e-mail: jaemax31@gmail.com (J.H. Kim).

Received 7 May 2012; received in revised form 1 June 2012; accepted 4 June 2012

Abstract

Bleeding from the elephant trunk fabric is a rare and under-recognized complication during second-stage thoraco-abdominal aortic aneurysm repair. In this article, we report one case of bleeding from the elephant trunk fabric and discuss the possible causes, management and prevention of this complication.

Keywords: Aneurysm (whole aorta) • Aortic operation • Endovascular procedures/stents • Bleeding (elephant trunk fabric)

INTRODUCTION

The elephant trunk (ET) procedure was designed to make a second-stage operation easy and safe. This procedure has improved the surgical outcome of second-stage thoracic or thoraco-abdominal aortic aneurysm repair for the past several decades and has evolved into the 'frozen ET technique' [1]. Bleeding from the ET fabric is a rare complication and poorly recognized.

CASE REPORT

A 44-year old male with Marfan syndrome and hypertension was referred to our institution complaining of ongoing back pain for 4 days. He had had a Bentall's operation for an acute type A aortic dissection 14 years previously. Preoperative computed tomography (CT) showed the remaining chronic dissection and aneurysmal changes starting from the arch to both iliac arteries (Fig. 1a). The maximum diameter of the aneurysm was 9 cm at the proximal descending aorta. The innominate artery aneurysm measured 4 cm in diameter. A hyper-attenuating crescent sign, which is a CT sign of impending rupture, was visible within the thrombus on non-contrast CT imaging (Fig. 1b).

To address the problem, we planned a hybrid arch operation. A total arch replacement with an ET was performed. Gelweave four-branch collared graft (24 mm; Vascutek, Inchinnan Renfrewshire, UK) was used for the operation. Total circulatory arrest time, cardiac ischaemic time and cardiopulmonary bypass time were 56, 113 and 254 min, respectively. Five days after the operation, we performed endovascular stenting using the ET as a proximal landing zone. Valiant thoracic stent grafts (Medtronic, Inc., Santa Rosa, CA, USA) of 30 × 30 × 200 and 32 × 32 × 150 mm were used. The final angiogram showed no proximal type I endoleak. A 3-month follow-up CT revealed well-seated stent grafts with no proximal endoleak (Fig. 2a).

Thoracic stent-grafting of this patient was originally planned as a bridging procedure to provide a convalescence period. So second-stage thoraco-abdominal aneurysm repair was performed 3 months after the procedure.

Left heart bypass was instituted using the left inferior pulmonary vein as an inflow site and the distal descending thoracic aorta as an outflow site. Intravenous heparin (1 mg/kg) was administered and the activated clotting times (ACT) were maintained within 200–250 s. All thoracic stents were removed. The proximal anastomosis between the ET graft and a new graft (22 mm; Gelweave four-branch Coselli graft; Vascutek, Inchinnan) was made without difficulty. The proximal clamp was moved below the level. Once left heart bypass was stopped, the distal aorta was opened. Selective visceral perfusion was performed.

While we were attaching the segmental arteries, blood started to seep through the ET fabric and became a massive haemorrhage (Fig. 2b). At the beginning, coagulation system was intact except for the prolonged activated partial thromboplastin time and ACT due to heparinization. The ET was wrapped using a Hemashield graft (Boston Scientific, Natick, MA, USA). After finishing all the remaining anastomoses, the heparin was reversed. 2700 cc of blood was processed by the cell saver, and an additional 6500 cc of packed cells were transfused. To correct the developing coagulopathy, 4200 cc of fresh frozen plasma, 720 cc of platelet concentrate, 720 cc of cryoprecipitate and other pro-coagulants were required. Then, bleeding was reduced but still prolonged at a significant level. Pulmonary haemorrhage following severe coagulopathy developed. The patient succumbed to hypoxia after the pulmonary haemorrhage.

DISCUSSION

Reported complications related to the ET procedure are kinking, obstruction, embolization, graft entrapment in the false lumen

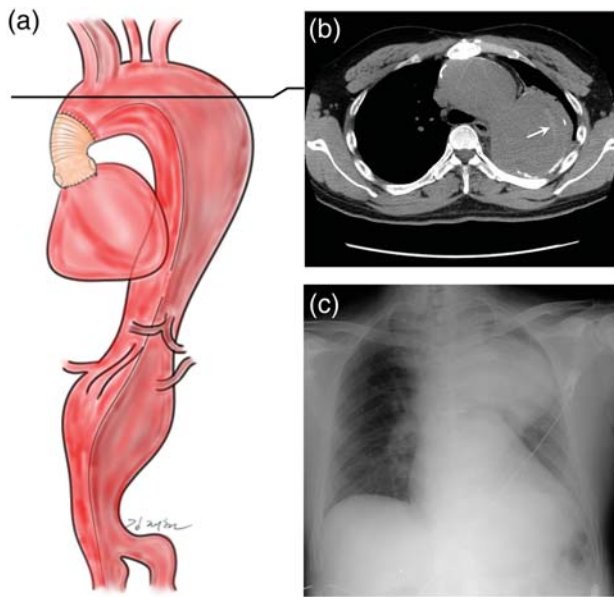


Figure 1: (a) Preoperative drawing illustrating an aortic aneurysm with chronic aortic dissection involving aortic arch, innominate artery and thoraco-abdominal aorta in a patient who underwent Bentall's operation for acute type I aortic dissection 14 years previously. The maximum diameter of the aneurysm was 9 cm at the proximal descending aorta. The innominate artery aneurysm measured 4 cm in diameter. (b) Preoperative non-contrast CT image showing a hyper-attenuating crescent sign (arrow). (c) Preoperative chest X-ray showing a huge aortic aneurysm.

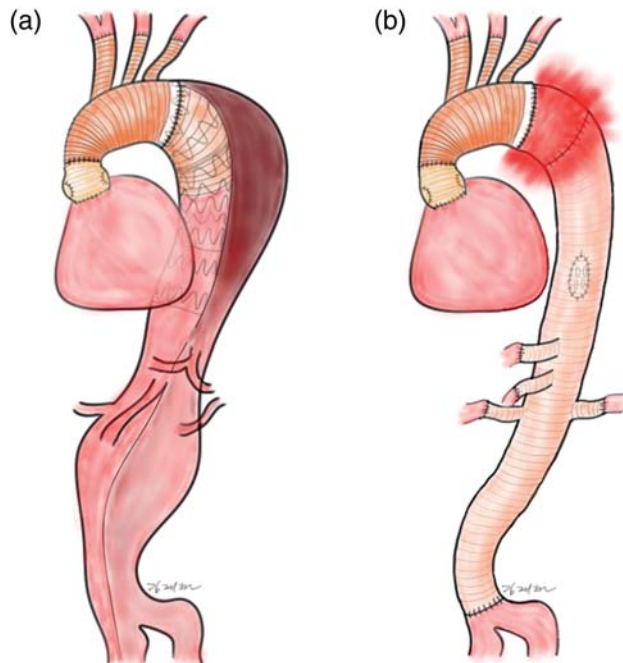


Figure 2: (a) Illustration showing well-seated stent grafts with no proximal endoleak after total arch replacement with the ET procedure and subsequent thoracic endovascular stent-grafting. (b) Postoperative drawing illustrating a massive haemorrhage seeping through the ET graft fabric.

and paraplegia [1]. However, reports on bleeding from the ET fabric are very rare [2, 3]. The consequences of severe bleeding in those reports were paraplegia [3] and prolonged mechanical ventilation after re-exploration [2].

We considered possible reasons for the ET fabric bleeding. First, the patient's coagulation system might be a culprit. But this was less likely because he had no coagulation problems during the previous two aortic surgeries. Furthermore, the bleeding occurred not through the suture lines but only through the ET fabric. Second, the floating nature of the ET in the blood stream might adversely affect the process of neo-intima formation. Third, the thoracic-stent, which blocked blood, i.e. prevented it from coming into contact with the inner side of the graft and distended the graft, might have played a role in the ET fabric bleeding. Finally, degradation of the gelatine-coating on the graft may have been associated with the bleeding. The gelatine impregnation completely lysed within 2 weeks, thus allowing encapsulation and graft healing to progress satisfactorily. Compared with other sealants such as albumin and collagen, it takes less time for gelatine to resorb [4]. If we have to perform open repair during the insufficient tissue ingrowth 2 weeks after implantation of the gelatine-coating graft, the risk of ET fabric bleeding would increase. Safety and optimal reintervention timing for the available Dacron grafts need to be investigated. Although we missed the chance to send the explanted fabric to the company, it should be noted that a thorough analysis of the fabric is very important.

To prevent this lethal complication, the endothelial lining inside the ET graft should be preserved and should not peel off. An ET graft should be cut as long as possible to leave only the necessary portion for the proximal anastomosis.

To treat the bleeding from the ET fabric, wrapping of the ET with remnant aortic tissue or prosthetic material would be an option. However, the wrapping procedure might not always be effective as in the case described herein. Another option would be thoracic stent-grafting to cover the lesion. A thoracic stent could be deployed either under direct palpation or under the aid of trans-oesophageal echocardiography or fluoroscopic guidance by puncturing the side of the newly replaced graft.

CONCLUSION

ET fabric bleeding is a poorly recognized complication. We suggest collecting every case related to this complication, even if the operation was unsuccessful, to elucidate the exact reason and mechanism. We hope that this report serves as an alarm to aortic surgeons who are preparing for second-stage ET completion surgery. An awareness of this complication of 'ET fabric bleeding' may change a lethal result into a non-lethal outcome.

Conflict of interest: none declared.

REFERENCES

- [1] Ius F, Hagl C, Haverich A, Pichlmaier M. Elephant trunk procedure 27 years after Borst: what remains and what is new? *Eur J Cardiothorac Surg* 2011;40:1-11.
- [2] Neri E, Toscano T, Frati G, Sassi C. The elephant trunk technique: a new complication. *Tex Heart Inst J* 2001;28:220-2.
- [3] Fukumura Y, Osumi M, Matsueda T, Kurushima A, Otani T. Bleeding complication from the elephant trunk graft at the 2nd stage operation of the total aortic replacement. *Kyobu Geka* 2010;63:449-52.
- [4] Ukpabi P, Marois Y, King M, Deng X, Martin L, Laroche G *et al.* The gel-weave polyester arterial prosthesis. *Can J Surg* 1995;38:322-31.