

APDW 2018 E-poster Exhibitions – Endoscopy

EE-0100 (PE-0038) Capsule endoscopic observation of small intestine in patients with familial adenomatous polyposis

Authors: TOMOAKI KONO; HIROKAZU FUKUI; HIROTSUGU EDA; KUMIKO NAKAMURA; AKIO TAMURA; TOMOHIRO OGAWA; TAKAHISA YAMASAKI; TAKUYA OKUGAWA; TAKASHI KONDO; KATSUYUKI TOZAWA; TOSHIHIKO TOMITA; TADAYUKI OSHIMA; JIRO WATARI; HIROTO MIWA

Affiliation: Department of Internal Medicine, Division of Gastroenterology, Hyogo College of Medicine, Nishinomiya, Japan

Background and Aim: Familial adenomatous polyposis (FAP) is the inherited disease in which adenomatous polyps likely develop throughout gastrointestinal tracts. In contrast to the colon and stomach, little information is available for tumor prevalence and its morphological features in the small intestine. Therefore, using a capsule endoscopy (CE), we aimed to clarify the characteristics of the small intestinal lesions in FAP patients. **Methods:** We investigated 17 FAP patients who had undergone all of CE and the upper- and lower-GI endoscopy in our hospital between October 2011 and January 2018. We retrospectively investigated the endoscopic and pathologic features of whole gastrointestinal lesions and analyzed its relation to clinical features in those FAP patients. **Results:** FAP patients examined (male/female, 6/11, mean age 44.5 ± 2.7 [range 30–65] years) were consisted of 6 severe and 11 sparse types. Regarding small intestinal polyps, 7 patients (41%) had them in the jejunum and 4 (24%) had in the ileum. The number of small intestinal polyps were less than 10 mm in any cases. When analyzed FAP patients by subdividing into the severe/sparse type, the numbers of duodenal polyp and the prevalence of Vater ampulla tumor were significantly increased in severe FAP but no correlation was found in the number of small intestinal polyps. However, we found that the number of small intestine was significantly greater in FAP patient group with ≥ 20 duodenal polyps (1.7 ± 2.7 vs. 7 ± 7.5 ; $p = 0.0438$). **Conclusion:** Small intestinal polyps develop in approximately 40% of FAP patients, and their number is significantly greater in FAP patient group with ≥ 20 duodenal polyps.

Keywords: familial adenomatous polyposis (FAP), capsule endoscopy (CE), small intestinal polyp

OE-0072 (PE-0039) Clinical characteristics and outcome of patients with obscure gastrointestinal bleeding undergoing capsule endoscopy: 10-year experience in a local hospital

Authors: HW LIU; YT HUI; SF SZE; YY LAM; CT WONG; TW LAM

Affiliation: Department of Internal Medicine-GI/Hepatology, Queen Elizabeth Hospital, Hong Kong, Hong Kong

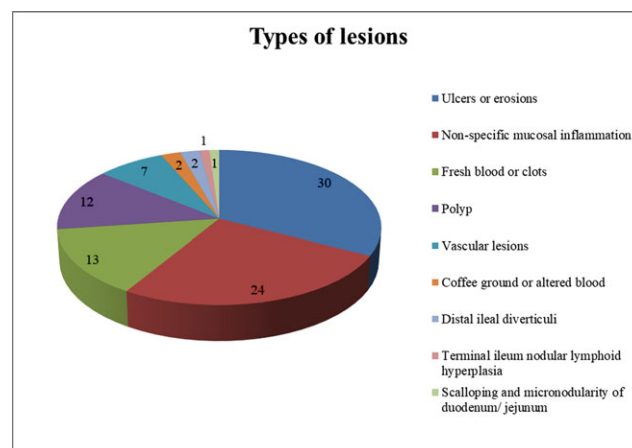
Background and Aim: To determine the clinical characteristics, prognostic factors and outcome of patients who underwent small bowel capsule endoscopy for obscure gastrointestinal bleeding. **Methods:** A total of 90 patients with obscure gastrointestinal bleeding and small bowel capsule endoscopy done were retrospectively included in the present study. Logistic regression was carried out to define predictive factors for presence of small bowel lesion and incomplete capsule examination. Risk factors for rebleeding in those with negative capsule result were identified using Cox regression analysis. Factors that influenced the small bowel transit time were analyzed. The safety profile of the procedure was also assessed.

Results: The diagnostic yield in our cohort was 46.7%, with positive rate similar between overt and occult bleeding groups. Patients with congestive heart failure had a higher diagnostic yield. History of myocardial infarction, moderate to severe renal or liver disease, overt bleeders, and hemoglobin $< 8\text{g/dL}$ on presentation were independent predictors of rebleeding. Suboptimal bowel preparation, prior abdominal radiotherapy, and higher Charlson Index were risk factors for incomplete examination. Small bowel transit time was prolonged in patients with prior abdominal surgery or suboptimal bowel preparation. Only one patient experienced capsule retention (1.1%) and the procedure was as safe in the elderly as in younger adults.

Conclusion: Small bowel capsule endoscopy is a safe procedure with satisfactory diagnostic yield for patients presenting with obscure gastrointestinal bleeding. It is equally useful in overt and occult bleeders. Patients with negative capsule examination still carry a considerable rebleeding risk and should be closely observed.

Keywords: small bowel capsule endoscopy, obscure gastrointestinal bleeding

Capsule findings in small bowel



OE-0413 (PE-0040) The role of video capsule endoscopy in the diagnosis of small bowel diseases in Nile Delta

Authors: MOHAMED ELSAYED ABDELRAOUF SARHAN[1]; MAMDOUH AHMED GABR[1]; NESREEN AHMED KOTB[1]; AHMED ALI MONIS[2]

Affiliation: [1]Department of Internal Medicine Department. Digestive Endoscopy Unit, Tanta University Hospital-Egypt, Tanta, and [2] Department of Internal Medicine, Ain Shams University, Cairo, Egypt

Background and Aim: Examination of the small bowel represents a challenge for endoscopists. The advent of video capsule endoscopy (VCE) dramatically changed the diagnostic evaluation of small intestinal diseases. It is non-invasive, convenient, and safe. The aim is to determine the diagnostic yield of VCE in patients with suspected small bowel diseases among our population in the middle of Nile Delta. **Methods:** The study was carried out on 22 patients (12 males and 10 females) who were attendants of Tanta Digestive Endoscopy Center-Egypt. Patients with obscure gastrointestinal bleeding (OGIB) or suspected other small bowel disease whom upper and lower endoscopy were negative were included. OMOM capsule, Jinshan Science and Technology Group, China, was conducted to those patients with negative upper endoscopy and colonoscopy searching for small bowel pathology. **Results:** Distribution of video capsule endoscopy findings among the studied patients was illustrated in Table 1a positive diagnosis (small intestinal abnormalities) was obtained in 19 patients (86.8%), while non-specific lesions were detected in 3 patients (13.6%). In univariate analysis, age, sex, lowest hemoglobin level, and comorbidities were not significant as a prognostic factors associated with re-bleeding. After treatment, re-bleeding occurs in 4 patients with diagnosed vascular anomalies, 1 patient with ileal lymphangectasia (22.72). **Conclusion:** Vascular malformations, small bowel ulcers, and small bowel tumors are the principal small intestinal lesions among our Egyptian population in the middle of Nile Delta. In spite of lack of treatment abilities, VCE is an accurate tool in the arsenal of endoscopic procedures.

Keywords: video capsule endoscopy, small bowel, diagnostic yield, Nile Delta

Table 1. Distribution of VCE findings

Video Capsule Endoscopy(VCE) findings	No.	%
Small intestinal ulcers	3	13.63
Vascular malformations	7	31.81
Dieulafoy's lesion	1	4.54
Small intestinal diverticulum	1	4.54
Ileal lymphangectasia	1	4.54
Ischemic bowel disease	1	4.54
Jejunal varices	1	4.54
Non-specific enteritis	1	4.54
small intestinal tumours	3	13.63
Small intestinal ulcer	3	13.63
Total	22	100.0

OE-0601 (PE-0041) Yield of capsule endoscopy in 206 patients with obscure gastrointestinal bleeding: Experience from a Single Tertiary Hospital in Singapore

Authors: GOVINDASAMY NEDUNCHEZHIAN[1]; JONATHAN LEE[2]; KEWIN SIAH[2]; ALEX SOH[2]; PHYLLIS TAN[2]

Affiliation: [1]Department of Medicine, National University Health System, Division of Gastroenterology and Hepatology, Singapore, National University of Singapore, Yong Loo Lin School of Medicine, and [2]Department of Internal Medicine-GI/Hepatology, National University Health System, Division of Gastroenterology and Hepatology, Singapore, Singapore

Background and Aim: Capsule endoscopy (CE), a minimally invasive method to evaluate the small intestine, plays a crucial role in the evaluation and management of obscure gastrointestinal bleeding (OGIB) patients. Our objective here is to review the diagnostic yield and the predictors of positive yield of capsule endoscopy in OGIB. **Methods:** Four hundred twenty-six patients from National University Hospital, Singapore underwent capsule endoscopy with PillCam™ SB video capsule system from 2006 to 2018. A total of 206 (48.4%) patients underwent CE for investigation of OGIB. Statistical analysis for predictors of positive findings with CE was done using binary logistic regression with SPSS v25. **Results:** Positive yield was 85.4% ($n = 176$), whereby erosions ($n = 95$, 54%), ulcers ($n = 66$, 37.5%), and angiodysplasia ($n = 51$, 29.0%) were the most common pathologies identified overall on capsule endoscopy. Forty-three (20.9%) patients had either evidence of active bleeding or lesions with stigmata of recent hemorrhage, of which 23 (53.5%) were bleeding from the small bowel, 16 (37.2%) were bleeding from either the stomach or duodenum, and 4 (9.3%) were bleeding from the colon. Three (7.0%) patients and 17 (39.5%) patients subsequently underwent further surgical and therapeutic endoscopic intervention, respectively. Among the 30 patients (14.5%) with no abnormal findings, 16.7% patients had poor bowel preparation compared to 6.3% of the patients with positive findings. Patients with poor bowel preparation were 3 times more likely to have a negative yield from capsule endoscopy (OR 3.00, 95% CI 0.97–9.36, $p = 0.058$). The overall capsule retention remained low at 1.2%. **Conclusion:** Capsule endoscopy triages the minority of the patients who would benefit from subsequent invasive evaluation and intervention. It is particularly useful in investigating obscure bleeding gastrointestinal tract, whereby adequate bowel preparation is critical to achieve accurate diagnosis.

Keywords: capsule endoscopy, obscure gastrointestinal bleeding, bowel preparation, capsule retention

OE-0926 (PE-0042) The effectiveness of improved use of chewing gum in influencing capsule endoscopy transit time a prospective randomized, controlled pilot study

Authors: YUE HU; LIANG HUANG; BIN LV

Affiliation: Department of Gastroenterology, First Affiliated Hospital of Zhejiang Chinese Medical University, Hangzhou, China

Background and Aim: To determine the effect of chewing gum, during the first 1 h of examination in patients undergoing CE for GTT and SBTT time and the proportion of cases with complete small bowel examination. **Methods:** Consecutive patients 16 years of age and older undergoing small-bowel CE from November 2017 to April 2018 were assessed for eligibility. Patients chewed one piece of gum for approximately 15 min every 30 min at the first hour of the examination. Two blinded gastroenterologists examined all studies. The completion rate of CE that reached the caecum within 10 h, gastric transit time (GTT) and small bowel transit time (SBTT) were evaluated in all patients. **Results:** Fifty-two consecutive patients were randomized either to use chewing gum ($n = 26$) or not ($n = 26$). The mean age was 47.5 ± 18.3 and 48.0 ± 19.0 years, respectively. The GTT in the chewing-gum group was significantly shorter than control (35.5 min vs. 65.5 min [$P < 0.05$]). There was no significant difference in SBTT between the two groups (350.0 min vs. 384.0 min [$P > 0.05$]). The CE percentage passed into the caecum was no difference in the chewing gum group compared with those in another (88.5% vs. 76.9%, respectively, $P > 0.05$). **Conclusion:** Chewing gum at the first hour during CE examination could significantly reduce GTT but not SBTT. Its use might improve the likelihood of the diagnostic yield of CE by the unaltered small bowel transit during the procedure.

Keywords: capsule endoscopy, chewing gum, gastric transit time, small bowel transit time

EE-0044 (PE-0043) Clinical impact of perioperative management of oral anticoagulants in bleeding after colonic endoscopic mucosal resection

Authors: SHOKO ONO[1]; IKKO TANAKA[2]; SAYOKO KINOWAKI[2]; MASAKI INOUE[2]; KANA MATSUDA[2]; MARIN ISHIKAWA[2]; MOMOKO TSUDA[2]; KEIKO YAMAMOTO[1]; YUICHI SHIMIZU[1]; NAOYA SAKAMOTO[2]

Affiliation: [1]Department of Internal Medicine-GI/Hepatology, Hokkaido University Hospital, and [2]Department of Internal Medicine-GI/Hepatology, Graduate School of Medicine and Faculty of Medicine Hokkaido University, Sapporo, Japan

Background and Aim: Heparin bridging therapy (HBT) is actually related to a high frequency of bleeding after endoscopic mucosal resection (EMR). To investigate clinical impact of management of oral anticoagulants without HBT in bleeding after colonic EMR. **Methods:** From data for patients who underwent colonic EMR, the relationships of patient factors and procedural factors with the risk of bleeding were analyzed. Our management of antithrombotic agents was based on the shortest cessation as follows: administration of warfarin was generally continued within the therapeutic range and direct oral anticoagulants (DOACs) were not administered on the day of the procedure. **Results:** A total of 1734 polyps in 825 EMRs were analyzed. Bleeding occurred in 4.0% of the patients and 1.9% of the polyps. Odds ratios of bleeding using multivariate logistic regression analysis were 3.72 in patients who used anticoagulants and 4.76 in patients who used both anticoagulants and antiplatelet agents. In patients with 1-day skip of DOACs, bleeding occurred in 6.5% of the polyps. However, HBT was the highest bleeding rate (9.7%). **Conclusion:** Use of oral anticoagulants was related to bleeding after colonic EMR, and 1-day skip of DOACs would be clinically acceptable as perioperative management without HBT.

Keywords: colon polyp, EMR, anticoagulants, DOAC, warfarin

EE-0056 (PE-0044) Clinical significance and safety of colonoscopy in elderly patients

Authors: SOOYEONG KWAK[1]; BYUNGK JANG[1]; JOONHYUN CHO[1]; SUNGBUM KIM[1]; KOOKHYUN KIM[1]; SIHYUNG LEE[1]; TAENYEUN KIM[1]; CHANG HEON YANG[2]

Affiliation: [1]Department of Internal Medicine-GI/Hepatology, Yeungnam University Medical Center, Daegu, and [2]Department of Internal Medicine-GI/Hepatology, Dongguk University School of Medicine, Gyeongju, Republic of Korea

Background and Aim: Current guidelines do not suggest an upper age cut-off for colorectal cancer (CRC) screening with colonoscopy (CFS). The aim of this study was to assess the clinical significance and safety of CFS and to analyze predictive factor of CRC in elderly patients. **Methods:** From 2008 to 2012, clinical data of 479 patients older than 75 years who underwent CFS were reviewed retrospectively. **Results:** Mean age was 77.96 years and male to female ratio 1:0.53. Excluding the cases of cancer obstruction, cecal intubation rate was 98.86%. One hundred forty-four patients (30.06%) were asymptomatic individuals undergoing screening or surveillance CFS, whereas 335 patients (69.94%) had symptoms prior to CFS, most commonly abdominal pain (20.04%). Complication was noted in 4 patients (0.84%), in which all cases were immediate bleeding that was successfully controlled by endoscopic hemostasis. The overall frequency of advanced adenoma and CRC was 10.02% ($n = 48$) and 23.17% ($n = 111$), respectively. Patients with CRC had more comorbidities ($p = 0.006$) and significantly poor bowel preparation state ($p < 0.0001$). Most common location of CRC was rectosigmoid area (56.76%). In patients with CRC, most common indication of CFS was blood in stool (27.9%), while in rest of patients without CRC was for screening or surveillance purpose (34.0%), followed by abdominal pain (20.9%). **Conclusion:** Our study showed that complete CFS could be performed safely and the possibility of CRC was high in cases with bloody stool in patients older than 75 years. Therefore, we should consider performing CFS in such patients. Taking into account that most of the CRC was found in rectosigmoid area, sigmoidoscopy can also be a safe alternative if patient's risk of complication associated with CFS is considered high.

Keywords: colonoscopy, elderly patients, colorectal cancer, screening, bloody stool

EE-0094 (PE-0045) Long-term outcomes of patients with indeterminate or positive lateral margin after endoscopic resection and related factors with recurrence in large, sessile or flat colorectal polyps

Authors: SU BUM PARK; HYUNG WOOK KIM; DAE HWAN KANG; CHEOL WOONG CHOI; SU JIN KIM; HYEONG SEOK NAM; DAE GON RYU; BYUNG JIN KWON; JUNG WOOK LEE

Affiliation: Department of Internal Medicine-GI/Hepatology, Pusan National University Yangsan Hospital, Yangsan, Republic of Korea

Background and Aim: Recurrence rate in colorectal polyps with indeterminate or positive lateral margin on histology is unclear. We evaluated the long-term outcomes of patients with indeterminate or positive lateral margin after endoscopic resection and related factors with recurrence in large, sessile or flat polyps. **Methods:** We collected the data for 156 lesions with large size (≥ 1 cm), sessile or flat shape, indeterminate or positive lateral margin in histology, and more than 24 months of follow-up intervals between Jan 2009 and Sep 2017. We analyzed recurrence rate, time to recurrence, histology at recurrence, and risk factors related with recurrence. **Results:** During follow-up periods (24–86 months, mean 44.2), recurrence rate was 7.1% (11/156) and mean time to recurrence was 39.2 months (20–59). Recurrence rate of cuff-off techniques were 3.2% (4/127) in en bloc, 9.1% (1/11) 2 piecemeal resection, and 33.3% (6/18) in ≥ 3 piecemeal resection. In analysis for risk factors related with recurrence, only ≥ 3 piecemeal resection were significantly related with recurrence in both univariate analysis and multivariate analysis (OR 16.92, $p = 0.037$). **Conclusion:** Following patients with indeterminate or positive lateral margin after endoscopic resection in large, sessile or flat colorectal polyp, recurrence rate was relatively low and time to recurrence was long than 12 months. Therefore, surveillance interval for these patients can be extended for more than 12 months. However, short-term follow-up is mandatory in case of ≥ 3 piecemeal resections or suspected submucosal cancer in morphology because of risk of recurrence or interval cancer.

Keywords: colorectal polyp, lateral margin, recurrence

Characteristics of recurrence patients

Characteristics of recurrence patients

No	Sex	Age	Location	Size (mm)	Shape	Resection method	Initial histology	Cut-off technique	Complication	Time to Recur	Histology of Recur	Size of recur (mm)	Treatment
1	female	76	rectum	41	lla	hybrid EMR	LGD	≥ 3 piecemeal	none	42	LGD	10	EMR
2	female	58	left	30	lla	conventional EMR	LGD	≥ 3 piecemeal	none	23	LGD	15	EMR
3	male	51	rectum	46	ls	conventional EMR	CIS	≥ 3 piecemeal	perforation	60	LGD	3	Bx removal
4	male	65	right	10	ls	conventional EMR	CIS	en bloc	bleeding	32	LGD	3	Bx removal
5	male	75	right	19	lla	hybrid EMR	SSA/P	en bloc	none	19	LGD	6	EMR
6	female	76	right	17	ls	conventional EMR	HGD	2 piecemeal	bleeding	50	cancer	advanced	operation
7	female	64	right	20	lla	conventional EMR	LGD	≥ 3 piecemeal	none	29	LGD	5	EMR
8	female	76	rectum	12	lla	conventional EMR	LGD	en bloc	none	17	LGD	3	Bx removal
9	male	52	right	18	ls	conventional EMR	LGD	en bloc	none	25	HGD	11	EMR
10	female	78	right	20	lla	hybrid EMR	LGD	≥ 3 piecemeal	none	50	cancer	advanced	operation
11	male	62	right	40	lla	conventional EMR	LGD	≥ 3 piecemeal	none	84	LGD	30	operation

EE-0098 (PE-0046) Clinical usefulness of colonoscopy in patients with early gastric cancer treated by endoscopic submucosal dissection (comparison with patients with positive fecal immunochemical test results)

Authors: YOSHIHARU YAMAGUCHI; MASAHIDE EBI; TOMOKO OCHIAI; KAZUHIRO YAMAMOTO; SATOSHI INOUE; KAZUNORI ADACHI; TOMOYA SUGIYAMA; YASUTAKA HUIKATA; NAOTAKA OGASAWARA; YASUSHI FUNAKI; MAKOTO SASAKI; KUNIO KASUGAI

Affiliation: Department of Gastroenterology, Aichi Medical University School of Medicine, Nagakute, Japan

Background and Aim: In Asia, second primary cancers are a leading cause of morbidity and mortality among cancer survivors. Colorectal neoplasms are the most commonly observed tumors outside of the stomach in patients with gastric cancer. We examined the usefulness of colonoscopy (CS) for patients undergoing gastric endoscopic submucosal dissection (ESD) and risk factors for colorectal neoplasms. **Methods:** Of the 312 patients who underwent ESD for early gastric cancer in the 3 years between January 2015 and December 2017, 143 patients receiving CS were included (g-ESD group) in this study. And 874 asymptomatic patients who underwent CS during the same period because of positive fecal immunochemical test (FIT) results were selected (FIT positive group). In this study, we compared with the background of two groups and statistically analyzed. **Results:** The total number of colorectal neoplasm was found in 62.9% (90 cases) in the g-ESD group, 46.6% (407 cases) in the FIT positive group, and significantly more colorectal neoplasm were found in the g-ESD group ($p < 0.001$). Advanced adenoma and carcinoma (AAC) was significantly higher in 30 cases of g-ESD group (20.1%) than in 72 cases of FIT positive group (8.2%). Statistical analyses were performed with adjusted for age and sex, AAC was significantly higher in g-ESD group ($p = 0.01$). Additionally, in the g-ESD group, high body mass index (BMI) was the risk factor of AAC. **Conclusion:** In patients undergoing gastric ESD, CS appears to be necessary for detecting synchronous double neoplasms. In particular, we recommend performing CS in patients with high BMI.

Keywords: colorectal neoplasm, gastric neoplasm, endoscopic submucosal dissection, colorectal neoplasm, endoscopic submucosal dissection, fecal immunochemical test

EE-0131 (PE-0047) An evaluation of predictive factors for bowel preparation before colonoscopy using the Boston Bowel Preparation Scale

Authors: HIROMICHI TSUNASHIMA; KOICHIRO SATO; TAKESHI ONDA; NORIYUKI KUNIYOSHI; KOTARO MATSUMOTO; KATSUNORI SEKINE; TAKAYUKI TSUJIKAWA; MASATOSHI MABUCHI; YUSUKE KAJIYAMA; SHINPEI DOI; KENTARO KIKUCHI; ICHIRO YASUDA

Affiliation: Department of Gastroenterology, Teikyo University Mizonokuchi Hospital, Kanagawa, Japan

Background and Aim: An evaluation of predictive factors for bowel preparation before colonoscopy using the Boston Bowel Preparation Scale. **Methods:** We evaluated 400 colonoscopies performed from March 2016 to June 2017 to analyze the degree of bowel preparation using the Boston Bowel Preparation Scale (BBPS) and assessed the predictive factors for inadequate bowel preparation. All patients received low-volume (2 L) polyethylene glycol solution with ascorbate (MoviPrep®) before colonoscopy. The potential predictive factors for inadequate bowel cleansing were older age (≥ 75), male gender, obesity ($\text{BMI} \geq 25$), constipation, laxative use, a history of abdominal surgery, single- or split-dose intake preparation, diverticulosis, and diabetes mellitus. Inadequate bowel preparation was defined as a BBPS ≤ 5 . We excluded patients with a diagnosis or history of colonic stricture, inflammatory bowel disease, or prior colectomy. **Results:** The median (range) patient age was 68 (27–84), and 43% were women. The median (range) number of bowel movements per week was 5.7 (1–11). The median (range) BBPS score was 8 (3–9), and the rate of adequate bowel preparation (BBPS ≥ 6) was 94.3%. A univariate analysis of the factors associated with inadequate bowel preparation were obesity ($P = 0.007$), diabetes mellitus ($P = 0.005$), and constipation ($P = 0.0428$). A multivariate logistic regression analysis showed that obesity (OR 2.76 [95% CI 1.07–7.23], $P = 0.035$) and diabetes mellitus (OR 3.65 [95% CI 1.32–9.64], $P = 0.0133$) were independent factors related to inadequate bowel cleansing. **Conclusion:** Using the BBPS score to evaluate colon cleansing, the predictive factors associated with inadequate bowel preparation were obesity ($\text{BMI} \geq 25$) and diabetes mellitus.

Keywords: BBPS, intestinal washing

EE-0150 (PE-0048) Clinical outcomes of the palliative colorectal stenting**Authors:** RYO KODAMA; MASATO KAMAKURA; HISANOBU SAEGUSA; HIROYASU USHIMARU**Affiliation:** Department of Gastroenterology, JA Nagano Koseiren Minaminagano Medical Center, Shinonoi General Hospital, Nagano, Japan

Background and Aim: Colonic stent placement represents an established strategy for managing patients with malignant colorectal obstruction. However, there is not enough evidence about colorectal stenting for palliative care. This study aims to evaluate the clinical benefit of palliative colorectal stenting. **Methods:** We retrospectively analyzed data from 32 patients with malignant colorectal obstruction who had undergone palliative colorectal stent placement between 2014 and 2018 to evaluate stent dysfunction and mortality. All colorectal stent were placed under endoscopic and fluoroscopic guidance. **Results:** The median age of patients was 79% of patients were male and 31% were female. Ninety-four percent of the causes of colorectal obstruction were colorectal cancer, and 6% were peritoneal dissemination. Sixteen percent of the patients had the obstruction located in the ascending colon, 13% in the transverse colon, 6% in the descending colon, 37% in the sigmoid colon, and 28% in the rectum. Technical success rate was 94%. Complication of the stenting procedure was microperforation in 3% but improved by conservative treatment. Clinical success rate was 100%. Fifteen cases received chemotherapy. Stent dysfunction occurred in 7 cases, and the mean period to stent dysfunction was 259 days (42–732). Stent migration occurred in 3 of 7 cases, and all of them received chemotherapy. In-growth or over-growth occurred in 4 of 7 cases, and 3 of 4 cases did not receive chemotherapy. In 1 case of stent dysfunction, re-stenting was failed and operation was done. In another 6 cases, re-stenting were succeeded; however, in two cases, stent dysfunction were repeated. Kaplan–Meier curve analyzing revealed that the mean survival period and the mean complication free period of patient who received colorectal stenting were 393 and 511 days, respectively. **Conclusion:** This study revealed that the stent had long-term patency and for majority of the cases, colorectal obstruction could be avoided until death.

Keywords: colorectal stent, palliative care**EE-0168 (PE-0049) The effect of sending educational video clips via smartphone mobile messenger on bowel preparation before colonoscopy****Authors:** JAE HYUN KIM; SUNG CHAN JEON; HYE JUNG KWON; YOUN JUNG CHOI; SUN JUNG KIM; KYOUNGWON JUNG; SUNG EUN KIM; WON MOON; MOO IN PARK; SEUN JA PARK**Affiliation:** Department of Internal Medicine-GI/Hepatology, Kosin University Gospel Hospital, Busan, Republic of Korea

Background and Aim: We aimed to evaluate the efficacy of sending educational video clips via smartphone mobile messenger (SMM) on bowel preparation before colonoscopy. **Methods:** This was a prospective, endoscopist-blinded, randomized controlled study. Patients in the SMM group received two video clips sent via SMM that introduced diet and regimen for bowel preparation, whereas those in the control group did not receive any video clip. We compared the quality of bowel preparation between the two groups, which was assessed by the endoscopist using the Ottawa scale. **Results:** Between August and November 2014, 140 patients in the SMM group and 141 patients in the control group underwent colonoscopic examination. The total Ottawa score of the SMM group was significantly lower than that of the control group (5.47 ± 1.74 vs. 5.97 ± 1.78 , $p = 0.1018$). These results were particularly prominent in the younger age group; the total Ottawa score of the SMM group under 40 years of age was significantly lower than that of the control group under 40 years of age. **Conclusion:** We identified that sending educational video clips via SMM could result in better bowel preparation, especially in the younger age group.

Keywords: colonoscopy, bowel preparation, education

EE-0174 (PE-0050) Colonic polypoid vascular ectasia treated by a polypectomy with an endoloop**Authors:** SANG HOON LEE; SUNG CHUL PARK**Affiliation:** Department of Internal Medicine-GI/Hepatology, Kangwon National University Hospital, Chuncheon, Republic of Korea

Background and Aim: Colonic vascular ectasia is a potential and frequent cause of lower intestinal bleeding in the elderly. Generally, vascular ectasias appear as flat or slightly elevated bright red lesions, whereas a pedunculated appearance is extremely rare. We present a case of a large pedunculated polypoid vascular ectasia of the colon, which was successfully treated with endoscopic polypectomy with a detachable snare. **Methods:** A 63-year-old female was admitted to our hospital with intermittent abdominal distension for 1 year. She had no history of underlying disease, and there were no findings in colonoscopy 2 years ago. Colonoscopic examination showed a 3.0-cm-sized bluish-red colored polypoid mass at ileocecal valve. Abdominopelvic CT showed that there is a 3.0-cm-sized ovoid and homogenous low density mass in proximal ascending colon. Endoscopic polypectomy was performed. Colonic mass was looped with a snare and resected at the lower third of the stalk. After resection, the mucosal defect was closed using endoclips. After the procedure, the patient discharged without complications. **Results:** Histopathologic findings showed cystic dilated blood vessels and endothelial cells, and these result were accordance with a diagnosis of vascular ectasia with a polypoid mass. Colonic vascular ectasia was diagnosed. At 4-month follow-up, colonoscopy showed the scar at ileocecal valve. **Conclusion:** Our case suggests that colonic vascular ectasia could present as a single, pedunculated mass. Furthermore, the colonic mass can be safely removed by endoscopic polypectomy with detachable snare.

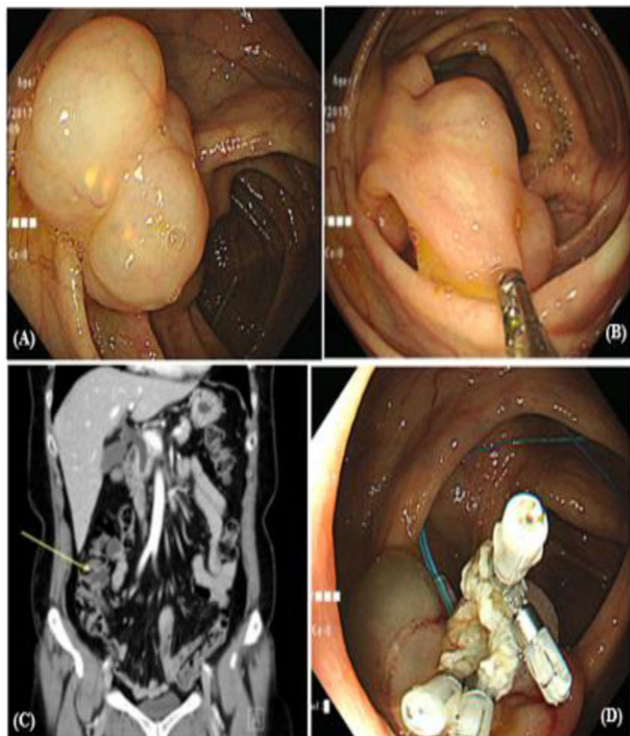
Keywords: colonic vascular ectasia, detachable snare

Figure 1 (A, B) Colonoscopic findings show a 3 cm-sized, bluish-red polypoid lesion at the ileocecal valve with a tenting sign indicated by the forceps. (C) Abdominopelvic CT findings show an ovoid and low-density mass measuring about 3.0 cm in size in the proximal ascending colon. (D) Hemoclips are used to prevent bleeding from the polypectomy site.

EE-0199 (PE-0051) Outcomes of same-day endoscopic mucosal resection for difficult colorectal polyps referred by Local Endoscopy Center**Authors:** SUNG HO SHIN; JAE SUNG AHN; JIN GU KANG; SEUNG IN SEO; HYOUNG SU KIM; WOON GEON SHIN; MYOUNG KUK JANG; JIN HEON LEE; HAK YANG KIM**Affiliation:** Department of Internal Medicine-GI/Hepatology, Kangdong Sacred Heart Hospital, Seoul, Republic of Korea

Background and Aim: The definition of a “difficult polyps” (DP) refers to polyps not amenable to endoscopic removal by the average endoscopist, it requires referral to a more experienced endoscopist. Most referred colorectal polyps are resected after initial colonoscopy; however, it needed repeated bowel preparation. The aims of this study were to determine the characteristics of referred difficult polyps and outcomes of endoscopic mucosal resection (EMR) when performed at the same-day colonoscopy.

Methods: DPs from local endoscopy centers were referred to Kangdong Sacred Heart Hospital’s endoscopy center at the same day of initial colonoscopy from January 2017 to December 2017. We analyzed clinical characteristics of DPs, outcomes and adverse events of the same-day EMR.

Results: A total of 108 patients with 390 polyps were referred for EMR. The mean size of DPs was 12.6 mm (range 4–30 mm), 42.6% were located in right side of colon and 56.5% of DPs were sessile polyps. Histopathology revealed 51 tubular adenomas (47.2%), 14 serrated adenomas (13%), 7 villous adenomas (6.5%), 12 hyperplastic polyps (11.1%), 2 lipomas (1.9%), 3 neuroendocrine tumors (2.8%), and 19 adenocarcinoma (17.6%). En bloc resection was performed in 96 patients (89%). There was one patient with positive resection margin at histopathology and managed with adjunctive APC. Immediate bleeding occurred in 42 patients who were managed with clip closure, and there were delayed bleeding in two patients. In multivariable analysis, large polyp size > 20 mm ($P = 0.003$) and sessile polyps ($P = 0.016$) were independent predictors for piecemeal resection at the same-day colonoscopy. **Conclusion:** Most DPs were sessile and flat adenomas; however, en bloc resection rate was high at the same-day EMR. En bloc resection was mostly affected by polyp size and shape. Future long-term prospective study may be needed to confirm outcomes of same-day EMR of DPs.

Keywords: colonoscopy, difficult polyp, endoscopic mucosal resection, outcome

EE-0213 (PE-0052) Predictors of high-risk adenoma occurrence at surveillance colonoscopy in patients who undergo colorectal adenoma removal

Authors: JIN LEE; MYUNGKWAN KO; SU-JIN JEONG; TAE YOUNG PARK; YONG EUN PARK; JOON HYUK CHOI; NAE-YUN HEO; JONGHA PARK; SEUNG HA PARK; YOUNG SOO MOON; TAE OH KIM

Affiliation: Department of Internal Medicine-GI/Hepatology, Inje University Haeundae Paik Hospital, Busan, Republic of Korea

Background and Aim: Surveillance colonoscopy is recommended after polypectomy because adenoma recurrence is common. The aim of this study was to evaluate the predictors of high-risk adenoma occurrence at surveillance colonoscopy in patients who undergo colorectal adenoma removal and to clarify the association between age and recurrent colorectal adenoma. **Methods:** This retrospective study included 563 patients who had colorectal adenomas at baseline colonoscopy and who underwent surveillance colonoscopy. The risk factors for recurrent adenoma were evaluated, and the 5-year cumulative incidence rates of overall and high-risk adenoma were compared according to age group. **Results:** During a mean follow-up period of 3.1 years, 305 (54.2%) patients had overall adenoma recurrence, and 80 (14.2%) patients had high-risk adenoma at surveillance colonoscopy. In a multivariate analysis, old age (≥ 60 years) and presence of multiple adenomas (three or more) were significantly associated with high-risk adenoma ($p = 0.002$ and 0.006 , respectively). The 5-year cumulative incidence rates of high-risk adenoma were 7.4%, 16.7%, and 24.1% in the < 50 , 50–59, and ≥ 60 years group, respectively ($p < 0.001$). **Conclusion:** Old age (≥ 60 years) and presence of multiple adenomas (three or more) were strongly associated with the occurrence of high-risk adenoma at surveillance colonoscopy. The 5-year cumulative incidence of high-grade adenoma was significantly high in the old age group. **Keywords:** age, high-risk adenoma, predictors, recurrent colorectal adenoma, surveillance colonoscopy

EE-0218 (PE-0053) The safety of coolprep (bowel preparation for colonoscopy) in patients with glucose-6-phosphate dehydrogenase deficiency in Korea

Authors: JEE SUN JEONG; HIUN-SUK CHAE; HYUN-HO CHOI; HYUNG-KEUN KIM; SEUNG-PYO HONG; MIN-WOO JUNG; YOUNG-KI KIM; SANG-WOO KIM; SUNG-SOO KIM

Affiliation: Department of Internal Medicine-GI/Hepatology, The Catholic University of Korea Uijeongbu St. Mary's Hospital, Uijeongbu, Republic of Korea

Background and Aim: Glucose-6-phosphate dehydrogenase (G6PD) deficiency is a genetic disorder that causes X chromosome inheritance with a worldwide prevalence of 4.9%. Colonoscopy is the standard method for colorectal cancer screening, and coolprep is widely used for bowel preparation. The coolprep contains ascorbic acid, and ascorbic acid is known to cause hemolytic anemia when administered in a high dose to G6PD deficiency patients. We investigated the prevalence of G6PD deficiency in Korea and the safety of using coolprep in these patients. **Methods:** Among patients who were scheduled to do a colonoscopy with coolprep for health screening, a total of 66 patients enrolled in our study. The enzyme G6PD was checked to confirm G6PD deficiency before colonoscopy. Only if G6PD deficiency was diagnosed, we decided to conduct a hemolytic anemia-related test on the day of the colonoscopy and 1 week later. **Results:** The mean age of patients was 62.03 ± 13.22 years, mean hemoglobin was 13.91 ± 1.47 g/dL, mean hematocrit was $41.54 \pm 3.88\%$, mean total bilirubin was 0.69 ± 0.25 mg/dL, and mean lactate dehydrogenase was 394 ± 74.50 U/L. In the urinalysis, urobilinogen was not detected in these patients. None of the patients had elevated the enzyme G6PD. There were no complications related to colonoscopy after taking coolprep. **Conclusion:** Since the prevalence of G6PD deficiency is very rare in Korea, it is thought that colonoscopy using coolprep for bowel preparation is safe. **Keywords:** G6pd deficiency, coolprep, colonoscopy

EE-0227 (PE-0054) A study on the risk factors of electrocoagulation syndrome after colorectal endoscopic submucosal dissection, large cohort study

Authors: JINWOO KIM; JUN LEE; SEONG-JUNG KIM; JOO-YEON CHO; CHAN-GUK PARK

Affiliation: Department of Internal Medicine-GI/Hepatology, Chosun University Hospital, Gwangju, Republic of Korea

Background and Aim: Endoscopic submucosal dissection (ESD) is a novel endoscopic procedure that enables en block resection of benign colorectal lesion and early colorectal cancer. Although electrocoagulation syndrome is a well-known complication of colorectal polypectomy, a few studies of electrocoagulation syndrome after colorectal ESD have reported. So we aimed to investigate the incidence and clinicopathologic risk factors associated with electrocoagulation syndrome after colorectal ESD. Especially, including the use of CO₂ gas. **Methods:** We conducted a retrospective analysis of the medical records of all patients (enrolled 198 of 294 patients) who were treated with colorectal ESD from January 2013 to October 2017. Incidence, risk factor, outcome of coagulation syndrome after ESD were evaluated and analyzed. **Results:** Post-ESD electrocoagulation syndrome (PEECS) occurred in 51 patients (25%). All PEECS patients were cured with conservative treatment. In the PEECS group, the size of the resected specimen was larger, the procedure time was longer, lesion with fibrosis and submucosal invasion were more than non-PEECS group. Also, there was more cancer lesion in the PEECS group. Especially the use of CO₂ gas resulted in a statistically decrease in PEECS incidence. Result from multivariate analysis, lesion with fibrosis (odd ratio [OR] 11, 95% confidence interval [95% CI] 2.9–42), lesion size larger than 4 cm (OR 17, 95% CI 19–150) were independent risk factor for PEECS. The use of CO₂ gas was not statistically significant, but it induced less PEECS (OR 0.44 95% CI 0.16–1.21, $P < 0.112$). **Conclusion:** All PEECS patients were cured with conservative treatment. Lesion with fibrosis, lesion size larger than 4 cm were independent risk factor for PEECS. Therefore, caution should be exercised when performing colon ESD in patient with lesion with fibrosis or lesion size larger than 4 cm.

Keywords: Post-ESD electrocoagulation syndrome (PEECS, size of the resected specimen, procedure time, lesion with fibrosis, and submucosal invasion, CO₂ gas)

EE-0259 (PE-0055) Usefulness of colonic tattooing using indocyanine green in patients with colorectal tumors

Authors: JAE HO PARK[1]; HEE SEOK MOON[1]; IN SUN KWON[2]; GEE YOUNG YUN[1]; SEO HEE LEE[1]; DAE HWA PARK[1]; JU SEOK KIM[1]; SUN HYUNG KANG[1]; EAUM SEOK LEE[1]; SEOK HYUN KIM[1]; JAE KYU SUNG[1]; BYUNG SEOK LEE[1]; HYUN YONG JEONG[1]

Affiliation: Departments of [1]Internal Medicine-GI/Hepatology, [2] Clinical trial center, Chungnam National University Hospital, Daejeon, Republic of Korea

Background and Aim: The aim of this study is to prove that tattooing using indocyanine green (ICG) is beneficial in the reduction of operation time, postoperative management, and to prove its usefulness according to stage and type of laparoscopic surgery. **Methods:** From Jan 2012 to Dec 2016, all patients underwent laparoscopic colonic surgery were retrospectively screened, and 1010 patients with colorectal neoplasms were included. Their lesions were tattooed with ICG the day before operation. The tattooed group (TG) included 114 patients, and the non-tattooed group (NTG) were selected by propensity score matching of subjects based on age, sex, tumor staging, and operation method ($n = 228$). In total, 342 patients were enrolled. Between the groups, the change in (Δ , preoperative–postoperative) hemoglobin and albumin, operation time, hospital stay, oral ingestion period, transfusion, and perioperative complications were compared. **Results:** Preoperative TG had a shorter operation time ($P = 0.007$), hospital stay ($P = 0.003$), and postoperative oral ingestion period ($P < 0.001$). Δ Hemoglobin ($P < 0.001$) and Δ albumin ($P < 0.001$) levels in the TG showed little difference. On comparison of patients with early and advanced tumor stages, early-stage colon cancer patients had better results for operation time, hospital stay, oral ingestion period, Δ hemoglobin, and Δ albumin than did advanced stage patients. Operation methods affected the results, and laparoscopic anterior resection (LAR) showed similar results. However, for left and right hemicolectomy, both groups showed no difference in operation time or hospital stay. **Conclusion:** Preoperative tattooing with ICG is useful for laparoscopic colectomy, especially in early-stage colon cancer and LAR.

Keywords: endoscopic tattoo, indocyanine green, colorectal neoplasm, laparoscopic surgery, perioperative

Perioperative parameters

Staging		Tattooed group (N=102)	Non-tattooed group (N=198)	P-value
Early (Stage 0 + I + IIa + IIb + IIc) (N = 239)	Operation time (minutes)	172.70 ± 48.87	190.34 ± 60.18	0.025
	Delta Hb	0.86 ± 0.79	2.16 ± 1.16	<0.001
	Delta Alb	0.40 ± 0.47	1.07 ± 0.39	<0.001
	Hospital stay(Days)	9.37 ± 2.91	11.53 ± 8.56	0.005
	Oral intake(Days)	1.49 ± 0.87	2.68 ± 1.16	<0.001
Advanced (Stage IIIa + IIIb + IIIc) (N = 82)	Operation time (minutes)	177.91 ± 56.74	195.69 ± 64.59	0.278
	Delta Hb	0.50 ± 0.71	2.05 ± 1.27	<0.001
	Delta Alb	0.39 ± 0.41	1.06 ± 0.41	<0.001
	Hospital stay(Days)	10.74 ± 5.00	12.23 ± 8.53	0.449
	Oral intake(Days)	1.83 ± 1.23	3.31 ± 3.62	0.064
Operation method		Tattooed group (N=88)	Non-tattooed group (N=198)	P-value
Laparoscopic anterior resection (N=160)	Operation time(minutes)	157.68 ± 43.42	180.33 ± 58.65	0.007
	Delta Hb	0.86 ± 0.79	2.16 ± 1.23	<0.001
	Delta Alb	0.41 ± 0.52	1.05 ± 0.41	<0.001
	Hospital stay(Days)	8.79 ± 2.33	10.26 ± 5.79	0.024
	Oral intake(Days)	1.43 ± 0.79	2.85 ± 1.83	<0.001
Lt. hemicolectomy (N=28)	Operation time(minutes)	206.3 ± 33.07	219.61 ± 60.67	0.45
	Delta Hb	0.35 ± 0.50	2.19 ± 1.14	<0.001
	Delta Alb	0.40 ± 0.29	1.09 ± 0.40	<0.001
	Hospital stay(Days)	12.00 ± 5.85	11.28 ± 4.49	0.72
	Oral intake(Days)	1.7 ± 0.82	2.5 ± 0.70	0.012
Rt. Hemicolectomy (N=95)	Operation time(minutes)	186.00 ± 49.35	197.14 ± 64.89	0.37
	Delta Hb	0.73 ± 0.68	2.06 ± 1.08	<0.001
	Delta Alb	0.61 ± 0.43	1.04 ± 0.38	<0.001
	Hospital stay(Days)	10.36 ± 3.92	10.71 ± 5.25	0.76
	Oral intake(Days)	1.66 ± 0.96	2.74 ± 1.36	<0.001
Univariate analysis		OR(95% CI)	P-value	Multivariate analysis
		OR(95% CI)	P-value	OR(95% CI)
Operation time (minutes)		0.994(0.990-0.998)	0.008	0.999(0.993-1.006)
Delta Hb		0.149(0.096-0.231)	<0.001	0.207(0.119-0.361)
Delta Alb		0.021(0.009-0.049)	<0.001	0.056(0.021-0.145)
Hospital stay (Days)		0.937(0.886-0.991)	0.023	0.987(0.909-1.071)
Oral intake (Days)		0.259(0.181-0.371)	<0.001	0.417(0.280-0.621)

EE-0271 (PE-0056) Quality of bowel preparation for colonoscopy in patients with a history of abdomino-pelvic surgery: Retrospective cohort study

Authors: BUN KIM[1]; BYUNG CHANG KIM[1]; JEONGSEON KIM[2]; HYUN JIN OH[3]; KUM HEI RYU[3]; BUM JOON PARK[3]; DAE KYUNG SOHN[1]; CHANG WON HONG[1]; KYUNG SU HAN[1]

Affiliation: Departments of [1]Center for Colon Cancer, Center for Cancer Prevention and Detection, [2]Department of Cancer Biomedical Science, [3]Center for Cancer Prevention and Detection, National Cancer Center, Goyang, Republic of Korea

Background and Aim: Prior abdomino-pelvic (AP) surgery is related to difficult colonoscopy and can affect bowel preparation quality. However, according to the prior AP surgery type, bowel preparation quality varied among studies. We examined the relationship of the prior AP surgery type with bowel preparation quality in a large-scale retrospective cohort. **Methods:** In the health screening cohort of the National Cancer Center, 12,881 participants who underwent screening or surveillance colonoscopy between June 2007 and December 2014 were included. Personal data were collected by reviewing patient medical records. Bowel preparation quality was assessed using the Aronchick scale and categorized as satisfactory for excellent to good bowel preparation or unsatisfactory for fair to inadequate bowel preparation. **Results:** A total of 1,557 (12.1%) participants had an AP surgery history. The surgery type was colorectal surgery ($n = 44$), gastric/small intestinal surgery ($n = 125$), appendectomy/peritoneum/laparotomy ($n = 476$), cesarean section ($n = 278$), uterus/ovarian surgery ($n = 317$), kidney/bladder/prostate surgery ($n = 19$), or liver/pancreatobiliary surgery ($n = 96$). The proportion of satisfactory bowel preparation was 70.7%. In the multivariate analysis, unsatisfactory bowel preparation was related to gastric/small intestinal surgery (OR=1.764, 95% CI = 1.230–2.532, $p = 0.002$). However, the other surgery types did not affect bowel preparation quality. Current smoking, diabetes, and high body mass index were the risk factors of unacceptable bowel preparation. **Conclusion:** Only gastric/small intestinal surgery was a potential risk factor for poor bowel preparation. Further research on patients with a history of gastric/small intestinal surgery to determine appropriate methods for adequate bowel preparation is mandatory.

Keywords: postoperative period, colonoscopy, bowel preparation, cohort study

EE-0279 (PE-0057) Predictive factors for inadequate bowel preparation using low-volume polyethylene glycol plus ascorbic acid for an outpatient colonoscopy: A single-center prospective observation study

Authors: SEUNG YONG SHIN; JAE JUN PARK; KYEONG SEON GA; IN YOUNG KIM; YOO MI PARK; DA HYUN JUNG; JIE HYUN KIM; YOUNG HOON YOON; HYOJIN PARK

Affiliation: Department of Department of Internal Medicine, Gangnam Severance Hospital, Seoul, Republic of Korea

Background and Aim: Low-volume polyethylene glycol (PEG) plus ascorbic acid (Asc) solutions are widely used for bowel cleansing before colonoscopy due to its superior patient acceptability and similar efficacy compared with standard volume PEG. This study aimed to investigate the pre-endoscopic predictive factors for inadequate preparation in subjects receiving low-volume PEG plus Asc. **Methods:** A prospective study was performed at Gangnam Severance Hospital, Korea, from June 2016 to December 2016. All participants received low-volume PEG plus Asc solutions for outpatients colonoscopy. The split-dose bowel preparation was administered in subject with morning colonoscopy, meanwhile, same day bowel preparation was used for afternoon colonoscopy. The subjects who took less than 75% of the preparation solution were excluded for analysis. **Results:** Seven hundred and fifteen patients were enrolled (mean age 56.1 ± 14.3 years, 54.4% male), of which 138 (19.3%) had an inadequate bowel preparation. In multivariable analysis, low (less than 70%) compliance for 3 days low-residual diet (odd ratio 2.078, 95% CI 1.286–3.358, $P = 0.003$) and brown liquid or brown solid rectal effluent (compared with clear or semiclear effluent) (OR 5.810, 95% CI 1.277–26.439, $P = 0.023$) were found as an independent predictors for inadequate preparation. **Conclusion:** The lack of adherence for low-residue diet recommendation and brownish colored rectal effluent were independent risk factors for inadequate bowel preparation using low-volume PEG plus Asc for outpatients colonoscopy. These predictive factors may be useful in guiding additional intervention to improve quality of bowel preparation.

Keywords: colonoscopy, low-volume polyethylene glycol, ascorbic acid, inadequate bowel preparation, predictive factors

EE-0281 (PE-0058) Clinical outcomes and patients satisfaction for novel patient referral system called “same-day polypectomy”

Authors: SEUNG YONG SHIN; JAE JUN PARK; YOUNG HOON YOON; JIE-HYUN KIM; DA HYUN JUNG; HYOJIN PARK

Affiliation: Department of Internal Medicine-GI/Hepatology, Gangnam Severance Hospital, Seoul, Republic of Korea

Background and Aim: Substantial number of patients who diagnosed with polyps on screening colonoscopy undergo subsequent colon polypectomy on a separate day at referral hospital. We developed novel patient referral system called “same-day polypectomy” that performs colon polypectomy in tertiary hospital after same day referral from private clinics. The aim of this study was to compare the clinical outcomes between conventional elective polypectomy and “Same-day polypectomy” and to evaluate the patient’s satisfaction with this novel system. **Methods:** We retrospectively reviewed prospectively enrolled colonoscopy database in a single referral center. A total of 122 patients were referred to Gangnam Severance Hospital for polypectomy between July 2017 and December 2017. Among them, 57 patients received “same-day polypectomy,” and remaining 55 patients underwent conventional elective polypectomy. Polyp characteristics, complications, degree of bowel cleanliness using Boston Bowel Preparation Scale (BBPS) were compared between these two groups. Patients’ satisfaction for the “same-day polypectomy” was assessed through questionnaires. **Results:** There were no significant differences in the location and average number of resected polyps between two groups. However, the polyps in “same-day polypectomy” group were smaller in size than those of elective polypectomy group (6.3 ± 3.2 mm vs. 10.9 ± 8.7 mm, $P < 0.001$) and were more frequent in polypoid type. Moreover, mean total BBPS score was lower in “same-day polypectomy” group than in elective polypectomy group (6.8 ± 1.6 vs. 8.4 ± 1.0 , $P < 0.001$). Meanwhile, procedure related complications were not identified in both groups. Regarding patients’ satisfaction for “same-day polypectomy,” 95% of the patients were satisfied with this novel system and most common reason for satisfaction was absence of repeat bowel preparation (70.8%). **Conclusion:** Our novel “same-day polypectomy” is safe and acceptable patient referral system with high patients’ satisfaction.

Keywords: colon polypectomy, same-day polypectomy, clinical outcome, patients satisfaction

EE-0319 (PE-0059) Clinical outcome of patients after endoscopic resection for T1-stage colorectal cancer

Authors: HIROTSUGU EDA; HIROKAZU FUKUI; TOMOAKI KOUNO; AKIO TAMURA; TOMOHIRO OGAWA; TAKAHISA YAMASAKI; TAKUYA OKUGAWA; TAKASHI KONDO; KATSUYUKI TOZAWA; TOSHIHIKO TOMITA; TADAYUKI OSHIMA; JIRO WATARI; HIROTO MIWA

Affiliation: Department of Internal medicine-Gastroenterology, Hyogo College of Medicine, Nshinomiya, Japan

Background and Aim: Endoscopic resection does not necessarily warrant a complete curability for early colorectal cancers. In this regard, JSCCR Guidelines 2016 requires an additional surgical resection (ASR) if the endoscopically resected specimen conflict with the pathological criteria for submucosal invasion, histological-type, budding, and vertical margin. However, the patients whose lesions apply to those criteria sometimes choice no ASR. In this context, we have few information about the prognosis of such patients and therefore, we investigated the clinical outcome of patients after endoscopic resection for T1-stage colorectal cancer. **Methods:** A total of 42 patients whose T1-stage colorectal cancers were treated with endoscopic resection and subsequently required for ASR according to above criteria was investigated, retrospectively. The patients were subdivided into two groups with or without ASR, and their clinico-pathological features and prognosis were analyzed statistically. **Results:** Twenty-six patients (mean age 65.0 ± 2.2 years; M/F, 13/13; tumor size, 25.4 ± 2.9 mm) had an additional surgical resection, whereas 16 patients (mean age 72.2 ± 3.5 years; M/F, 7/9; tumor size, 22.7 ± 3.7 mm) did not. The distance of submucosal invasion tended to be longer in patients with ASR (3791 ± 884 vs 1577 ± 407 mm). The positivity of lymphatic invasion was significantly higher in the specimens from patients with ASR. Recurrent was observed in 4 (25%) of 16 patients without ASR and in 1 of 26 (3.8%) patients with ASR. Log-rank test revealed that the recurrent rate is significantly worse in patients without ASR ($p < 0.05$). During the observational period (5–83 months), no patients died of colorectal cancer although three patients without ASR died of other diseases. **Conclusion:** The patients with T1-stage colorectal cancer should have ASR to prevent recurrence if their endoscopically resected lesions don’t fulfill the criteria of pathological curability in JSCCR Guidelines 2016.

Keywords: T1-stage colorectal cancer, endoscopic resection, additional surgical resection

EE-0339 (PE-0060) Colonoscopy quality indication: Caution in the areas and directions

Authors: JUNGMIN KIM; YEHYUN PARK; SOOJUNG PARK; JAEHEE CHEON; TAEIL KIM; WONHO KIM

Affiliation: Department of Department of Internal Medicine and Institute of Gastroenterology, Yonsei University College of Medicine, Seoul, Republic of Korea

Background and Aim: The prevalence of colorectal cancer has recently increased in Korea, and colonoscopy has been performed with a health checkup. Managing the quality of colonoscopy can reduce the incidence of colorectal cancer and complications. **Methods:** Between March 2015 and February 2018, 31,034 colonoscopies and 6,077 sigmoidoscopies were analyzed retrospectively, and management of qualities and complications of colonoscopy were analyzed. **Results:** Colonoscopy showed an increase from 819.7 (746.61–892.79) to 883.6 (835.61–931.68), and sigmoidoscopy showed an increase from 167.9 (159.11–176.69) to 172.3 (159.79–184.78). Abdominal pain, 61 (6.75%), surveillance of colorectal cancer, 121 (13.3%), and health screening, 208 (22.6%) were the highest rates of indication at colonoscopy. PDR was measured from 48.7% to 53.7%, and there were no statistically significant differences when viewed on a quarterly basis. ($P = 0.453$) The average annual bleeding complication rate was 0.19% to 0.25% and the perforation complications were 0.04% to 0.11%. Above fair in Aronchick Bowel preparation Scale were from 87.8% to 89.2%. Bleeding (65.8%) and perforation (53.6%) were more common in the left colon than in the right colon; 3 o'clock to 6 o'clock in endoscopic view is the most common complication site in bleeding (63.2%) and perforation (40.6%). **Conclusion:** Proper endoscopic quality management is required, and endoscopy should be performed with caution in the areas and directions where complications occur easily.

Keywords: colonoscopy, sigmoidoscopy, quality indicators, bleeding, perforation

The characteristics of complications

Table. The size, areas and directions of complication

Perforation (n = 38)		Bleeding (n = 192)	
Size	n (%)	Size	n (%)
≥ 1cm	31	≥ 1cm	77 (33.0)
< 1cm	7	< 1cm	115 (67.0)
Area	n (%)	Area	n (%)
Rt. Colon	13 (34.2)	Both	18 (9.4)
Cecum	4 (10.5)	Rt. Colon	89 (46.4)
A-colon	3 (7.9)	IC valve	7 (3.6)
Hepatic flexure	4 (10.5)	Cecum	9 (4.7)
T-colon	5 (13.2)	A-colon	41 (21.4)
Lt. Colon	25 (65.8)	Hepatic flexure	11 (5.7)
Splenic flexure	1 (2.6)	T-colon	21 (10.9)
D-colon	1 (2.6)	Lt. Colon	103 (53.6)
S-colon	12 (31.6)	Splenic flexure	3 (1.6)
Rectum	8 (21.1)	D-colon	20 (10.4)
Direction	n (%)	S-colon	39 (20.3)
12 o'clock to 3 o'clock	4 (10.5)	Rectum	41 (21.4)
3 o'clock to 6 o'clock	24 (63.2)	Direction	n (%)
6 o'clock to 9 o'clock	7 (18.4)	12 o'clock to 3 o'clock	33 (17.2)
9 o'clock to 12 o'clock	3 (7.9)	3 o'clock to 6 o'clock	78 (40.7)
		6 o'clock to 9 o'clock	43 (22.5)
		9 o'clock to 12 o'clock	37 (19.3)

EP-0098 (PE-0061) Safety and efficacy of low-volume preparation in the elderly: Oral sulfate solution in day before and split-dose regimens (SEE SAFE) study

Authors: MIN SEOB KWAK[1]; JAE MYUNG CHA[1];

HYO-JOON YANG[2]; DONG IL PARK[2];

KYEONG OK KIM[3]; JUN LEE[4]; JEONG EUN SHIN[5];

YOUNG-EUN JOO[6]; JONGHA PARK[7];

JEONG-SIK BYEON[8]; HYUN GUN KIM[9]

Affiliation: [1]Department of Internal Medicine-GI/Hepatology, Kyung Hee University Hospital at Gangdong, [2]Department of Internal Medicine-GI/Hepatology, Kangbuk Samsung Medical Center, [8] Department of Internal Medicine-GI/Hepatology, Asan Medical Center, [9]Department of Internal Medicine, Soon Chun Hyang University Seoul Hospital, Seoul, [3]Department of Internal Medicine, Yeungnam University Medical Center, Daegu, [4]Department of Internal Medicine, Chosun University Hospital, [6]Department of Internal Medicine, Chonnam National University Hospital, Gwangju, [5] Department of Internal Medicine, Dankook University Hospital, Cheonan, and [7]Department of Internal Medicine, Inje University Haeundae Paik Hospital, Pusan, Republic of Korea

Background and Aim: The use of a low-volume bowel cleansing agent is associated with a greater willingness to undergo repeat colonoscopy. Oral sulfate solution (OSS) is a recently approved low-volume agent; however, its efficacy and safety in the elderly population remain unclear. We aimed to evaluate the efficacy, safety, and acceptability of the OSS preparation, in comparison to those of a standard polyethylene glycol (4L PEG) preparation, in elderly patients. **Methods:** A multicenter, randomized, investigator-blinded study was conducted. Participants were randomized to receive OSS or 4L PEG with a split-dose regimen. Bowel cleansing efficacy was assessed using the Boston Bowel Preparation Scale (BBPS). Acceptance, satisfaction, and preparation-related symptoms were recorded. Additionally, blood parameters were analyzed for electrolyte abnormalities and nephrotoxicity. **Results:** A total of 193 patients were analyzed. Mean BBPS scores for the entire ($p = 0.010$) and right colon ($p = 0.001$) were significantly higher in the OSS group than in the 4L PEG group. The severity of clinical adverse event and frequency of acute kidney injury were similarly low, and no clinically meaningful electrolyte changes were identified. Self-reported scores regarding amount ($p < 0.001$) and feeling ($p = 0.007$), as well as overall satisfaction ($p = 0.001$) and willingness to repeat the preparation (92.8% vs. 67.7%; $p < 0.001$), were significantly better in the OSS group than in the 4L PEG group. **Conclusion:** In elderly individuals, OSS with a split-dose regimen has greater acceptability and comparable efficacy in bowel cleansing compared to 4L PEG. Clinical trials registration number: NCT03112967.

Keywords: colonoscopy, cathartics, safety, treatment outcome, aged

EP-0111 (PE-0062) Endoscopic submucosal dissection in a patient with previous colon cancer surgery

Authors: SEONGDAE LEE[1]; EUI-GON YOUK[1]; KEE-HO SONG[1]; WHA-YOUNG LEE[2]

Affiliation: [1]Department of Surgery, Daehang hospital, and [2] Department of Internal Medicine, Ganam Cha Hospital, Seoul, Republic of Korea

Background and Aim: Endoscopic submucosal dissection (ESD) is known as an excellent treatment modality for en bloc resection of large polyp and early colorectal cancer. However, ESD is considered challenging and rarely performed to remove multiple polyps in patients who have undergone colon cancer surgery. We would like to report a successful experience of removing three large polyps safely by ESD in a patient with previous history of surgery. **Methods:** A 75-year-old male patient with large polyps found during screening colonoscopy was referred to our hospital. He had a low anterior resection and chemoradiotherapy for rectal cancer 23 years ago. **Results:** A total of 29 polyps were detected during therapeutic procedure; 26 polyps were removed by EMR, cold snare, and cold biopsy. Three large polyps were serially treated through ESD. The first polyp was Laterally Spreading Tumor (LST)-nodular mixed (NM) type in hepatic flexure. The size was 31 × 29 mm and the removal time was 20 min. Secondly, a 75 × 55 mm sized polyp was located in the splenic flexure, which was flat elevated type, and the removal procedure took 162 min. The third polyp was located from the dentate line to just below the anastomosis site. The size of the LST-NM was 52 × 45 mm and the procedure time was 78 min. The patient was discharged 2 days after the procedure without any complications such as fever, bleeding, and perforation. All three polyps were histopathologically confirmed as tubular adenomas. **Conclusion:** Even though polyps in patient with previous colon cancer surgery are large and multiple, it can be removed by endoscopy without surgical treatment as in this case. However, it is important to perform ESD with careful attention to improve the completeness of the procedure and to avoid unnecessary surgery.

Keywords: colorectal neoplasm, multiple polyps, endoscopic submucosal dissection

OE-0217 (PE-0063) Relationship between colonoscopic withdrawal times and the non-detection of adenomas

Authors: RYOICHI NOZAKI; YASUSHI NAKAMURA; SATOSHI TAKAYANAGI; MASATAKE MURAOKA; KAZUTAKA YAMADA

Affiliation: Department of Gastroenterology, Coloproctology Center Takano Hospital, Kumamoto, Japan

Background and Aim: Quality indicators (QI) evaluate the quality of colonoscopy, and the most significant QI is the adenoma detection rate (ADR). Moreover, the colonoscopic withdrawal time (observation time) is an important technical factor in QI. The recommended observation time in western countries such as the USA and UK is 6 min or longer. However, in Asian countries, only a few studies have been done on the relationship between observation time and ADR. We retrospectively analyzed the relationship between observation time in colonoscopy and the non-detection of adenomas. **Methods:** One hundred sixty cases with colorectal polyps identified in the first colonoscopy and who underwent a second colonoscopy and polypectomy 1 to 3 months later were enrolled in this study. The first colonoscopy screening was performed by 17 physicians, and the second colonoscopy and treatment was performed by one experienced physician who has performed approximately 40,000 colonoscopic examinations. The second colonoscopy findings were defined as the optimal criterion (gold standard). The relationship between the observation time of the first colonoscopy and the number of undetected colorectal polyps was then analyzed. Only neoplastic polyps (adenomas) 5 mm or larger were analyzed. The time spent in the non-observation period (i.e. biopsy and treatment) was excluded and only the time spent in pure observation was compared. **Results:** One hundred and three out of 367 polyps (28%) treated endoscopically in the second colonoscopy went undetected. The mean observation time of the second colonoscopy was 15.2 min. The number of undetected polyps was significantly more in observation times of less than 6 min (1.1 ± 1.3 polyps less than 6 min vs. 0.6 ± 0.8 polyps 6 min or longer, $P = 0.0182$). **Conclusion:** The observation time when performing colonoscopy should be at least 6 min or longer.

Keywords: colonoscopic withdrawal time, quality indicator

OE-0231 (PE-0064) A comparison of post-colonoscopy polypectomy outcomes: Patients on direct oral anticoagulants versus aspirin

Authors: YUNN CHENG NG[1]; SAU SHUNG FONG[2]; KHOON BENG CHUAH[1]

Affiliation: Departments of [1]Gastroenterology and Hepatology, [2] Surgery, Tan Tock Seng Hospital, Singapore, Singapore

Background and Aim: Direct oral anticoagulants (DOAC) are increasingly being prescribed for management of atrial fibrillation and thrombosis in Asia. Post-polypectomy bleeding (PPB) remains the most common complication of colonic polypectomy. Whilst risk of PPB in patients on aspirin has been well studied, data on outcome in patients on DOAC remain minimal. This study aims to compare post-colonoscopy polypectomy outcomes in patients on DOAC versus aspirin. **Methods:** Data of patients on DOAC (rivaroxaban and apixaban) who underwent colonoscopy with polypectomy over a 14-month period (Jan 2017 to Feb 2018) in Tan Tock Seng Hospital were collected using Computerised Patient Support System (CPSS). Patients on aspirin were recruited as control. Electronic records were reviewed for any hospital attendance 3 weeks post-procedure for colonoscopy-related complications. **Results:** Forty-four cases of colonoscopy with polypectomy performed were identified: 22 on DOAC and 22 on aspirin. All patients on DOAC had a creatine-clearance above 30 ml/min; 3 patients stopped DOAC 24 h, 13 patients stopped 48 h, and 6 patients stopped 3–7 days prior to colonoscopy. In the DOAC group, 3 polypectomies were performed via cold snare; 6/22 polypectomies had clips applied, 3 cases were done prophylactically. In the aspirin group, 8 polypectomies were performed via cold snare; 10/22 polypectomies had clips applied, 6 cases were done prophylactically. Polyp size ranged from 2–20 mm and were comparable between both groups. Twelve patients resumed DOAC 1 day, 4 patients at 2 days, and 4 patient at 3–14 days post polypectomy. No patients from either groups had post-colonoscopy polypectomy complications. **Conclusion:** DOAC appears as safe as aspirin in colonoscopy with polypectomy if stopped 24–48 h prior to procedure. Timing to resume DOACs is endoscopist-dependent but appears safe as early as 24 h post polypectomy. Cold snare polypectomy may also be safe in patients on DOAC if stopped 24–48 h prior to procedure.

Keywords: colonoscopy, post-polypectomy, bleeding, complication, direct oral anticoagulant

OE-0249 (PE-0065) Factors affecting polyp characteristics

Authors: MOHAMMADALI ZAD[1]; CUONG NGHI DO[2]; LUCY JOHNSTON[3]; MOHAMMED ALANSARI[4]

Affiliation: [1]Department of Gastroenterology, Logan Hospital, Logan, [2]Department of Medical Student, Griffith University, Gold Coast, [3]Department of Pediatrics, Monash Hospital, Melbourne, and [4]Department of Gastroenterology, Ballart Hospital, Ballart Central, Australia

Background and Aim: Further knowledge of the effect patient factors have on polyps and associations between polyp characteristics would assist in risk stratification and urgency of colonoscopy. Our aims are to assess the effect age, sex, BMI, smoking, and DM has on polyp characteristics and to assess associations between location, size, and histological type of polyps. **Methods:** Prospective data collection of 784 colonoscopy patients between May 2012 and November 2014 at an Australian hospital. We recorded details of patient age, sex, BMI, COPD, and DM. We compared this to histological type, location, and size of polyps as summarized by endoscopy/biopsy reports. Clinically significant polyps were defined histologically as tubular adenomas (low-grade and high-grade), tubulovillous adenomas (high-grade and low-grade), adenocarcinomas, and inflammatory polyps. Nonsignificant polyps were defined as hyperplastic and hamartomatous polyps. Indications for colonoscopy were GI bleed (32.7%), surveillance (14.5%), screening (11.3%), anemia (9.4%), altered bowel habits (13.7%), abdominal pain (5.1%), and other (13.3%). **Results:** Males (mean = 6.8 mm, $p = 0.0405$) and diabetic patients (mean = 6.23 mm, $p = 0.0342$) were found to have statistically larger polyp sizes than female and non-diabetic counterparts. No patient characteristic were found to have statistically different rates of clinically significant polyps. Location and polyp size were compared and the hepatic (mean = 7 mm) and splenic flexures (mean = 7.38 mm) were found to have the largest polyps ($p = 0.0005$). Location and polyp histology were compared and the hepatic (100%) and splenic flexures (88.24%) were found to have the highest proportion of clinically significant polyps ($p < 0.0001$). **Conclusion:** Our study found that males and diabetics have statistically larger polyps. Further, polyps in the hepatic and splenic flexure were more likely to be clinically significant and larger polyps. These locations are typically difficult to visualize on endoscopy and suggest greater attention is needed.

Keywords: colonoscopy, polyp, diabetes, risk, male

OE-0273 (PE-0066) Bowel preparation: The basis for quality colonoscopy in geriatrics**Authors:** ZHEN XI JOEL LEE; KUO CHAO YEW**Affiliation:** Department of Internal Medicine-GI/Hepatology, Tan Tock Seng Hospital, Singapore, Singapore

Background and Aim: The 2017 UN Ageing Survey reported the population of Singapore at 5.71 million with 886,000 people (15.5%) greater than age 65. 47% of Singapore's total population will be at least 65 years old in 3 decades. Cancer surveillance is essential in the geriatric population. Good bowel preparation increases colonic adenoma detection rate. Achieving satisfactory bowel preparation depends on factors such as bowel preparation regimen and patient comorbidities. Literature on factors influencing bowel preparation in the elderly is however scarce. We sought to determine the potential factors that result in poor bowel preparation in this unique group of patients. **Methods:** We performed subgroup analysis on patient aged greater than 65 years old using information from bowel preparation database in our institution. It consisted of 611 inpatients who underwent colonoscopy at our hospital, from June 2015 to December 2015. Comparisons between patients with good/fair (Boston ≥ 5) and poor (Boston < 5) bowel preparation were made. **Results:** Three hundred ninety-three (64.3%) of our patients was of the geriatric population; 254 (64.6%) had good/fair bowel preparation, while 139 (35.4%) had poor bowel preparation; 41.2% of patients with diabetes mellitus had poor bowel preparation ($p = 0.05$). Male gender (38.2%, $p = 0.174$), dementia (20.8%, $p = 0.185$), and calcium channel blockers usage (30%, $p = 0.140$) were associated with poor bowel preparation outcomes. Nasogastric tube application did not improve bowel preparation outcome (good/fair 0.79%, $n = 2$; poor 5.04%, $n = 7$, $p = 0.011$). This difference is still significant after adjustment for confounders such as stroke and age ($p = 0.031$). **Conclusion:** A detailed evaluation into potential contributing factors among the geriatric population is necessary to better identify poor bowel preparation outcome. Successful bowel preparation rate can be increased by identifying patients with poor bowel preparation risk.

Keywords: bowel preparation, colonoscopy**OE-0316 (PE-0067) Investigation on the depth of resected specimen after underwater endoscopic mucosal resection for colorectal polyps with fibrosis or scar****Authors:** YUKI KANO; SATOSHI ASAI; EISUKE AKAMINE; KOSUKE ITO; HITOMI JIMBO; KENJI MATSUO; KOTARO TAKESHITA; TAKUMI ICHINONA; NAOKI FUJIMOTO**Affiliation:** Department of Gastroenterology, Tane General Hospital, Osaka, Japan

Background and Aim: Recently, underwater EMR (UEMR) was reported effective for the removal of the post EMR recurrent lesions which were difficult to be removed with conventional EMR. However, there has been no data reported about the depth of the resected specimen after UEMR. If the indication of UEMR is considered the same with that of conventional EMR, the resected specimen after UEMR should contain submucosal layer $\geq 1000 \mu\text{m}$. Therefore, we investigated the pathological depth of UEMR specimens. **Methods:** This was the single center retrospective study. All patients who underwent UEMR for colorectal lesions from April 2016 to May 2018 were included. In our institute, the indication of UEMR was as below: recurrent lesions after EMR, lesions with fold convergence or depression, LST-NG (nongranular type laterally spreading tumor) $< 2 \text{ cm}$. The lesions suspected submucosal invasive cancer were excluded. We evaluated the resection depth of submucosal layer pathologically. **Results:** A total of 24 patients underwent UEMR for 25 colorectal lesions. The mean age was 68 years and 63% of patients were male. The mean size of the lesion was 24 mm. En-block resection was obtained in 44% of the lesions. Endoscopic complete resection rate was 96%, median procedure time was 13 min, and there were no adverse events. Pathological results showed adenoma (84%), mucosal cancers (16%), and there were no submucosal cancers. The median resection depth of submucosal layer was $600 \mu\text{m}$, and the rate of the specimen which contained submucosal layer $\geq 1000 \mu\text{m}$ was 29%. **Conclusion:** Most of the resected specimens after UEMR for the colorectal lesions with fibrosis or scar did not contain submucosal layer $\geq 1000 \mu\text{m}$. Therefore, not UEMR but ESD could be better for the lesions with possible submucosal invasive cancer.

Keywords: underwater endoscopic mucosal resection, resection depth, the indication of UEMR, colorectal polyps with fibrosis or scar, submucosal layer

OE-0369 (PE-0068) Safety and efficacy of etomidate/midazolam and propofol/midazolam sedations for screening colonoscopy: A prospective, randomized controlled trial

Authors: JUNG MIN LEE; SEONG JI CHOI; HAN JO JEON; SEHYUN JANG; SEUNG HAN KIM; JAE MIN LEE; HYUK SOON CHOI; EUN SUN KIM; BORA KEUM; YOON TAE JEEN; HOON JAI CHUN; HONG SIK LEE; CHANG DUCK KIM

Affiliation: Department of Internal Medicine-GI/Hepatology, Korea University Anam Hospital, Seoul, Republic of Korea

Background and Aim: Recent studies demonstrated that etomidate was a safe sedative drug with non-inferior sedation effects. This study aimed to investigate whether etomidate/midazolam has fewer cardiopulmonary adverse events and non-inferior efficacy than propofol/midazolam for screening colonoscopy. **Methods:** A single-center, randomized, double-blind study prospectively enrolled 200 patients. Patients were divided into etomidate and propofol groups. The primary outcome was cardiopulmonary adverse events. The secondary outcomes were the proportion of patients with vital signs fluctuations (oxygen desaturation and transient hypotension), adverse events disturbing the procedure, and sedation-related outcomes. **Results:** Adverse cardiopulmonary events were higher in the propofol group than the etomidate group (65.0% vs. 51.0%, respectively; $P = 0.045$). Forty-six (46.0%) patients in the propofol group and 29 (29.0%) in the etomidate group had vital signs fluctuations (respectively, $P = 0.013$). Adverse events disturbing the procedure, including myoclonus, were not significantly different in both groups (etomidate: 20.0% vs. propofol: 11.0%; $P = 0.079$). Both groups had similar sedation-related outcomes. Multivariate analysis revealed that the etomidate group had a significant low risk for vital signs fluctuations (odds ratio: 0.427, 95% confidence interval: 0.230–0.792, $P = 0.007$). In addition, the longer the procedure, the more vital sign instability (odds ratio: 2.193, 95% confidence interval: 1.025–4.694, $P = 0.043$). **Conclusion:** Etomidate/midazolam for screening colonoscopy had more unstable hemodynamic response; therefore, we recommend using etomidate/midazolam for colonoscopy in patients with vulnerable risk factors.

Keywords: midazolam, etomidate, propofol, colonoscopy

OE-0516 (PE-0069) The safety of same-day regimen in patients with painless colonoscopy under propofol anesthesia

Authors: HONGBIN ZHU; DONGXU WANG; JIAN TIAN; JUN BAI

Affiliation: Department of Gastroenterology and Hepatology, PLA No.254 Hospital, Tianjin, China

Background and Aim: To explore the differences in the safety, efficiency, and tolerance of routine bowel preparation and same-day regimen in patients with painless colonoscopy under propofol anesthesia. **Methods:** The patients who were selected from May 2017 to December 2017 to the same day painless gastroscopy and colonoscopy were divided into the routine bowel preparation group and same-day regimen. The amount of gastric remnant fluid in the three groups was compared, and the adverse reactions of intestinal preparation quality, polyp detection rate, and sleep loss were compared in the patients with colonoscopy, and the factors affecting the amount of gastric residual fluid were analyzed. Variance analysis or chi-square test were used for statistical analysis, and the influencing factors of gastric residual volume were analyzed by multiple linear regression. **Results:** The amount of gastric liquid in the single line gastroscopy group was (26.5 + 14.9) mL, and the amount of gastric remnant liquid in the bowel preparation group was (26 + 17.1) mL, and the gastric residual liquid in the traditional bowel preparation group was (26 + 20.7) mL, the difference was not statistically significant ($P = 0.9955$). The intestinal preparation quality score (BBSP) was (6.9 + 1.2) scores on the day of intestinal preparation group (6.9 + 1.2), which was higher than that of the traditional intestinal preparation group (6.3 + 1.5), and the difference was statistically significant ($P = 0.0208$). The detection rate of polyps in the bowel preparation group was 35% (26/75), which was not significantly different from that in the conventional preparation group (40%, 23/58, $P = 0.5542$). The last time of taking medicine was related to the volume of gastric remnant ($P = 0.022$). **Conclusion:** Bowel preparation does not increase the risk of anesthesia and aspiration. It is safe, effective, and tolerable.

Keywords: painless, colonoscopy, residual gastric liquid

OE-0565 (PE-0070) Does prophylactic clip application before snare polypectomy decrease postpolypectomy bleeding in large pedunculated polyps?

Authors: JAE SEUNG SOH[1]; MYEONGSOOK SEO[2]; KYUNG-JO KIM[3]

Affiliation: [1]Department of Internal Medicine-GI/Hepatology, Hallym University Sacred Heart Hospital, Anyang, [2]Department of Internal Medicine-GI/Hepatology, Konkuk University Medical Center, Chungju, and [3]Department of Internal Medicine-GI/Hepatology, Asan Medical Center, Seoul, Republic of Korea

Background and Aim: Although prophylactic clip application before polypectomy may prevent postpolypectomy bleeding (PPB), the usefulness of prophylactic clip in large pedunculated polyps is not consistent in a few prospective randomized studies. This study was conducted to evaluate the efficacy of prophylactic clip applications and to investigate the predictors of PPB in large pedunculated colorectal polyps. **Methods:** A total of 137 pedunculated polyps (≥ 1 cm in size) in 116 patients were prospectively enrolled and randomized into either clip (Group A) or without clip application (Group B) and resected. Occurrence of immediate PPB graded as grade 1–4 and that of delayed PPB were compared. **Results:** Sixty-seven polyps were allocated in the Group A and 70 polyps in the Group B. In both groups, median polyp diameters were 15 mm ($P = 0.173$), and median stalk diameters were 3 mm ($P = 0.362$), respectively. A total of 28 (20.4%) episodes of immediate PPB of 137 polyps occurred, six (9.0%) in Group A and 22 in Group B (6/67 [9.0%] vs. 22/70 [31.4%], $P = 0.001$). However, no differences were observed between the two groups in terms of the occurrence of delayed PPB ($P = 0.943$). The prophylactic clip application decreased immediate PPB (odds ratio 0.319, 95% CI 0.135–0.753). In addition, polyp in size (≥ 20 mm) and stalk diameter (≥ 4 mm) increased the risk of immediate PPB. **Conclusion:** Clip application prior to polypectomy for pedunculated polyps ≥ 1 cm in size is effective in decreasing the occurrence of immediate PPB. Thus, clip applications should be considered before undergoing snare polypectomy, especially for a large polyp with thick stalk.

Keywords: postpolypectomy bleeding, clip, pedunculated polyps

OE-0571 (PE-0071) Patient factors determine cecal intubation time at colonoscopy

Authors: MOHAMMADALI ZAD[1]; CUONG DO[2]; LUCY JOHNSTON[3]; MOHAMMED ALANSARI[4]

Affiliation: [1]Department of Gastroenterology, Logan Hospital Logan, [2]Department of Medical Student, Griffith University, Gold Coast, [3]Department of Pediatrics, Monash Hospital, Melbourne, and [4]Department of Gastroenterology, Ballart Hospital, Ballart Central, Australia

Background and Aim: Cecal intubation (CI) time is often used as a surrogate to estimate difficulty of a colonoscopy. Shorter CI times have been associated with increased detection rates of important lesions. Our aim is to assess the association between patient factors (Gender, BMI, DM, IHD, COPD, Surgery History) and cecal intubation and extubation time during colonoscopy. **Methods:** Prospective data collection of 3295 consecutive patients between May 2012 and November 2014 at a regional hospital in Australia. We recorded the intubation and extubation time (minutes) of patients undergoing colonoscopy. We compared the median CI and cecal extubation (CE) times of patient groups with regard to Gender, BMI, DM, IHD, COPD, and Surgery Hx. Seventeen experienced endoscopists performed the colonoscopies, and data were collated by trained endoscopy nurses. Indications for colonoscopy were GI bleed (32.7%), surveillance (14.5%), screening (11.3%), anemia (9.4%), change in bowel habits (13.7%), abdominal pain (5.1%), and other (13.3%). **Results:** Median CI time in minutes for men was 7 (95% CI 5–11) and in women it was 6 (95% CI 5–10) min ($p = 0.001$). Men had shorter median CE time at 6 (95% CI 4–10) min compared to women at 7 (95% CI 5–11) min ($p = 0.001$). Patients with DM had median CI time of 8 (95% CI 5–14) min, compared to non-diabetics at 6 (95% CI 5–10) min ($p = 0.001$). Finally, patients with a history of abdominal surgery, including hysterectomies, had a statistically significant longer CI time than those who had undergone no surgery ($p = 0.03$). **Conclusion:** Men had longer median CI times than women, but shorter median CE times. Patients with DM and IHD had longer median CI times. Abdominal surgery was also associated with longer median CI times. Longer median CI times stands as an estimate of more difficult colonoscopies, which is associated with missed lesions.

Keywords: cecal intubation, colonoscopy, patient factors

OE-0573 (PE-0072) Duration between the completion of bowel preparation and the start of colonoscopy predicts bowel preparation quality

Authors: MOHAMMADALI ZAD[1]; CUONG DO[2]; LUCY JOHNSTON[3]; MOHAMMED ALANSARI[4]

Affiliation: [1]Department of Gastroenterology, Logan Hospital, Logan, [2]Department of Medical Student, Griffith University, Gold Coast, [3]Department of Pediatrics, Monash Hospital, Melbourne, and [4]Department of Gastroenterology, Ballart Hospital, Ballart Central, Australia

Background and Aim: Inadequate bowel preparation is associated with increased rates of missed polyps. We aim to determine the optimal time frame between the last dose of preparation agent and the start of the colonoscopy to achieve the highest frequency of excellent–good bowel prep. **Methods:** Prospective data collection of 3195 consecutive patients who received Prep Kit C between May 2012 and November 2014 at a regional hospital in Australia. Runway time calculated as the difference between the last dose of preparation agent and the start of the colonoscopy. Statistical analysis compared the frequency of adequate (defined as excellent/good by Ottawa scale) vs. inadequate (regular/bad/inadequate) bowel preparation at different runway times (hourly). Seventeen experienced endoscopists performed the colonoscopies, and data were collated by trained endoscopy nurses. Indications for colonoscopy were GI bleed (32.7%), surveillance (14.5%), screening (11.3%), anemia (9.4%), change in bowel habits (13.7%), abdominal pain (5.1%), and other (13.3%). **Results:** Patients with a runway time of 4–5 h ($n = 480$) achieved the highest percentage of adequate bowel preparation (97.1%). Comparatively, only 86.4% of patients with a runway time > 8 h ($n = 1007$) had adequate bowel preparation ($p < 0.05$). The OR of all patients exposed to runway time < 6 h compared to those with runway time > 6 h is 2.7 (95% CI 2.1, 3.5). Interestingly, patients with known diabetes had a 4.2% lower rate ($p = 0.005$) of adequate bowel preparation than non-diabetics. **Conclusion:** Patients should begin their colonoscopy 4–5 h after ingestion of the last dose of preparation agent for the highest rate of excellent or good bowel preparation. Runway time that exceeded 8 h showed a notable decline in adequate bowel preparation. The odds of getting an excellent–good bowel preparation was 2.7 times greater in patients with runway time < 6 h.

Keywords: runway time, colonoscopy, bowel prep

OE-0669 (PE-0073) Temporal trends of knowledge level and perceptions on colorectal cancer (CRC) screening among 4,800 Chinese residents: A population-based telephone study

Authors: JINGXUAN WANG; COLETTE LEUNG; MAGGIE CHAN; VEELEAH LOK; TIFFANY PANG; JUNJIE HUANG; JASON L W HUANG;

IRIS MAN YING WONG; **MARTIN CHI SANG WONG**

Affiliation: Department of JC School of Public Health and Primary Care, The Chinese University of Hong Kong, Hong Kong, Hong Kong

Background and Aim: Colorectal cancer (CRC) screening has been proven to be effective in reducing CRC-related mortality; however, uptake rate remains suboptimal. Through a government subsidized screening program, this study aims to evaluate changes in knowledge, perceptions, and cues to action towards CRC screening based on the Health Belief Model (HBM). **Methods:** Two rounds of population-based telephone survey were conducted among 4,800 randomly selected Hong Kong residents aged 61–70; 2,400 subjects were surveyed before, and other 2,400 were surveyed 1 year after the program had launched. Our validated questionnaire measured any HBM-related variables, including CRC knowledge, perceived susceptibility, severity, benefit, barriers, and cues to action. Variables between rounds were evaluated by Pearson's chi-square test. **Results:** Subjects of high level of knowledge on CRC symptoms and screening methods remained statistically similar between rounds. Significantly, more people perceived screening to be beneficial after program (1% vs. 48.5%, $p < 0.001$), while their perceived barriers to screen decreased across time (3.1% vs. 0.2%, $p < 0.001$). After the program, fewer subjects considered CRC family history (71.46% vs. 56.50%) or medical insurance (55.54% vs. 43.71%) as motivations to screen, but physicians' recommendation brought positive influence to respondents' screening behaviors (63.8% vs. 76.5%, all $p < 0.001$). **Conclusion:** Our findings demonstrated similar knowledge level yet higher perception of screening benefits, and greater motivation to be screened due to physicians' recommendations. These findings are of reference value for health educational initiatives and inform public health policy to enhance screening uptake.

Keywords: CRC screening, educational initiative, uptake rate

Table 1. Comparison of Pre- and Post- CRC screening programme

	Pre-programme (N=2,400) Frequency (%)	Post-programme (N=2,400) Frequency (%)	p-value
Gender			0.10
Male	1020 (42.5)	963 (40.1)	
Female	1380 (57.5)	1437 (59.9)	
Age	Mean=61.9 (SD=4.1)	Mean=62.2 (SD=3.5)	
Educational level			<0.001
Primary education or not schooling	1066 (44.4)	1229 (51.2)	
Secondary education	1100 (45.8)	1009 (42.0)	
Tertiary education	206 (8.6)	149 (6.2)	
Monthly household income			<0.001
<10,000 HKD	1144 (47.7)	1188 (49.5)	
10,001–20,000 HKD	326 (13.6)	507 (21.1)	
>20,000 HKD	306 (12.8)	338 (14.1)	
Knowledge of symptoms			<0.001
Low (scored 0)	785 (32.7)	903 (37.6)	
Middle (scored 1)	856 (35.7)	739 (30.8)	
High (scored ≥2)	759 (31.6)	758 (31.6)	
Knowledge of risk factors			<0.001
Low (scored 0)	741 (30.9)	1361 (56.7)	
Middle (scored 1)	984 (41.0)	335 (13.9)	
High (scored ≥2)	673 (28.0)	706 (29.4)	
Knowledge of screening			0.666
Low (scored 0)	118 (4.9)	105 (4.4)	
Middle (scored 1)	420 (17.5)	426 (17.8)	
High (scored ≥2)	1862 (77.6)	1869 (77.9)	
Perceived risk			<0.01
No	2143 (89.3)	2198 (91.6)	
Yes	257 (10.7)	202 (8.4)	
Perceived severity score			<0.001
Low (scored ≤5)	369 (15.4)	467 (19.5)	
Middle (scored 7–13)	969 (40.4)	850 (35.4)	
High (scored ≥14)	1062 (44.3)	1083 (45.1)	
Perceived benefit of test			<0.001
Low (scored 0–2)	744 (31.0)	33 (1.4)	
Middle (scored 3–5)	1654 (68.9)	1204 (50.2)	
High (scored 6–8)	2 (0.1)	1163 (48.3)	
Perceived health/psychological barrier to screening			<0.001
Low (scored ≤2)	1911 (79.6)	2148 (89.5)	
Middle (scored 3)	415 (17.3)	247 (10.3)	
High (scored 4)	74 (3.1)	5 (0.2)	
Perceived access barriers to screening			0.287
Low (scored 2)	1964 (81.9)	1992 (83.0)	
Middle (scored 3)	418 (17.4)	384 (16.0)	
High (scored 4)	18 (0.8)	24 (1.0)	
Family member had CRC			<0.001
No	471 (19.6)	873 (36.4)	
Don't know	214 (8.9)	171 (7.1)	
Yes	1712 (71.5)	1356 (56.5)	
Health insurance			<0.001
No	683 (28.5)	1194 (49.8)	
Don't know	381 (15.9)	156 (6.5)	
Yes	1333 (55.5)	1049 (43.7)	
Physician's recommendation			<0.001
No	838 (34.9)	508 (21.2)	
Don't know	311 (13.1)	56 (2.3)	
Yes	1251 (52.0)	1836 (76.5)	

OE-0672 (PE-0074) Magnetic bead(s)-assisted endoscopic submucosal dissection (MBA-ESD): A novel technique for resection of large superficial colorectal tumor

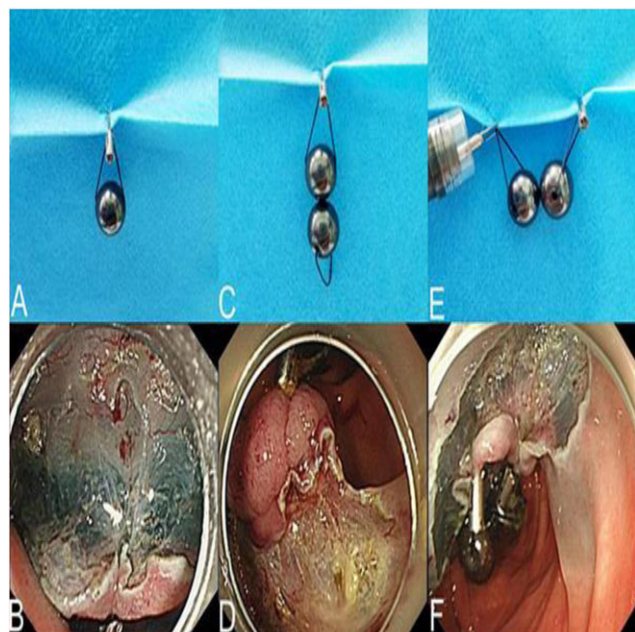
Authors: LIANSONG YE; BING HU; CHUNCHENG WU; WEI LIU; XIANGLEI YUAN

Affiliation: Department of Gastroenterology, West China Hospital, Sichuan University, Chengdu, China

Background and Aim: ESD is the main method for en bloc resection of large superficial colorectal tumors. However, colorectal ESD is technically difficult and time-consuming, especially for lesions in deep colon. It's reported that traction by gravity seems to be one of the most beneficial methods for colorectal ESD; we therefore devised a magnetic bead(s)-assisted ESD (MBA-ESD) (Fig. 1). The weight can be easily adjusted by using an additional magnetic bead and the direction of traction by changing patients' position, which enables endoscopist easier access to the cutting line during the whole procedure. This study was to assess the safety and effectiveness of MBA-ESD for large superficial colorectal lesions. **Methods:** Retrospective analyses of 14 patients who underwent MBA-ESD for large colorectal tumors between Jun. 2017 and Jan. 2018 at West China Hospital, Sichuan University. This method was compared with the prior 14 patients who underwent conventional ESD. **Results:** The locations of these 14 lesions included ascending colon ($n = 7$), hepatic flexure ($n = 2$), descending colon ($n = 2$), sigmoid colon ($n = 1$), and rectum ($n = 2$). Mean size of these lesions was 34.1 ± 12.0 mm. The en bloc resection and R0 resection of MBA-ESD were 100%. There was no bleeding or perforation in all cases. Compared with the conventional ESD group, the mean procedure time was significantly shorter (37.4 ± 17.1 min vs. 57.1 ± 22.6 min, $p = 0.015$). **Conclusion:** Our initial results suggested that MBA-ESD appears to be a safe and fast method for treating large superficial colorectal tumors.

Keywords: superficial colorectal tumors, ESD, traction, magnetic bead(s)

Figure 1



OE-0677 (PE-0075) Child-Pugh B or C cirrhosis increases the risk of bleeding following colonoscopic polypectomy

Authors: HOSIM SOH; JAEYOUNG CHUN; SEONA PARK; JONG PIL IM; JOO SUNG KIM

Affiliation: Department of Internal Medicine-GI/Hepatology, Seoul National University Hospital, Seoul, Republic of Korea

Background and Aim: The risk of postpolypectomy bleeding (PPB) following colonoscopic procedures in patients with liver cirrhosis remains unclear. We evaluated the risk of PPB in patients with LC compared to those with chronic hepatitis (CH). **Methods:** From 2011 to 2014, the medical records of patients with chronic liver disease (CLD) undergoing colonoscopic polypectomy at Seoul National University Hospital were reviewed. Primary endpoints were immediate PPB (IPPB) and delayed PPB (DPPB). The risk factors of IPPB and DPPB were analyzed. **Results:** A total of 1,267 patients with CLD were enrolled. The study population comprised 453 (35.8%) patients with CH, 700 (55.2%) with Child-Pugh (CP) A cirrhosis, 100 (7.9%) with CP-B cirrhosis, and 14 (1.1%) with CP-C cirrhosis, respectively. The incidence of IPPB and DPPB were significantly higher in patients with CP-B (22.0%) or CP-C cirrhosis (21.4%) compared to CP-A (6.9%) and CH (4.9%) ($p < 0.001$). The independent risk factors of IPPB were platelet count less than 50,000/uL (adjusted odds ratio [OR], 5.341; 95% confidence interval [CI], 2.595–10.991; $p < 0.001$), CP-B or CP-C (adjusted OR, 5.795; 95% CI, 1.414–5.795; $p = 0.003$), number of polyp (adjusted OR, 1.187; 95% CI, 1.082–1.302; $p < 0.001$), and size of polyp (adjusted OR, 1.062; 95% CI, 1.021–1.104; $p = 0.003$). The risk factors of DPPB were CP-B or CP-C (adjusted OR, 42.065; 95% CI, 3.911–452.465; $p = 0.002$), size of polyp (adjusted OR, 1.156; 95% CI, 1.072–1.246; $p < 0.001$), and history of cerebrovascular disease (adjusted OR, 39.964; 95% CI, 5.159–309.592; $p < 0.001$). **Conclusion:** CP-B or CP-C cirrhosis increased the risk of PPB compared to CH. Patients with decompensated cirrhosis should be monitored carefully for PPB.

Keywords: colonoscopy, bleeding, complication, liver cirrhosis, polypectomy

OE-0685 (PE-0076) Targeted forceps biopsy improves concordance rate of pathology with resected specimen in large colorectal tumors

Authors: DAJUNG RYU[1]; EUN SOO KIM[1]; HYUN SEOK LEE[1]; SUNG KOOK KIM[1]; MIN KYU JUNG[1]; JOON SEOP LEE[1]; JOON SEOK YOON[1]; CHANG HEON YANG[2]
Affiliation: [1]Department of Internal Medicine-GI/Hepatology, Kyungpook National University Hospital, Daegu, and [2]Department of Internal Medicine-GI/Hepatology, Dankook University Hospital, Gyeongju, Republic of Korea

Background and Aim: Colonoscopy with forceps biopsy is prerequisite for the diagnosis of large colorectal epithelial tumors before endoscopic or surgical resection. A remarkable discrepancy rate up to 60% in the pathologic diagnosis between forceps biopsy and resected specimen for large colorectal tumors. We aimed to compare accuracy of targeted biopsy with that of conventional biopsy in the pathologic diagnosis of large colorectal tumors. **Methods:** This was a prospective, randomized, single center study, which was conducted in a tertiary referral center between May 2017 and March 2018. Patients with colorectal epithelial tumors larger than 2 cm were eligible. Endoscopists took a forceps biopsy at depressed mucosa or large nodular area after meticulous surface evaluation using high definition colonoscopy in target group whereas they took a forceps biopsy at the most convenient area in control group. **Results:** Sixty-four patients with colorectal epithelial tumors larger than 2 cm were enrolled in the study (mean age 63.3 ± 9.5 year, male 25 [39.1%], mean size of tumors 23.8 ± 6.0 mm; target group 32 vs. control group 32). Concordance rate between forceps biopsy and resected specimen was significantly higher in target group than control group (81.3% vs. 53.1%, $p = 0.032$). In the target group, there were 6 patients (18.9%, 6/32) who showed disparity in the pathology between forceps biopsy and resected specimen; 5 (83.3%, 5/6) were underestimated in forceps biopsy whereas 1 (16.7%, 1/6) was downgraded in resected specimen. In the control group, there were 15 patients (46.9%, 15/32) who showed disparity in the pathology between forceps biopsy and resected specimen; 12 (80%, 12/15) were underestimated in forceps biopsy whereas 3 (20%) were downgraded in resected specimen. **Conclusion:** Targeted forceps biopsy based on surface evaluation significantly improved diagnostic accuracy of large colorectal tumors
Keywords: targeted forceps biopsy, large colorectal tumors, pathologic diagnosis, conventional biopsy

OE-0700 (PE-0077) Multi-loop method for colorectal endoscopic submucosal dissection: A feasibility study

Authors: GOTA SUDO[1]; TOKUMA TANUMA[2]; MASAKAZU AKAHONAI[2]; HIROSHI NAKASE[1]
Affiliation: [1]Department of Gastroenterology and Hepatology, Sapporo Medical University, and [2]Department of Internal Medicine-GI/Hepatology, Teine Keijinkai Hospital, Sapporo, Japan

Background and Aim: Colorectal endoscopic submucosal dissection (ESD) is one of the most challenging procedure. In order to simplify the procedure and reduce the risk related to colorectal ESD, we devised traction assisted ESD using multi-loop (M-loop) method. The aim of this study was to investigate a feasibility of M-loop method. **Methods:** We enrolled 29 patients who underwent ESD for superficial colorectal tumor at Teine Keijinkai Hospital between March 2017 and October 2017. M-loop was created with silk thread and syringe (both available in clinical practice). After attaching M-loop to a base of clip, housing into clip applicator, we delivered and attached the M-loop to specimen as a standard clip operation without scope removal. M-loop was used after completing circumference mucosal incision or in the difficult situation with conventional ESD. We evaluated the rate of en bloc resection, R0 resection, and adverse events. This study was approved by the Ethics Committee of Teine Keijinkai Hospital. **Results:** More than half of the lesions were located at flexure part, and more than half of the main operators were non-experts. The en bloc resection rate was 100% (29/29), while R0 resection rate was 93% (27/29). Delayed bleeding was occurred in one patient. Another one patient suffered micro-perforation during ESD. Endoscopic treatment with clipping was performed immediately, and the patient improved on conservative therapy. **Conclusion:** The M-loop method was feasible for colorectal ESD. This method can make it easy to perform colorectal ESD even in difficult cases. **Keywords:** endoscopic submucosal dissection, traction method, colorectal tumor

OE-0728 (PE-0078) The association of fruits and vegetable intake with colorectal adenomas: Preliminary results from a prospective colonoscopy cohort in Singapore

Authors: JUSTINA ANGEL TAN[1];

SAKINAH BINTE ABBAS[2];

NUR HALISAH BINTE JUMAT[2]; DAN YOCK YOUNG[1];

CLARE WHITTON[3]; JONATHAN LEE[1]

Affiliation: [1]Department of Medicine, National University Health System, Division of Gastroenterology and Hepatology, [2]Department of, National University of Singapore, Yong Loo Lin School Of Medicine, and [3]Department of, National University of Singapore, Saw Swee Hock School Of Public Health, Singapore, Singapore

Background and Aim: Previous Asian epidemiological studies reported inconsistent results regarding the association between intake of fruits and vegetables and colorectal adenoma risk: The Shanghai Men's Health Study concluded that adenoma risk is decreased only by intake of fruit and not vegetables. Conversely, 6 out of 8 other Asian studies linked decreased adenoma risk with mainly vegetable consumption. We thus conducted a cross-sectional study of local patients to investigate the association of fruits and vegetable intake with colorectal adenoma risk. **Methods:** Sixty-one Chinese patients undergoing colonoscopy, between June 2016 and June 2018, at National University Hospital, Singapore, were each personally administered a validated semiquantitative food frequency questionnaire covering 168 food and beverage items. Statistical analysis using binary logistic regression was calculated with SPSS v25. **Results:** Thirty-two (52.5%) patients had colorectal adenomas, whereby there were no significant differences in the mean age ($p = 0.26$) and mean body mass index ($p = 0.83$), when compared to patients without adenomatous polyps. There was a lower proportion of men with adenomatous polyps (40.6% vs 58.6%), although not statistically significant ($p = 0.16$). A greater proportion of patients (64.7% vs 35.3%) taking ≥ 3 servings of vegetables per day had no colorectal polyps, whereby patients taking ≥ 3 servings of vegetables per day, compared to patients taking ≤ 2 servings of vegetables per day, were 3.93 (95% CI 1.03–15.0, $p < 0.05$) times more likely to have a normal colonoscopy. There was no difference in the amount of fruits taken between patients with or without colorectal adenomas ($p = 0.90$). **Conclusion:** Our findings suggest that vegetables, rather than fruits, may have beneficial effects against colorectal adenoma development, whereby patients taking ≥ 3 servings of vegetables a day had 42% less risk of adenomatous colonic polyps, compared to patients taking ≤ 2 servings of vegetables a day.

Keywords: polyp, colonoscopy, vegetable, fruits, colorectal

OE-0751 (PE-0079) Polypectomy bleeding risk in the continuation of antithrombotics at colonoscopy: A retrospective analysis of 1 year cohort

Authors: JESSICA Y L CHING; ANDREW M Y HO;

MOE HTET KYAW; THOMAS Y T LAM; JUSTIN C Y WU;

FRANCIS K L CHAN

Affiliation: Department of Institute of Digestive Disease, The Chinese University of Hong Kong, Hong Kong, Hong Kong

Background and Aim: The use of antithrombotics is increasing with an aging global population. Although there are international practice guidelines on the management of antithrombotics in patients undergoing endoscopy, the risk of post-polypectomy bleeding varies. **Methods:** Patients undergoing colonoscopy from July 2015 to June 2016 were reviewed. Patients were identified if they were receiving antithrombotics (anticoagulants and thienopyridines) when colonoscopy was scheduled and were expected to continue after colonoscopy. We reviewed all consultation notes starting from the booking date of colonoscopy until day 30 after the procedure. Continuation of antithrombotics were checked. Immediate post-polypectomy was considered present if there was bleeding observed during colonoscopy requiring endoscopic intervention. Day 30 bleeding was considered present if patients were hospitalized for therapeutic endoscopy. **Results:** Between July 1, 2015 and June 30, 2016, 4,777 patients underwent colonoscopy, 124 patients (male: 54.9%; mean age: 68.2) took antithrombotics (114 anticoagulant users and 10 thienopyridines users). Among them, 51 (41.1%) patients had continued antithrombotics and 65 (45.1% in continuation group vs 57.5% in the discontinuation group, $p = 0.17$) patients had polypectomy done. A total of 26 patients (7 in the continuation group vs 19 in the discontinuation group) had immediate post-polypectomy (13.7% vs 26.0%, $p = 0.10$) (Fig. 1). Three patients (1 in the continuation group vs 2 in the discontinuation group) had post-polypectomy bleeding on day 30. **Conclusion:** Our study showed that the risk of post-polypectomy bleeding at the time of colonoscopy was not significantly higher with the continuation of antithrombotics at colonoscopy.

Keywords: polypectomy bleeding risk, continuation of antithrombotics

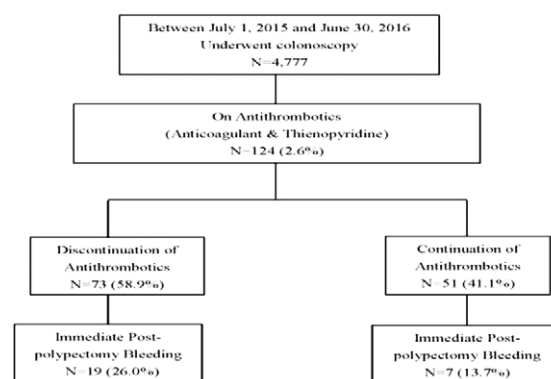


Figure 1. Diagram showing the review process

OE-0784 (PE-0080) Clinical research on the effect of background music on normal colonoscopy

Authors: QIUYU CHEN; WEI ZHAO; XIN ZHANG; BIN WANG; JUNLING LIU; YUMING WANG; QINGXIANG YU; BANGMAO WANG; HAILONG CAO

Affiliation: Department of Gastroenterology and Hepatology, Tianjin Medical University General Hospital, Tianjin, China

Background and Aim: Colonoscopy is an essential method for the detection of colorectal diseases. Patients generally feel uncomfortable, while anesthesia colonoscopy cannot be applied to all patients. We worked with the effects of background music on the tolerability, pain level, overall efficacy of colonoscopy, and attempt to study the mechanisms. **Methods:** Eighty patients who underwent colonoscopy were consecutively enrolled and randomly divided into two groups. Background music was played in the OR; keep the OR quiet in the controls. Autonomic nerve function examinations were performed before and after colonoscopy; the pain intensity reports were measured by patients. The number of cases that complete the colonoscopy (reaching the cecum), time of the procedures, and intestinal polyp detection rate were recorded. **Results:** The pain self-evaluation in the music intervention group was lower (3.00 [2.00, 4.00] vs. 3.50 [3.00, 6.00], $p < 0.05$). The change in the parasympathetic components of the autonomic nervous activity after colonoscopy in the music intervention group increased, while the change in the sympathetic components decreased. Ninety-two percent of patients in the music intervention group thought that background music had beneficial effects; the physician thought that it helped among 96% of the processes. The ratio of cases that complete the colonoscopy had no significant difference (97.4% vs. 92.5%, $\chi^2 = 0.949$, $p = 0.329$); the time of the procedures was less than the control group (6.00 [5.00, 8.00] min vs. 9.50 [5.75, 10.25] min, $p < 0.05$); no significant difference in the detection rate of polyps between the treatment group and the control group. **Conclusion:** A small sample of randomized controlled research found that playing background music during the routine colonoscopy can reduce pain, improve tolerance to colonoscopy, shorten time of procedures, which may be related to background music regulating autonomic nerve function.

Keywords: background music, colonoscopy

OE-0785 (PE-0081) Sex differences in the bowel preparation score and colonoscopy insertion time

Authors: YOUNG-JAE HWANG; NAYOUNG KIM; DONG WOO SHIN; EUN SUN JANG; HYUK YOON; CHEOL MIN SHIN; YOUNG SOO PARK;

JIN HYEOK HWANG; JIN-WOOK KIM; DONG HO LEE

Affiliation: Department of Internal Medicine, Seoul National University Bundang Hospital, Seongnam, Republic of Korea

Background and Aim: Colonoscopy indices such as bowel preparation score and cecal insertion time have been studied. However, sex differences in colonoscopy indices have never been studied. This study was performed to investigate the differences in the Boston bowel preparation score (BPPS) and colonoscopy insertion time between men and women. **Methods:** This study retrospectively analyzed the medical records of subjects who underwent colonoscopy at Seoul National University Bundang Hospital from March 2015 to April 2018. BPPS was used to evaluate the colon cleanliness before colonoscopy. Statistical analysis was performed to compare demographic, clinical, and outcome variables between two groups. **Results:** The study group consisted of a total of 17,035 patients (8,277 women and 8,758 men). Mean age was 60.0 ± 13.7 for men and 60.0 ± 13.2 for women ($p = 0.034$) (Table). The 13.4% (1,177/8,758) of men and 11.9% (981/8,277) of women underwent colon surgery before colonoscopy. Subjects who underwent colonic resection had shorter procedure time than those who did not undergo surgery. More than 99% of patients received sedation colonoscopy regardless of sex. Women showed better bowel preparation score than men (7.3 vs. 7.1, $p = 0.001$). However, the cecal intubation time and total procedure time was longer in women than in men regardless of the history of the operation (both $p = 0.001$). **Conclusion:** There is sex difference of undergoing colonoscopy in terms of BPPS, cecal intubation time, and total colonoscopy time, although the difference is small than expected.

Keywords: sex difference, bowel preparation time, cecal intubation time, total procedure time

Table. Sex difference in bowel preparation score and colonoscopy insertion time (n = 17,035)

Variables	Male (n = 8,758)	Female (n = 8,277)	p-value
Age, mean \pm SD	60.0 \pm 13.7	60.0 \pm 13.2	0.034
History of colon surgery	1,177 (13.4%)	981 (11.9%)	0.001
Non-sedation CFS, n (%)	70 (0.8%)	55 (0.7%)	0.001
Sedation CFS, n (%)	8,688 (99.2%)	8,222 (99.3%)	
BPPS, total score (mean \pm SD)	7.1 \pm 1.9	7.3 \pm 1.9	0.001
Right colon (mean \pm SD)	2.2 \pm 0.8	2.3 \pm 0.8	
Transverse colon (mean \pm SD)	2.5 \pm 0.7	2.6 \pm 0.6	
Left colon (mean \pm SD)	2.4 \pm 0.7	2.5 \pm 0.7	
Cecal intubation rate, n (%)	8,331 (95.1%)	7,860 (95.0%)	0.625
No Hx. of surgery, n (%)	7,219 (95.2%)	6,950 (95.3%)	0.925
Hx. of surgery, n (%)	1,112 (94.5%)	910 (92.8%)	0.103
Cecal intubation time (min, mean \pm SD)	5.0 \pm 6.0	6.2 \pm 7.1	0.001
No Hx. of surgery (min, mean \pm SD)	5.2 \pm 6.2	8.4 \pm 6.4	0.001
Hx. of surgery (min, mean \pm SD)	3.7 \pm 3.7	4.8 \pm 4.2	0.001
Total procedure time (min, mean \pm SD)	12.8 \pm 7.1	13.8 \pm 7.2	0.001
No Hx. of surgery (min, mean \pm SD)	13.2 \pm 7.3	14.0 \pm 7.3	0.001
Hx. of surgery (min, mean \pm SD)	10.3 \pm 4.9	11.3 \pm 5.4	0.001

Abbreviations: SD, standard deviation; BPPS, Boston bowel preparation score; Hx., history; CFS, colon fibroscopy

OE-0842 (PE-0082) Ileal changes in patients with microscopic colitis

Authors: SIDDHARTH SHUKLA; RAKESH KOCHHAR; SATYAVATI RANA; KAUSHAL KISHOR PRASAD; NARENDRA DHAKA; NEHA BERRY; SARTHAK MALIK; BALAJI LAXMINARAYANSHETTY BELLAM; MEGHA SHARMA; SAROJ KANT SINHA

Affiliation: Department of Gastroenterology, Post Graduate Institute of Medical Education and Research, Chandigarh, India

Background and Aim: Microscopic colitis (MC) is an overlooked cause of chronic diarrhea. Strict restriction of disease to colon is still unclear and may have bearing on treatment regimes. We therefore evaluated terminal ileum using narrow band imaging (NBI), high definition white light endoscopy (HDWLE) with eventual histopathological findings on biopsy. **Methods:** Fifty-three adults with suspected MC were recruited and routine tests done. All underwent colonoscopy with ileal intubation if possible. Segmental colonic biopsies were obtained with additional biopsies from terminal ileum using HDWLE and NBI. They were analyzed by expert gastrointestinal histopathologist. **Results:** MC was established in 43 patients. HDWLE findings of ileum did not reveal any abnormality. On NBI, intravillous capillary network was regular unbranched with semicircular pattern in 41 (95.4%) of patients of MC and in all controls. It was sparse and irregular in 2 (4.7%) cases. Peyer's patch domes were indistinct in 5 (9.4%) or normal in 38 (88.4%) cases and normal in all controls ($p = 0.570$). Peyer's patch vessels were regular and unbranched in 38 (88.4%) cases and in all controls. They were sparse and irregular in 5 cases (11.6%) ($p = 0.570$). Histopathology of terminal ileum revealed normal villi in 39 (90.6%) cases, 4 had partial villous atrophy. The crypt villous ratio was grouped as 1:1.5, 1:3, 1:4, and 1:5 in 2 (4.6), 26 (60.4), 11 (25.5%), and 4 (9.3), respectively. Lymphoplasmacytic infiltrate was grouped as mild, moderate, and severe and observed in 10 (23.2%), 2 (4.6%), and 1 (2.3%) patient, respectively. **Conclusion:** Ileal NBI findings in MC are being reported for the first time, with up to 12% showing abnormalities. Histologically, almost 23% showed abnormalities in ileal biopsies. Ileal pathology may contribute to certain symptoms in MC and have bearing on treatment.

Keywords: microscopic colitis, narrow band imaging, ileal findings

OE-0950 (PE-0083) Randomized, controlled trial of abdominal vibration stimulation versus walking for bowel cleansing before colonoscopy

Authors: CHOONG-KYUN NOH; SUN GYO LIM; SUNG JAE SHIN; KWANG JAE LEE; KEE MYUNG LEE

Affiliation: Department of Gastroenterology, Ajou University Hospital, Suwon, Republic of Korea

Background and Aim: Adequate bowel preparation is important for successful colonoscopy. We aimed to evaluate the clinical feasibility and effectiveness of abdominal vibration stimulation in bowel preparation.

Methods: In this randomized, prospective, investigator-blind, single-center study, 200 inpatients, undergoing elective colonoscopy, were randomized into two groups. During the preparation period, patients assigned to the walking group ($n = 100$) walked $\geq 3,000$ steps, whereas those assigned to the vibrator group ($n = 100$) received abdominal vibrator stimulation and avoided walking. One hundred patients were also enrolled as a control group. All patients received the same colon cleansing regimen: 4-L split-dose polyethylene glycol (PEG) solution. **Results:** There were no significant differences ($P > 0.05$) between the vibrator group and walking group regarding instances of diarrhea after taking PEG (11.23 ± 3.45 vs. 11.18 ± 3.18), time to first diarrhea after taking PEG (109.3 ± 41.10 vs. 114.9 ± 37.57 min), total procedure time (35.16 ± 25.78 vs. 40.43 ± 23.37 min), patient satisfaction (4.25 ± 0.83 vs. 4.21 ± 0.82), or bowel preparation adequacy (Boston Bowel Preparation Scale score for the entire colon: 7.38 ± 1.55 vs. 7.39 ± 1.55), but the vibrator group had shorter cecal intubation time (5.96 ± 2.63 vs. 7.93 ± 5.05 min, $P < 0.001$) compared with the walking group. **Conclusion:** Compared to walking exercise, which is the conventional approach for promoting bowel preparation for colonoscopy, abdominal vibration stimulation achieved similar rates of bowel cleansing adequacy and colonoscopy success without compromising safety or patient satisfaction. Abdominal vibration stimulation may help improve bowel preparation in patients who are unable to perform walking exercise, but further research is needed to validate our findings in such a population.

Keywords: colonoscopy, bowel cleansing, abdominal vibration stimulation, walking exercise

OE-0970 (PE-0084) A pilot study prophylactic complete closure of colonic endoscopic submucosal dissection (ESD) wounds to prevent delay bleeding in a non-Japanese center

Authors: KA LUEN THOMAS LUI; WAI KEUNG LEUNG

Affiliation: Department of Medicine, Queen Mary Hospital, Hksar, Hong Kong

Background and Aim: Fear of complications of ESD, namely, perforation and bleeding, is one of the main obstacles of the development of ESD in non-Japanese centers. The aim of this study is to describe the role of prophylactic complete closure of ESD wounds to prevent delay bleeding in a non-Japanese center during the early stage of acquiring ESD technique. **Methods:** Consecutive colorectal ESD done performed by a single endoscopist from 2015 to June 2018 were reviewed. This was the initial phase of colorectal ESD (defined as < 100 colorectal cases) done by this endoscopist. All ESD wounds were attempted to close except those with technical reasons, e.g. non-approachable edges by hemoclip and non-deformable wound. Complete closure of mucosal defects after ESD was being defined as no muscle layer seen after closure by hemoclips (EZ clip, HX –610–090 L; Olympus or Single use hemoclip; Anrei). Delay bleeding was defined as clinical evidence of bleeding that required endoscopic hemostasis or a decrease in the hemoglobin level of > 2 g/dL after ESD. **Results:** Patient's demographics, complications, and other outcomes of closure and non-closure group were compared and summarized in Table 1. Both non-complete mucosal closure ($p < 0.001$) and anticoagulation use ($p < 0.001$) are associated with increased risk of delay bleeding by multivariate analysis. **Conclusion:** Complete mucosal closure may decrease risk of delay bleeding after colorectal ESD in the initial phase of acquiring ESD technique.

Keywords: colonoscopy, endoscopic submucosal dissection, clipping, initial, bleeding

Table 1.

	Complete mucosal closure N=77	Non-complete mucosal closure N=20	P value
Age	65.7 ±13.1	65.3±11.8	0.98
Male Sex	58 (75.3%)	12 (60.0%)	0.26
Tumor location (colon/ rectum)	73 (94.8%)/4 (5.2%)	16 (80%)/4 (20%)	0.054
Use of antiplatelet/anticoagulation	24 (31.1%)/4 (5.2%)	5 (25.0%)/2 (10.0%)	0.57
Platelet level (unit × 10 ⁹)	229±70	233±90	0.85
Macroscopic appearance (IST-G/NG)	43 (55.8%)/34 (44.2%)	16(80%)/4 (20%)	0.06
Resected specimen size (mm)	29.4 ± 11.3	28.0 ± 16.0	0.79
Fibrosis (F0/F1/F2)	54 (70.1%)/8(10.3%)/15(19.4%)	14 (70%)/3(15%)/3(15%)	0.79
Histology (Carcinoma/IA or SIA/ Hyperplastic or benign)	5(6.5%)/65(84.4%)/7(9.1%)	2 (10%)/16(80%)/2(10%)	0.85
ESD Resection time (minutes) (Mean ±SD)	127 ±56	116 ±69	0.55
Closure time (minutes) (Mean ±SD)	19.2 ±14.9	-	
Hybrid technique use	10 (13.0%)	6 (30%)	0.09
Endoscopic resection	75 (97.4%)	18 (90%)	0.18
SD resection	64 (83.1%)	17 (85%)	1.00
Delay bleeding	0	5 (25%)	*0.0002
Perforation (immediate or delay)	0	0	-

EE-0395 (PE-0088) The effect of colonic stent insertion on cecal intubation time in patients with malignant colorectal obstruction

Authors: CHOONG-KYUN NOH; BYOUNG HOON MIN; JI WON YANG; AH REUM KIM; SUNG JAE SHIN

Affiliation: Department of Gastroenterology, Ajou University Hospital, Suwon, Republic of Korea

Background and Aim: There were few studies about colonoscopic insertion time in patients with self-expandable metallic stent (SEMS) insertion in colorectal cancer. We evaluate the influence of colonic SEMS insertion on colonoscopic insertion time. **Methods:** Retrospectively, a total of 66 patients with SEMS insertion in obstructive colorectal cancer were enrolled (group A). Also, to compare the insertion time, we enrolled the 331 patients without SEMS in colorectal cancer (group B) and 1568 non-cancer patients (group C). We compared the colonoscopic insertion time and evaluated its related factors among the groups. **Results:** In bowel preparation, the excellent and good grade was 12.1% in group A and 24.5% in group B ($p < 0.04$). In tumor T staging, T1, T2, T3, T4, was 0.0%, 1.7%, 75.9%, 22.4% in group A, and 20.8%, 14.8%, 55.3%, 9.1% in group B ($p < 0.001$). The mean colonoscopic cecal intubation time was 11.8 mins (group A), 9.9 min (group B), and 8.8 min (group C) with statistical significance ($p < 0.001$). Mean cecal intubation time according to cancer location was not different between groups A and B, except sigmoid colon cancer (group A, 11.8 ± 5.9 min vs. 8.1 ± 6.5 min, p value < 0.001). **Conclusion:** The stent insertion in colorectal cancer was thought to be a negative effect on the colonoscopic intubation, especially in sigmoid colon cancer.

Keywords: self-expendable metallic stent, colorectal cancer, cecal intubation time

OE-0440 (PE-0089) Efficacy and safety of winged partially covered self-expandable metal stent for malignant gastric outlet obstruction: Newly designed stent to prevent distal migration

Authors: YOUNG KWON CHOI; JI YONG AHN; HEE KYONG NA; KEE WOOK JUNG; DO HOON KIM; JEONG HOON LEE; KEE DON CHOI; HO JUNE SONG; GIN HYUG LEE; HWOON-YONG JUNG

Affiliation: Department of Internal Medicine-GI/Hepatology, Asan Medical Center, Seoul, Republic of Korea

Background and Aim: Through-the-scope implantation of self-expandable metal stents can be used for the palliation of malignant gastric outlet obstruction (GOO). Although covered stents were developed to prevent tumor ingrowth, often seen with uncovered stents, migration is still major problem. Especially, surgical treatment is required in some patients if distal migration occurs. We evaluated the usefulness of the newly designed winged stent (Fig. 1) that was developed to prevent distal migration. **Methods:** This was a single center, single-arm, retrospective study. A total of 63 inoperable cancer patients with symptomatic GOO were reviewed to evaluate the safety and efficacy of a newly designed partially covered self-expandable metal stent with star-shaped wing flaps at the proximal end to reduce distal stent migration. **Results:** Technical and clinical success was achieved in 100% and 87.3% of patients, respectively. The GOO Scoring System score significantly improved after stent placement (from median 1 to 2, $p < 0.001$). The median duration of stent patency was 147 days (interquartile range [IQR], 76–201), and median duration of overall survival was 176 days (IQR, 79–325). Stent migration was observed in seven patients (11.1%), and restenosis developed in 12 patients (19.0%). All cases of migration were proximal, and no distal migration was observed. Endoscopic removal of migrated stents was performed successfully in all cases. **Conclusion:** The newly designed winged stent showed feasible efficacy and safety for malignant GOO. Furthermore, it effectively prevented distal stent migration.

Keywords: gastric cancer, stent, gastric outlet obstruction, self-expandable metal stent, migration

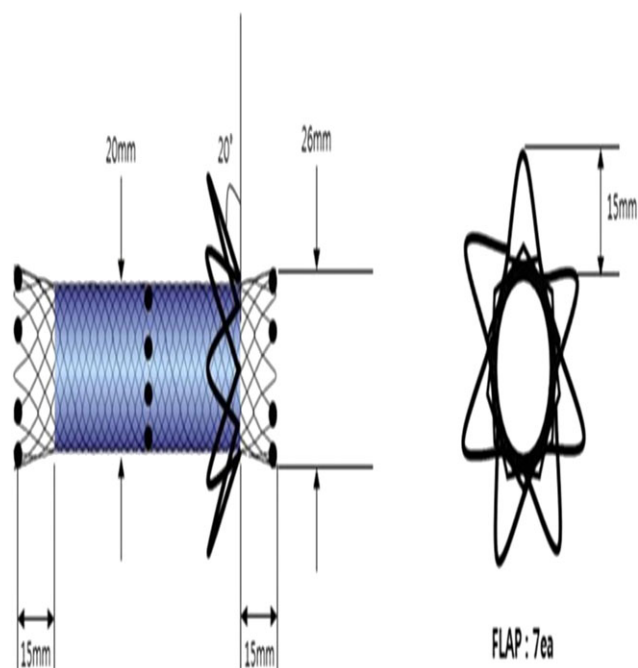


Figure 1

OE-0504 (PE-0090) Fluoroscopic self-expandable metallic stent placement for treating postoperative nonanastomotic strictures in the proximal small bowel: A 15-year single institution experience

Authors: NADER BEKHEET[1]; HO-YOUNG SONG[2]

Affiliations: [1]Department of Gastroenterology, Gastrointestinal Endoscopy and Liver Unit, Kasr Al Ainy Faculty of Medicine, Cairo University, Cairo, Egypt; and [2]Department of Radiology, Asan Medical Center, Seoul, Republic of Korea

Background and Aim: To evaluate the efficacy and safety of fluoroscopic self-expandable metallic stent (SEMS) placement for treating postoperative nonanastomotic strictures in the proximal small bowel. **Methods:** Data from eight patients (mean age, 63.8 ± 6.9 years; seven males and one female) who underwent 17 fluoroscopic SEMS placement procedures in total for treating postoperative nonanastomotic strictures in the proximal small bowel (i.e. duodenum and proximal jejunum) were retrospectively reviewed. Strictures were located in the proximal jejunum in all patients. The mean length of the strictures was 5.8 ± 2.0 cm. Five patients with comorbidities were poor surgical candidates. Four patients underwent fluoroscopic balloon dilation, three of whom showed no resolution of obstructive symptoms and one demonstrated recurrence. **Results:** Technical and clinical success was achieved in 100% (17/17) SEMS procedures. Complete resolution of obstructive symptoms and improvement in oral intake status occurred within 3 days after all procedures, rendering a clinical success rate of 100% (17/17). No complication occurred during or after the procedures. The median follow-up duration was 167 (interquartile range [IQR], 48–576) days. Stent malfunction occurred after 58.8% (10/17) of the procedures, including six occurrences of stent migration and four of tissue overgrowth. Recurrence occurred after 64.7% (11/17) of the procedures. The median stent dwell and recurrence-free times were 32 [IQR, 20–193] days and 68 [IQR, 38–513] days, respectively. **Conclusion:** Fluoroscopic SEMS placement may be effective and safe for treating postoperative nonanastomotic strictures, but stent malfunction and recurrence are major drawbacks.

Keywords: postoperative nonanastomotic strictures, small bowel, self-expandable metallic stent

OE-0508 (PE-0091) Preliminary results of fluoroscopic peroral placement of a self-expandable metallic stent for malignant jejunal obstruction in a non-surgically altered stomach

Authors: NADER BEKHEET[1]; HO-YOUNG SONG[2]; WANG ZHE[2]

Affiliations: [1]Department of Gastroenterology, Gastrointestinal Endoscopy and Liver Unit, Kasr Al Ainy Faculty of Medicine, Cairo University, Cairo, Egypt; and [2]Department of Radiology, Asan Medical Center, Seoul, Republic of Korea

Background and Aim: To evaluate the technical feasibility and clinical effectiveness of fluoroscopic peroral placement of a self-expandable metallic stent (SEMS) in the palliative treatment of a malignant proximal jejunal obstruction in a non-surgically altered stomach. **Methods:** Using the peroral method, fluoroscopically guided SEMSs were placed in five consecutive patients with a malignant proximal jejunal obstruction. Data were collected on technical and clinical success and stent-related complications and management. **Results:** Stent placement was technically successful in three of five patients. The stent delivery system could not pass through the obstructions due to the angulation of the bowel loop in one patient. In the other patient with technical failure, proximal jejunal perforation occurred during the negotiation of the guidewire. These two patients underwent palliative bypass surgery. During a mean follow-up period of 229 days (range 102–377 days), symptoms improved after stent placement in three patients. In one of these three patients, stent migration occurred 32 days after placement. This patient underwent additional stent placement. **Conclusion:** Fluoroscopically guided peroral placement of SEMSs, which can provide fast symptom relief, may be useful for stent placement in patients with proximal jejunal obstruction. However, a more flexible guiding sheath or steerable guiding sheath must be developed to improve the technical success rate of the peroral placement of SEMSs into the proximal jejunum. **Keywords:** malignant small bowel obstruction, self-expandable metallic stent, non-surgically altered stomach, jejunum

EP-0081 (PE-0092) Single-balloon enteroscopy: Preliminary experience in patients with gastrointestinal bleeding suspected to originate from the small intestine

Authors: KHIEU VAN VU; GIANG ANH DO; HO THI THU PHAM; TRUONG MANH NGUYEN; TUAN VAN KIEU; TUNG LAM NGUYEN

Affiliation: Department of GI Endoscopy, 108 Central Hospital, Hanoi City, Vietnam

Background and Aim: Single-balloon enteroscopy (SBE) is a novel method of balloon-assisted enteroscopy which allows deep intubation of intestine and has therapeutic potential. The aim of the present study was to evaluate the feasibility, complications, diagnostic, and therapeutic yield of SBE in patients with suspected to originate the small intestine. **Methods:** Between January 2014 and December 2017, all patients undergoing enteroscopy with the Olympus SBE system (length 200 cm, outer diameter 9.2 mm) were studied. **Results:** One hundred and eighteen patients (mean age 44.3 years, range 12–76 years, 86 men) with suspected small bowel bleeding underwent 158 SBE procedures. Antegrade and retrograde approaches were used in 72% and 28% of subjects, respectively. The mean insertion depth was 246.5 ± 76.3 cm beyond the duodenojejunal flexure by the oral route and 158 ± 58.6 cm proximal to the ileocecal valve by the per anal approach. The mean duration of the procedure for antegrade and retrograde enteroscopy was 65.9 ± 19.5 min and 72.3 ± 18.3 min, respectively. Pan-enteroscopy was possible in 24.3% of cases. Diagnostic yields in cases of OGIB were 43.2%. The causes of bleeding found on SEB include angiodysplasia ($n = 11$), adenocarcinoma ($n = 9$), polyp ($n = 17$), ulcers ($n = 12$), intestinal tuberculosis ($n = 1$), Meckel's diverticulum ($n = 1$). The number of patients receiving endoscopic intervention was 28/118 (23.7%). No severe complications such as perforation, bleeding, or pancreatitis occurred. **Conclusion:** SBE is well tolerated and has good diagnostic yield. Therefore, SBE may be a useful diagnostic and therapeutic tool in addition to DBE for investigating suspected small bowel disease. **Keywords:** single-balloon enteroscopy

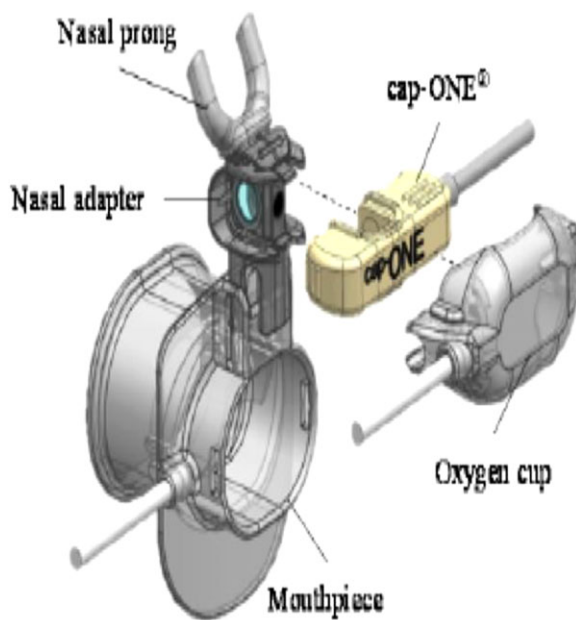
EE-0033 (PE-0093) A mainstream capnometer system is safe and feasible under CO₂ insufflation during ERCP procedures

Authors: YOICHI TAKIMOTO[1]; EISUKE IWASAKI[1]; TATSUHIRO MASAOKA[1]; YUJIRO MACHIDA[1]; HIROKI TAMAGAWA[1]; TADASHI KATAYAMA[1]; KAZUHIRO MINAMI[1]; SHINTARO KAWASAKI[1]; TAKASHI SEINO[1]; MASAYASU HORIBE[1]; SEIICHIRO FUKUHARA[2]; HARUHIKO OGATA[2]; TAKANORI KANAI[1]

Affiliation: Departments of [1]Internal Medicine-GI/Hepatology [2]Center for Diagnostic and Therapeutic Endoscopy, Keio University, Tokyo, Japan

Background and Aim: There is a need to safely accomplish conscious sedation during endoscopic retrograde cholangiopancreatography (ERCP). Apnea preceding hypoxemia is one of the frequent adverse effects of conscious sedation during endoscopic procedures. We evaluated the safety and feasibility of a newly developed mainstream capnometer system (shown in figure) to monitor apnea during ERCP under CO₂ insufflation. **Methods:** Non-intubated adult patients who underwent ERCP-related procedure with intravenous sedation were enrolled. End tidal CO₂ (EtCO₂) was continuously monitored during procedure under CO₂ insufflation using a mainstream capnometer system which consists of capnometer and specially designed bite block for upper-gastrointestinal endoscopy and ERCP. SpO₂ was also monitored continuously during procedure. **Results:** Eleven patients were enrolled. Measurements of CO₂ concentration were possible from the beginning to the end in all 11 cases. There was neither measurement failure nor dislocation of bite block and adverse event related to this bite block occurred. Apnea events occurred 7 times in 7 patients, and hypoxemia was linked to apnea 5 times in 5 patients. The apnea event linked to hypoxic event occurred in 5 times (mean duration time was 195 s). **Conclusion:** Measurement of EtCO₂ concentrations using newly developed mainstream capnometer system was feasible and safety under CO₂ insufflation. **Keywords:** ERCP, sedation, CO₂

Structure of the cap-ONE bite block



EE-0113 (PE-0094) Efficacy of indomethacin or diclofenac to prevent post-ERCP pancreatitis (PEP): A comparative study

Authors: BIMAL CHANDRA SHIL[1]; MADHUSUDAN SAHA[2]; SHASANKA KUMAR SAHA[3]; RANJIT KUMAR BANIK[4]; ABU NAYEEM MD SAIFULLAH[5]; MD ROYES UDDIN[6]; MD OMAR FARUQ[7]; MD HABIBUR RAHMAN[8]

Affiliation: Departments of [1]Gastroenterology, [3]Internal Medicine-GI/Hepatology, [4]Internal Medicine-GI/Hepatology, [5]Internal Medicine-GI/Hepatology, [6]Internal Medicine-GI/Hepatology [7]Internal Medicine-GI/Hepatology, [8]Internal Medicine-GI/Hepatology, Sir Salimullah Medical College, Dhaka, [2]Department of Internal Medicine-GI/Hepatology, North East Medical College, Sylhet, Bangladesh

Background and Aim: Acute pancreatitis is the most common major post-ERCP complication ranging as high as 10–30%. Rectal NSAIDs (indomethacin or diclofenac) seem to be the most promising drugs to prevent post-ERCP pancreatitis (PEP). We performed a trial to investigate the efficacy of indomethacin or diclofenac. **Methods:** A prospective randomized comparative trial was performed at Dhaka from January 2013 to March 2018. Patients undergoing ERCP were randomly selected to group A and group B. Diclofenac 50-mg suppository was given to group A patients and indomethacin 100-mg suppository was given to group B patients during or just after ERCP. The primary outcome was acute pancreatitis following the procedure which was defined by new upper abdominal pain, elevation of pancreatic lipase to at least 3 times the upper limit of normal level 24 h after ERCP and hospitalization for 02 nights. Retrospective data of 122 patients who had undergone ERCP in 2012 but had no history of rectal NSAIDs were analyzed (group C). **Results:** Total 613 patients were included in this study and followed up. PEP developed in 21 (8.5%) patients of group A ($n = 247$), in 19 (7.78%) patients of group B ($n = 244$), and in 20 (17.85%) patients of group C ($n = 122$) ($p = 0.02$). Moderate to severe pancreatitis were found in 08 (3.23%) patients of group A, in 06 (2.45%) patients of group B, and in 12 (9.83%) patients of group C ($p = 0.01$). Administration of these NSAIDs showed clear benefit to reduce occurrence of PEP when compared with no drug group ($p = 0.01$). The efficacy of indomethacin compared with diclofenac was similar ($p = 0.874$). **Conclusion:** Prophylactic use of rectal indomethacin or diclofenac during or just after ERCP significantly reduce the incidence of post-ERCP pancreatitis. These NSAIDs are inexpensive, safe, and should be used routinely in each patient undergoing ERCP.

Keywords: ERCP, rectal NSAIDs, post-ERCP pancreatitis

EE-0215 (PE-0095) The safety and efficacy of a large-bore biliary metallic stent in malignant biliary obstruction

Authors: YONSOO KIM; SUNG ILL JANG; DONG KI LEE

Affiliation: Department of Internal Medicine-GI/Hepatology, Gangnam Severance Hospital, Seoul, Republic of Korea

Background and Aim: In patients with unresectable malignant biliary obstructions, self-expanding metallic stent (SEMS) is widely used. However, SEMS is susceptible to occlusions by tumor ingrowth, outgrowth, and sludge formation. To overcome these adverse effects, we used a novel full covered SEMS (FCSEMS) which has 12-mm body diameter and 16-mm head diameter like dumbbell-shaped. The conventional FCSEMS (FCSEMS-C) has 10 mm diameter in both head and body. The efficacy and safety of a large-bore dumbbell-shaped FCSEMS (FCSEMS-L) was compared with FCSEMS-C. **Methods:** Patients with unresectable distal malignant biliary obstruction was retrospectively enrolled in this study at Gangnam Severance Hospital between January 2011 and February 2018. A total of 46 patients were included. A FCSEMS-L was inserted endoscopically in 23 patients, and a FCSEMS-C was inserted in 26 patients. Clinical characteristics, complications, and prognosis were also analyzed. **Results:** The two groups did not differ significantly in mean age, male to female ratio, and their underlying disease. Stent occlusion occurred in 3 patients (13%) who received FCSEMS-L and in 13 patients (50%) who received FCSEMS-C. Stent occlusion due to sludge impaction was not occurred in patients with FCSEMS-L, and occurred in 8 patients (34.6%) with FCSEMS-C ($p = 0.010$). There are no difference in mean follow-up period (FCSEMS-L 193.2 days vs FCSEMS-C 278.8 days, $p = 0.236$), stent migration ($p = 0.559$), and cumulative stent patency ($p = 0.691$). Complications, including cholangitis and pancreatitis, were found to be acceptable and resolved by conservative management in both groups. **Conclusion:** Although the use of a FCSEMS-L produced no significant differences in stent patency or stent migration rate, the FCSEMS-L can be used safely in human bile duct and prevent effectively stent occlusion due to sludge impaction.

Keywords: malignant biliary obstruction, large-bore dumbbell-shaped FCSEMS, sludge impaction

EE-0324 (PE-0096) Major bleeding risk of endoscopic sphincterotomy versus endoscopic papillary balloon dilatation in hemodialysis patients

Authors: TZU-WEI YANG[1]; CHI-CHIH WANG[1]; MING-CHANG TSAI[1]; WEN-WEI SUNG[1]; MING-HSENG TSENG[2]; CHUN-CHE LIN LIN[1]

Affiliation: [1]Department of Division of Gastroenterology and Hepatology, Department of Internal Medicine, Chung Shan Medical University Hospital, and [2]Department of Medical Informatics, Chung Shan Medical University, Taichung, Taiwan

Background and Aim: Endoscopic sphincterotomy (EST) and endoscopic papillary balloon dilatation (EPBD) are two methods for therapeutic endoscopic retrograde cholangiopancreatography (ERCP). Although the post-procedure bleeding rate of EPBD is lower in the normal population, the post-procedure bleeding rate in patients with bleeding tendency, i.e. end-stage renal disease is unknown. We aimed to evaluate the post-EST and post-EPBD bleeding rate among hemodialysis patients. **Methods:** As per two million population data selected from Taiwan's National Health Insurance Research Database (NHIRD), patients who had catastrophic illness card of hemodialysis (HD) between January 1, 2004, and December 31, 2011, were collected as research subjects. Rates of major gastrointestinal tract bleeding events occurred within 14 days after EST or EPBD in both HD and non-HD patients were compared. **Results:** A total of 3,561 patients, age above 18-year-old without liver cirrhosis or hematologic diseases, received total 3,826 EST and 280 EPBD procedures during the 8 calendar years enrolled in our analysis. The total post-ERCP major bleeding rate is much higher in HD patients (8.64% vs. 2.16%, $p < 0.0001$). Although post-EPBD major bleeding events are lower (0.75% vs. 2.26%; $p = 0.049$) comparing with post-EST major bleeding events in the normal population, post-procedure major bleeding events rate is similar in HD group (8.70% vs. 8.33%; $p = 0.484$) (Fig. 1). **Conclusion:** Post-ERCP, post-EST, and post-EPBD major bleeding rates are all higher in HD patients. EPBD failed to reduce the bleeding events needed to perform endoscopic hemostasis in HD patients.

Keywords: endoscopic sphincterotomy, endoscopic papillary balloon dilatation, post-procedure bleeding, hemodialysis

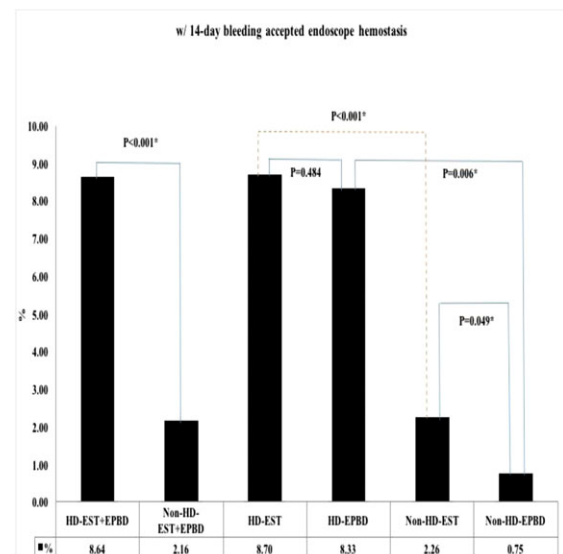


Figure 1. Bleeding HD EST EPBD.

EP-0008 (PE-0097) Endoscopic management of bile duct leak following laparoscopic cholecystectomy: A single center experience in a tertiary care hospital from northern Rajasthan, India

Authors: ZUBIN SHARMA; RAVINDRA SHARMA

Affiliation: Department of Internal Medicine-GI/Hepatology, Aditya Gastro Centre, Sriganganagar, India

Background and Aim: Bile leak is a rare encountered complication commonly seen in the setting of biliary tract surgery. This study is conducted to determine the impact of endoscopic and surgical management in treating symptomatic bile leak. **Methods:** We retrospectively analyzed patients who had bile leak over a period of 3 ½ years from February 2014 to September 2017, 47 patients with bile leak were identified. Site and extent of bile leak was evaluated using MRCP, CECT, and ERCP. ERCP was mainly used as a therapeutic tool rather than a diagnostic tool. Apart from routine medical care, wherever feasible, ERCP was used as a primary mode of definitive treatment in all our patients. Percutaneous biliary drainage was used in technically difficult cases. **Results:** Forty-seven patients with symptomatic bile leak were identified in aforesaid period; 43 patients had bile leak due to post laparoscopic cholecystectomy injury, mostly to cystic duct stump and duct of Lushka, while in 4 patients, it was associated with liver abscess. Major bile duct injury was seen in 14 patients with post cholecystectomy status and in 2 patients with liver abscess. Out of 47 patients, 45 were treated with ERCP and 2 with percutaneous drainage. Surgery was not required in any of the patients. Sphincterotomy along with stent placement for 6 weeks was effective in 44 patients and only sphincterotomy was effective in 3 patients undergoing ERCP. There was no mortality seen due to bile leak. **Conclusion:** Most patients presenting with post cholecystectomy bile duct injury (leak) without complete bile duct transaction can be successfully treated by means of therapeutic endoscopy without the need for surgery.

Keywords:

EP-0014 (PE-0098) Role of endotherapy in inoperable hepatobiliary malignancy: A single center experience

Authors: ZUBIN SHARMA; RAVINDRA SHARMA

Affiliation: Department of Internal Medicine-GI/Hepatology, Aditya Gastro Centre, Sriganganagar, India

Background and Aim: Endoscopic biliary stenting has become a standard palliative treatment for obstructive jaundice due to inoperable malignancies of the pancreas and hepatobiliary system. Self-expandable metal stents (SEMS) has significantly improved the duration of stent patency and increases the life expectancy but the cost is higher. This study aims to report a single center experience to analyze various presentation, treatment modalities including endoscopic, and surgical inoperable pancreato-hepatobiliary malignancies. **Methods:** This observational study was conducted at tertiary referral center from August 2016 to December 2017. The subjects were patients with inoperable malignancies (hepatobiliary and pancreatic). Seventy patients of various age groups (40–90 years) were studied for type of presentation and treatment modalities and outcome. **Results:** Among 70 with inoperable hepatobiliary and pancreatic malignancy were 44. Among inoperable patients cholangiocarcinoma were 9, gall bladder malignancy were 7, pancreatic carcinoma 5, hepatocellular carcinoma with biliary infiltration were 3, and colonic malignancy with liver secondaries and obstructive jaundice were 2. Among 44 patients, 37 patients underwent self-expandable metal stenting (SEMS), 3 patients underwent PTBD (percutaneous transhepatic biliary drainage), and 4 patients underwent palliative diversion surgery. **Conclusion:** Biliary stents have been used in various malignant and benign biliary obstructions. Regardless of number of stents deployed, drainage of more than 50% of the liver volume is important for longer patient survival and endoscopic bilateral metallic stenting could be the preferred treatment for inoperable hepatobiliary and pancreatic malignancies.

Keywords: SEMS, PTBD

EP-0075 (PE-0099) Outcomes and tips of endoscopic therapy for acute cholecystitis**Authors:** MANABU YAMADA; TAKAYUKI FUJIMORI; TOMOKI KONO; MAKOTO ORYU**Affiliation:** Department of Internal Medicine, Kagawaken Saiseikai Hospital, Takamatsu, Japan

Background and Aim: Cholecystectomy is the standard treatment for acute cholecystitis, while in case of increased operative risk, surgery may be postponed or rejected. When percutaneous drainage is difficult, we have performed endoscopic drainage ETGBS (endoscopic transpapillary gallbladder stent) or ETGBD (endoscopic transpapillary gallbladder drainage) with ETCG (endoscopic transpapillary catheterization into the gallbladder). The aim of this study was to assess the success rate and clinical efficacy, and some technical methods of endoscopic gallbladder drainage in patients with acute cholecystitis. **Methods:** A total of 36 consecutive patients with acute cholecystitis who received endoscopic drainage between April 2006 and March 2016 were enrolled in the present retrospective study. The technical success rate, clinical success rate, and complication rate were evaluated. About technique of ETCG, after successful bile duct cannulation, a 0.025 or 0.032-inch guidewire is advanced into the cystic duct and subsequently into gallbladder. Then, catheter is advanced into gallbladder, guidewire is exchanged to the stiff type. Finally, nasobigallbladder drainage tube or stent is placed. But there are some difficult cases. In the lower branch type of cystic duct, seeking of cystic duct is difficult because guidewire is easily bounced to the hepatic side. ENBD tube is useful by fixing pigtail above the bifurcation. When we can not identify the cystic duct, POCS with SpyGlass DS is useful for ETCG. **Results:** The technical success rate was 94% (34/36) and clinical success rate was 100% (34/34). Complication rate was 11.1% (4/36: acute pancreatitis (not severe) in 3 cases and injury of cystic duct in 1 case). **Conclusion:** Endoscopic gallbladder drainage with ETCG technique is safe and effective to treat acute cholecystitis with patients who are unsuitable for cholecystectomy or percutaneous drainage. ETCG with ENBD tube is useful especially in the lower branch type of cystic duct.

Keywords: acute cholecystitis, endoscopic drainage, ERCP**EP-0083 (PE-0100) Post-ERCP pancreatitis: Minimizing role of pancreatic duct stenting with non-invasive combination therapy in difficult cases****Authors:** JING LIANG HO; CHRISTOPHER TZE WEI CHIA; KHOON BENG CHUAH**Affiliation:** Department of Gastroenterology and Hepatology, Tan Tock Seng Hospital, Singapore, Singapore

Background and Aim: Double-guidewire technique (DGT) is a salvage technique frequently used when standard cannulation technique (SCT) is unsuccessful. Instrumentation of the pancreatic duct (PD) has been associated with increased risk of post-ERCP pancreatitis (PEP). Safety of DGT in difficult ERCP access needs to be better defined to determine if it truly affects PEP. **Methods:** A total of 258 ERCP cases between July and December 2017 was retrospectively retrieved and analyzed. We seek to determine the safety of DGT and role of PD stenting in prevention of PEP in the setting of failed SCT. **Results:** Out of the 258 ERCP cases, 13.5% (35 cases) failed SCT and required DGT to facilitate successful biliary access. Out of the DGT cases, rectal NSAID was administered in 65%, PD stenting was performed in 23%, and intravenous lactated Ringer's (LR) was initiated in 83% as PEP prophylaxis. DGT cannulation rate following failed SCT was 83%. The incidence of PEP, infection, significant bleeding, and perforation were 2.9%, 17.1%, 0%, and 0%, respectively. The rate of PEP in the subgroup without PD stent placed was only 3.7%. Impact of PEP prophylaxis was found to be significant for rectal NSAID ($p < 0.01$), PD stenting ($p = 0.039$), and LR hydration ($p < 0.01$). There was no PEP witnessed when at least 2 PEP prophylactic measures were instituted (either rectal NSAID and/or PD stent and/or LR drip). **Conclusion:** Our data demonstrated PEP rates remained low despite performing DGT for difficult biliary access and PEP risk may be minimized even without PD stenting if at least 2 other PEP prophylactic measures are undertaken. This suggests PD stenting may not be critical in this circumstance. A larger prospective study is indicated to evaluate this finding.

Keywords: Post-ERCP pancreatitis, double-guidewire technique, pancreatic duct stent

EP-0149 (PE-0101) Consequences of forgotten biliary stents: A single unit experience

Authors: KOSMAPATABENDIGE USHANTH DALPATADU; LAKMAL DORATIYAWA; UPUL SOMATHILAKA; HIMEERA JAYASINGHE

Affiliation: Department of Gastroenterological Surgery, Kurunegala Teaching Hospital, Kurunegala, Sri Lanka

Background and Aim: Endoscopic stenting of common bile duct (CBD) is performed in obstructive jaundice due to benign or malignant conditions. The objective of CBD stenting is to relieve obstruction and maintain internal drainage of bile. Unlike the metal stents, the plastic stents should be removed after 6–12 weeks to prevent complications. **Methods:** Retrospective, descriptive study of all patients referred/admitted to Gastroenterological surgery unit, T.H. Kurunegala from July 1, 2017 to June 30, 2018 with retained biliary stents for more than 12 weeks. **Results:** Five male patients aged 20 to 79 (median age 66) with retained stents for more than 12 weeks were identified. Four had choledocolithiasis, whilst one had malignant stricture (plastic stent inserted pending metal stent for immediate decompression). The duration from initial stenting ranged from 16 to 176 weeks. Three presented with cholangitis and stent obstruction, one with pain and stone-stent complex, whilst the other was recalled from clinic after review. All knew that they had stents inserted and the necessity for removal within 12 weeks at initial discharge. Three had defaulted due to social circumstances and two did not attend follow up as they were asymptomatic till stent blockage. All had Endoscopic Retrograde Cholangio Pancreaticography (ERCP). Two had migrated stents and one had fragmented stent requiring wide sphincterotomy and sphincteroplasty with balloon sweeping and graspers for removal. All had successful stent removal/reinsertion. **Conclusion:** Endotherapy has revolutionized the management of biliary disease. However, proper patient education and follow up is mandatory as retained stents can act as a nidus for infection and stone formation with complications which may need difficult ERCP management or even surgical intervention. This also stresses the importance of updating the knowledge of the health fraternity and the maintenance of an ERCP registry.

Keywords: plastic biliary stents, obstruction, ERCP

OE-0116 (PE-0102) Liver hydatid cyst in urban referral center: Criteria for the need of biliary stenting

Authors: PANKAJ DESAI[1]; MAYANK KABRAWALA[1]; RAJIV MEHTA[1]; SUBHASH NANDWANI[1]; KEYUR BHATT[2]; DHAVAL MANGUKIYA[2]; CHINTAN PATEL[1]; PARIKA KALRA[1]; RITESH PRAJAPATI[1]; NISARG PATEL[1]

Affiliation: Departments of [1]Internal Medicine-GI/Hepatology [2]Surgery-Hepatobiliary, Surat Institute of Digestive Sciences, Surat, India

Background and Aim: Hydatidosis is a zoonotic infection very common in developing countries. Mostly single organ involvement. Liver represents (50–70%) and lungs (10–30%). Rupture into the biliary tree is the commonest complication (up to 25% of cases). We saw the need for ERC in a good number of cases and analyzed our data to identify the predictors for need of ERC in cases of hydatid cysts in liver. **Methods:** Data from October 2010 to March 2018 for liver cysts were analyzed. Total liver cysts: 67-operated, hydatid cysts: 50 management-cystectomy-non-radical alternative. Cyst de-roofing, cyst content evacuation without removal of priciest, plus or minus omentoplasty and ERC. Preoperatively albendazole to all. Not given: patients with cholangitis due to internal rupture of cyst contents. None of the patient in our series was of type CE 1 (WHO Classification). **Results:** Biliary communication preoperative: 27 (54%) ERC: 18 (66.7%) postoperatively. Cholangitis and jaundice preoperatively: 4 ERC biliary communication on table: 12 (24%). Distance from hilum: ERC group 1.66 cm vs 4.35 cm non-ERC size of cyst—(10.79 cm vs 9 cm), alkaline phosphatase (103.88 vs 62.13, normal up to 80), bilirubin (1.54 vs 0.75)—statistically insignificant. ERC group: hospital stay—9.22 vs 3.2 days; non-ERC combined liver spleen hydatid cyst: 1; mortality 1: average follow up—3 months to 8 years. Fluid collection: 1-PCD. **Conclusion:** Cystectomy—a non-radical alternative of hydatid disease is practical and feasible approach. Preoperative ERC raised bilirubin, alkaline phosphatase, and cholangitis. Post Op ERC: Biliary communication during surgery. Bile leak nearness to the hilum—an important predictor for need of postoperative ERC in our series. However, larger studies are needed to reciprocate the findings. Morbidities higher internal rupture.

Keywords: hydatid cysts, liver, ERC, cholangitis, hilum

OE-0128 (PE-0103) How effective is the endoscopic stenting in management of post-cholecystectomy bile duct injuries: Experience of a tertiary care hepatobiliary center in a developing country

Authors: CHAMILA LAKMAL; MALITH NANDASENA; BAWANTHA DILSHAN GAMAGE; THEJANA WIJERATNE; ALOKA PATHIRANA

Affiliation: Department of Surgery, Faculty of Medical Sciences, University of Sri Jayawardenapura, Colombo, Sri Lanka

Background and Aim: Iatrogenic bile duct injury (IBDI) is the most serious complication of cholecystectomy. Four times higher incidence of IBDI was reported globally in laparoscopy compared to open surgery. Endoscopic stenting is an alternative to surgery in managing IBDI, and data on this aspect are scarce in our setting. **Methods:** Retrospective analysis of patients referred for Endoscopic Retrograde Cholangiogram (ERC) with suspected IBDI following open/laparoscopic cholecystectomy was done. Findings were categorized by Bismuth–Strasberg classification (A–E). E (1–5) were considered as major injuries. The stented patients were evaluated for symptom improvement, need of repeat endoscopy and complications. **Results:** Eighty-seven IBDI was detected during ERC (70% following laparoscopic cholecystectomy). Male:female was 1:3 and mean age was 38.6 years (range 28–70); 53% had minor injuries (Bismuth–Strasberg A–D). Cystic stump leak was the commonest single injury (36%). No difference of injury severity was detected between laparoscopy and open groups ($p = 0.78$) and 78% of injuries detected postoperatively. All the minor injuries ($n = 46$) were stented with 7 Fr or 10 Fr plastic stents. All stented patients needed repeat ERC (two monthly in most cases) with a median number of 5 (range 2–11) and 81% underwent serial dilatation and multiple stenting. All the patients had symptom improvement within 3 months of the initial intervention. In stented group, 5 patients (10%) needed surgery as they developed chronic CBD stricture which were not improved with at least 6 attempts of serial dilatation. Zero mortality was reported in stented group. **Conclusion:** Minor IBDI can be effectively managed with ERC and stenting according to our data. Serial dilatation with repeated ERC is needed in majority but avoiding a major surgery would be an advantage. Number of serial dilations attempted before deciding on reconstructive surgery should be evaluated further as many patients improved after serial dilatation.

Keywords: iatrogenic bile duct injury, ERC, stenting

OE-0200 (PE-0104) Recurrent acute pancreatitis due to pancreas divisum: A rare case ever documented and reported in Indonesia

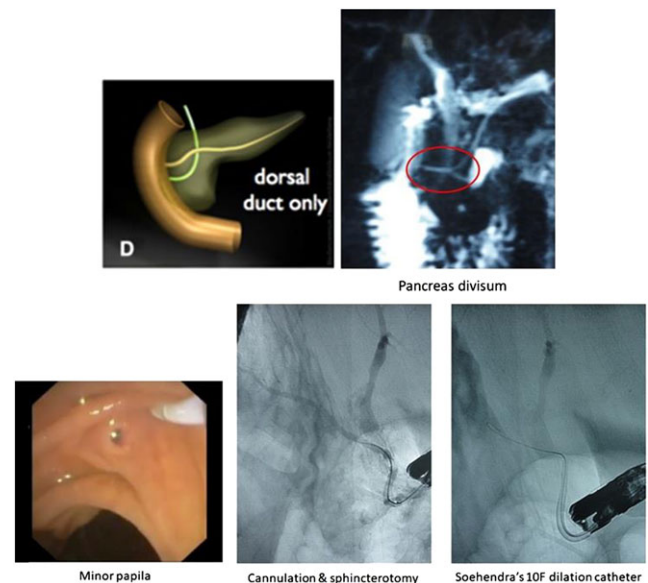
Authors: MUHAMMAD BEGAWAN BESTARI; EKA SURYA NUGRAHA; SITI AMINAH ABDURACHMAN

Affiliation: Department of Internal Medicine-GI/Hepatology, University of Padjadjaran-Hasan Sadikin General Hospital, Bandung, Indonesia

Background and Aim: Pancreas divisum is a condition due to failure of fusion two embryonic part of the pancreas. In Japan and Thailand, this congenital anomaly occurred in 0.64% and 1.6%, respectively. **Methods:** A 39 years old male with abdominal pain referred by secondary care. He had been diagnosed as pancreatitis twice within the last 1 year prior his current admission and undergone MRCP and ERCP. His pancreatic enzymes were very high, MRCP (Picture 1) demonstrated dilatation of dorsal duct that drain to the minor papilla suggestive a complete pancreas divisum, which unfortunately was not diagnosed by doctors in secondary care. ERCP was done demonstrated a stenosis in the minor papilla. Treatment is directed towards relieving outflow obstruction at the level of the minor papillary sphincterotomy and dilation using Soehendra's dilator catheter with successful results. After several days, his condition improved, and the pancreatic enzymes back to normal level. **Results:** Pancreatic divisum is a congenital anatomical anomaly of the pancreas during the eighth week of fetal development. The dorsal pancreatic section drains into the minor duodenal papilla through the major pancreatic duct; the ventral pancreatic duct, the smaller part of the pancreas, merges with the common bile duct at the hepatopancreatic ampulla. Definitive diagnosis is made with either ERCP or MRCP. The choice treatment for symptomatic pancreatic divisum is a sphincterotomy of the minor duodenal papilla with or without dilatation. **Conclusion:** Pancreas divisum is very rare in Asia. This is the first pancreas divisum case successfully treated and reported in Indonesia.

Keywords: pancreas divisum, recurrent pancreatitis, ERCP, sphincterotomy, dilatation

Pancreas divisum—MRCP and ERCP images



OE-0307 (PE-0105) Efficacy and safety of ERCP in patients with gastroesophageal varices**Author:** JUNBO HONG**Affiliation:** Department of Gastroenterology, The affiliated hospital of Nanchang university, Nanchang, China

Background and Aim: Management of pancreaticobiliary disorders concomitant with gastroesophageal varices remain great challenges for clinicians. The present study was to evaluate the efficacy and safety of endoscopic retrograde cholangiopancreatography (ERCP) in patients with gastroesophageal varices. **Methods:** The medical records of consecutive patients with gastroesophageal varices who underwent ERCP due to biliary and pancreatic diseases were retrospectively reviewed and analyzed. **Results:** Two hundred and seventy ERCP procedures (226 cases of cirrhosis and 44 cases of non-cirrhosis) were conducted in 208 patients with gastroesophageal varices. The technical success rate was 98.5%; of these, endoscopic retrograde biliary drainage (ERBD), endoscopic metal biliary endoprosthesis (EMBE) placement, endoscopic retrograde pancreatic drainage (ERPD), and stone extraction were conducted in 173/174 (99.4%), 27/27 (100%), 26/26 (100%), and 116/174 (66.7%) of attempted cases and in 173/270 (64.1%), 27/270 (10.0%), 26/270 (9.6%), and 116/270 (43.0%) of overall cases, respectively. Adverse events included fever ($n = 18$, 6.7%), post-ERCP pancreatitis ($n = 8$, 3.0%), hyperamylasemia ($n = 17$, 6.3%), post-ERCP pancreatitis (PEP) combined with hyperamylasemia ($n = 25$, 9.3%), duodenal papilla bleeding ($n = 9$, 3.3%), cardiac mucosal laceration (3, 1.1%), and perforation ($n = 1$, 0.4%). Additionally, gastroesophageal variceal bleeding occurred in one patient 7 days after ERCP. Most adverse events were mild, transient, and alleviated by conventional therapies. The Child–Pugh scores and MELD scores were not associated with adverse events. A procedure time > 20 min and bougienage of the bile duct stricture were independent risk factors for PEP combined with hyperamylasemia, while ERPD was a protective factor according to the multivariable analysis. **Conclusion:** ERCP is effective and safe for patients with gastroesophageal varices.

Keywords: ERCP, gastroesophageal varices, cirrhosis**OE-0361 (PE-0106) Clinical outcomes of needle knife fistulotomy for rescue treatment****Authors:** HYEONG SEOK NAM; DAE HWAN KANG; HYUNGWOOK KIM; CHEOL WOONG CHOI; SU BUM PARK; SU JIN KIM; DAE GON RYU; JAE PIL LEE**Affiliation:** Department of Internal Medicine-GI/Hepatology, Pusan National University Yangsan Hospital, Yangsan, Republic of Korea

Background and Aim: Endoscopic retrograde cholangiopancreatography (ERCP) is an important procedure for the diagnosis and treatment of patients with biliary tract and pancreatic disease. Needle knife fistulotomy (NKF) is a technique used during ERCP to facilitate access. Double-guidewire technique (DGT) is a method that can be employed in cases of difficult cannulation; however, it can increase post-ERCP-pancreatitis (PEP). This study aimed to evaluate the clinical outcomes of NKF following unsuccessful standard cannulation or DGT in patients with pancreaticobiliary disease. **Methods:** We retrospectively reviewed data of 209 patients who received NKF as a rescue therapy between January 2009 and December 2016. Cannulation success and complication rates according to the primary access methods used were assessed. Additionally, the incidence of pancreatic complications including those associated with pancreatic duct (PD) stenting was assessed. **Results:** The cannulation success rate was 84.9% [174/205]. There was no difference in the success rate between patients who received NKF after standard cannulation and those who received it after DGT (85.9% [146/170] and 85.0% [28/35], respectively, $p = 0.187$). Also, there was no significant difference in the incidence of procedure-related adverse events between patients in the two groups (17.1% [29/170] and 25.7% [9/35], respectively, $p = 0.318$). Endoscopic retrograde pancreatic drainage (ERPD) insertion decreased the incidence of PEP and hyperamylasemia among patients who received PD cannulation (5.0% [1/20] in ERPD and 24.0% [37/154] in non-ERPD, $p = 0.035$). **Conclusion:** The use of NKF for rescue treatment is safe and effective after standard cannulation and guidewire technique. ERPD insertion is effective in reducing procedure-related pancreatic complication such as PEP and hyperamylasemia.

Keywords: endoscopic retrograde cholangiopancreatography, needle knife fistulotomy

OE-0404 (PE-0107) Economic impact of single operator digital cholangioscope in the treatment of pancreatobiliary disorders: Single center experience in Singapore

Authors: YVONNE YL LEE[1]; WEE KHOON NG[2]; KOK PUN CHEN[2]; CHARLES VU[2]; MICHAEL CANGELOSI[1]; WAI LEONG QUAN[2]

Affiliation: [1]Department of Health Economic and Reimbursement, Boston Scientific Asia Pacific, and [2]Department of Internal Medicine-GI/Hepatology, Tan Tock Seng Hospital, Singapore, Singapore

Background and Aim: Cholangioscopic visualization of the pancreatobiliary system for the diagnosis and treatment of lesions in the biliary and pancreatic ducts has been historically limited by technical challenges such as limited field of view, need for two trained operators, and rapid scope damage. A new generation of a single operator digital cholangioscope (SO-DC), SpyGlass DS direct visualization system, addresses these historical shortcomings and advances the practice of cholangioscopy. We aim to evaluate the economic impact of this system from the perspective of a Singaporean, Medisave, and Medishield-unsubsidized patient. **Methods:** An economic assessment of the medical device was performed using a patient budget impact analysis (BIA). The model was developed on an interactive platform to facilitate patient and health-care provider/facility education. The BIA calculations included an estimate of the eligible population and costs of inpatient and outpatient procedures, surgery, and medical device(s). Data required to populate the model were provided by Tan Tock Seng public hospital, and hospitalization cost data were extracted from Ministry of Health published reports. **Results:** We projected cost savings of approximately SGD \$3,000 (rounded to nearest 50 SGD) in making definitive diagnosis for indeterminate strictures, SGD \$1050 in avoiding repeat endoscopic retrograde cholangiopancreatography (ERCP) procedures, and SGD \$26,500 in avoiding unnecessary surgeries due to the use of the SO-DC for each unsubsidized patient. **Conclusion:** Single operator digital cholangioscope is designed to increase diagnostic accuracy, reduce the need for exploratory surgery, and manage indeterminate strictures and large stones in the biliary system when ERCP without SO-DC has been unsuccessful or deemed to be inappropriate. This analysis demonstrates that the use of SO-DC may additionally manifest as reduced out-of-pocket expenditure for unsubsidized patients.

Keywords: direct, visualization, device, economic, Singapore

OE-0498 (PE-0108) A retrospective analysis to assess the importance of doing a biliary sphincterotomy as a method to increase and simplify cannulation success rate of the main pancreatic duct

Authors: PANKAJ DESAI; MAYANK KABRAWALA; SUBHASH NANDWANI; RAJIV MEHTA; CHINTAN PATEL; PARIKA KALRA; RITESH PRAJAPATI; NISARG PATEL

Affiliation: Department of Endoscopy and EUS, Surat Institute of Digestive Sciences, Surat, India

Background and Aim: MPD cannulation is the prime requisite for any pancreatic endotherapy during an ERCP. Very few cannulation techniques are described for pancreatic duct cannulation. Cases with chronic pancreatitis, acute on chronic pancreatitis or cases of acute pancreatitis with ductal leaks, the duodenum, and periampullary region are edematous and make MPD cannulation difficult. If we could get the wire into the CBD first, doing a wide biliary sphincterotomy improved the success of cannulation of the MPD. **Methods:** We studied our data of all cases (1206) for pancreatic ERCP from October 2008 to May 2018 in our tertiary care center. All cases were done by a single operator. All cases where MPD could not be cannulated in three attempts or MPD not cannulated directly in 10 min or CBD cannulated first were studied. When direct MPD cannulation failed, we attempted to cannulate the CBD first or when CBD was first cannulated during an MPD cannulation, we did a biliary sphincterotomy wide enough to separate the biliary and pancreatic orifices and then cannulated the MPD with a cannula and a glide wire. **Results:** Number of ERP: 1206; successful direct MPD cannulation: 982 (81.4%); difficult cannulation: 224 (18.6%); CBD cannulated first: 199 out of 224 (88.9%); biliary sphincterotomy done: 199 (100%); successful MPD cannulation after biliary sphincterotomy: 185 (92.9%); failed MPD cannulation after biliary sphincterotomy: 14 (7.03%); pancreas divisum found: 10 out of 14 failed cannulations (71.4%); failed MPD cannulation overall: 25 out of 1206 (2.07%). **Conclusion:** If direct MPD cannulation is difficult, cannulating the CBD first and doing a biliary sphincterotomy improves the MPD cannulation success rate significantly—81.4% to 92.9%. Of those cases with failed MPD cannulation after biliary sphincterotomy, 71.4% cases had pancreas divisum which was not detected on MRCP or prior imaging.

Keywords: ERCP, pancreatic, sphincterotomy, biliary

OE-0620 (PE-0109) Endoscopic transpapillary biliary biopsy using the sheath of a plastic stent

Authors: SHINICHI MORITA[1]; ITSUO NAGAYAMA[1]; TAKAHIRO HOSHI[1]; SATOSHI ABE[1]; TSUTOMU KANEFUJI[2]; KAZUYOSHI YAGI[1]; TAKESHI SUDA[1]; SHUJI TERA[3]

Affiliation: [1]Department of Gastroenterology and Hepatology, Uonuma Institute of Community Medicine Niigata University Hospital, Minamiuonuma, [2]Department of Internal Medicine-GI/Hepatology, Niigata Prefectural Tokamachi Hospital, Tokamachi, and [3]Department of Internal Medicine-GI/Hepatology, Graduate School of Medical and Dental Sciences, Niigata University, Niigata, Japan

Background and Aim: The purpose of biliary biopsy is for diagnosing cancer and determining cancer extent. Innovations in peroral cholangioscopy have improved diagnostic accuracy, but due to high cost, its benefits are limited only in some facilities. We have reported an endoscopic transpapillary biopsy using the sheath of a plastic stent (ETB-PS) as an alternative method. This study retrospectively evaluated the efficacy of ETB-PS. **Methods:** Sixteen patients underwent ETB-PS from August 2016 to December 2017 (male/female, 14/2; age, 56–85 [median 77] years; benign biliary stricture [BBS]/bile duct cancer [BDC], 2/14). Seven patients underwent surgery. The outcome parameters were sampling adequacy rate for diagnosing cancer, for determining cancer extent, procedural time, and complications. **Results:** Biopsy specimens were successfully sampled in all cases. Mean procedure time was 45 (40–90) min. Acute pancreatitis occurred in one case. In total, 48 specimens (median; three per patient) were obtained from the lesion; the sampling adequacy rate was 77.1% (37/48) and 93.8% (15/16) per patient. The accuracy of distinguishing BBS from BDC was 83.3%, with a sensitivity of 84.6% and specificity of 100%. Additionally, the sampling adequacy for determining cancer extent was only 31.7% (13/41). The accuracy was 87.5%, with a sensitivity of 50% and specificity 100%. The most common cause of inadequate diagnosis was the collection of only fibrous tissues due to mucosal fallout. **Conclusion:** The efficacy of ETB-PS is equivalent to previous reports for diagnosing cancer, but its efficacy in determining cancer extent is inadequate. The reason is many factors such as differences in cancer progression among different morphological types, presence of cholangitis, and mucosal fallout by specimen handling. Evaluating the results and determining the treatment strategy with an understanding of the usefulness and limitations of biopsy for bile duct lesions are important.

Keywords: endoscopic transpapillary biopsy, bile duct cancer, benign biliary stricture, sheath of a plastic stent, peroral cholangioscopy

OE-0850 (PE-0110) Endoscopic retrograde cholangiopancreatography in patients with Billroth II gastrectomy: Side-viewing endoscope or forward-viewing endoscope?

Authors: LEI LU; HANGBIN JIN; GAUNGXIN CUI; JING YANG; JIANFENG YANG; XIAOFENG ZHANG

Affiliation: Department of Gastroenterology, Affiliated Hangzhou First People's Hospital, Zhejiang University School of Medicine, Hangzhou, China

Background and Aim: It is technically challenging to perform endoscopic retrograde cholangiopancreatography (ERCP) in patients with Billroth II gastrectomy. Only few studies have investigated whether the forward-viewing endoscope or the side-viewing endoscope is better for patients with Billroth II gastrectomy. The aim of this study is to assess the efficacy and safety of the forward-viewing endoscope compared with the side-viewing endoscope for ERCP in patients with Billroth II gastrectomy.

Methods: All patients with Billroth II gastrectomy who underwent ERCP at our center from January 2008 and December 2017 were retrospectively reviewed. Data regarding to patients' baseline characteristics, procedure-related details, and adverse events were recorded and analyzed. **Results:** A total of 159 patients (median age 69.4 years, range 40–89 82 females) were enrolled. Of these, 76 patients were initially attempted with the forward-viewing endoscope (FVD group), while others were tried with the side-viewing endoscope first (SVD group). Both groups were comparable in terms of demographic data. The enterography success rate was higher in the FVD group (72/76, 94.7%) than in the SVD group (69/83, 83.1%) ($p = 0.021$). The success rate of ERCP cannulation in those successful afferent loop intubation cases was higher in the SVD group (65/69, 94.2%) than in the FVD group (60/72, 83.3%) ($p = 0.042$). Overall, the ERCP success rate was similar in both group (79% [69/76] vs. 78.3% [65/83], $p = 0.922$). The procedure-related complication rate was 7.9% (6/76) in the FVD group, and 14.5% (12/83) in the SVD group ($p = 0.192$). All of these complications were managed conservatively. **Conclusion:** The forward-viewing endoscope is as safe and effective as the side-viewing endoscope for ERCP in patients with Billroth II gastrectomy. **Keywords:** Billroth II gastrectomy, endoscopic retrograde cholangiopancreatography, forward-viewing endoscope, side-viewing endoscope

EE-0046 (PE-0111) Prospective, multicenter, observational study of tissue acquisition via endoscopic ultrasound-guided fine-needle biopsy using the 25G Franseen needle

Authors: RYO SUGIURA[1]; MASAKI KUWATANI[1]; KEI YANE[2]; YOKO TAYA[3]; HIDEYUKI IHARA[4]; MANABU ONODERA[5]; KAZUNORI ETO[6]; ITSUKI SANO[7]; TAIKI KUDO[8]; TOMOKO MITSUHASHI[9]; AKIO KATANUMA[2]; NAOYA SAKAMOTO[1]

Affiliation: Departments of [1]Gastroenterology and Hepatology [9]Surgical Pathology, Hokkaido University Hospital, [2]Department of Gastroenterology, Teine-Keijinkai Hospital, [3]Department of Gastroenterology, Hokkaido Medical Center, [4]Department of Gastroenterology, Tonan Hospital, [5]Department of Gastroenterology, Ntt East Sapporo Hospital, Sapporo, [6]Department of Gastroenterology, Tomakomai City Hospital, Tomakomai, [7] Department of Internal Medicine, Kushiro Rosai Hospital, Kushiro, and [8]Department of Gastroenterology and Hepatology, Hakodate Municipal Hospital, Hakodate, Japan

Background and Aim: Recently, endoscopic ultrasound-guided fine-needle biopsy (EUS-FNB) using a Franseen needle was developed for histological tissue acquisition. However, the yield of a 25-gauge Franseen needle when acquiring histological core tissue has been unclear. **Methods:** We performed a prospective, multicenter, observational cohort study that included 100 solid lesions scheduled for EUS-FNB using a 25-gauge Franseen needle at eight centers in Hokkaido, Japan. Only EUS-FNB specimens acquired at the first attempt were evaluated without rapid onsite evaluation. The tissue acquisition rate, acquisition rate of an adequate specimen for histological assessment, quality of tissue sample, sensitivity, specificity, positive predictive value (PPV), negative predictive value (NPV), diagnostic accuracy, and adverse events were evaluated. **Results:** We analyzed a total of 100 solid lesions in 100 patients. The patients were 57 males and 43 females with a median age of 70 years. The technical success rate was 100%. The tissue acquisition rate was 95.0%. The acquisition rate of an adequate specimen for histological assessment was 82.0%. The sensitivity, specificity, PPV, NPV, and diagnostic accuracy were 87.0%, 100%, 100%, 40.0%, and 88.0%, respectively. The adverse event rate was 1.0% and was reported in only one patient who had a moderate pancreatic fistula. **Conclusion:** EUS-FNB using the 25-gauge Franseen needle was feasible, and adequate histological core tissue samples were acquired with this method.

Keywords: endoscopic ultrasonography, endoscopic ultrasound-guided fine-needle biopsy, Franseen needle, tissue acquisition

EE-0112 (PE-0112) Idiopathic acute pancreatitis (IAP): The value of endoscopic ultrasound

Authors: BIMAL CHANDRA SHIL[1]; MADHUSUDAN SAHA[2]; RANJIT KUMAR BANIK[3]; SHASANKA KUMAR SAHA[4]; ABU NAYEEM MD SAIFULLAH[5]; MD ROYES UDDIN[6]; MD OMAR FARUQ[7]; MD HABIBUR RAHMAN[8]

Affiliation: Departments of [1]Gastroenterology, [3]Internal Medicine-GI/Hepatology, [4]Internal Medicine-GI/Hepatology, [5]Internal Medicine-GI/Hepatology, [6]Internal Medicine-GI/Hepatology [7]Internal Medicine-GI/Hepatology, [8]Internal Medicine-GI/Hepatology, Sir Salimullah Medical College, Dhaka, [2]Department of Internal Medicine-GI/Hepatology, North East Medical College, Sylhet, Bangladesh

Background and Aim: The causes of acute pancreatitis remain idiopathic in 10–30% of patients. Endoscopic ultrasound (EUS) is an important tool for imaging pancreas and biliary tract. The aim of our study was to evaluate the role of EUS in detecting etiologies in idiopathic acute pancreatitis (IAP). **Methods:** Total 109 consecutive non-alcoholic patients with idiopathic acute pancreatitis were enrolled in this study over a period of 03 years. Detailed history, clinical evaluation, laboratory investigations, and CT and/or MR imaging could not find out the underlying cause of acute pancreatitis. All the patients underwent endoscopic ultrasound (EUS) examinations. **Results:** Among 109 patients, 81 patients had intact gall bladder and 28 patients had history of cholecystectomy. EUS revealed a cause of acute pancreatitis in 46 (56.79%) patients in intact gall bladder group, including microlithiasis and/or gall bladder sludge in 20 (24.69%), chronic pancreatitis (CP) in 12 (14.81%), common bile duct (CBD) stone or sludge in 8 (9.87%), biliary ascariasis in 02, ampullary neoplasm in 02, small pancreatic head tumor in 01, and pancreatic divisum in 01 patient. EUS could detect etiologies in 13 (46.42%) patients of IAP in cholecystectomized patients; CBD sludge or stone in 6 (21.42%), CP in 4 (14.28%), biliary ascariasis in 02, and ampullary neoplasm in 01 patient. Overall, EUS could find out the etiologies in 59 (54.12%) cases among all the IAP patients. Presence of gall bladder provided increased diagnostic yield ($p = 0.343$). **Conclusion:** Endoscopic ultrasound is a very useful procedure with high accuracy towards the etiological evaluation of IAP and should be considered as the first line investigation for the management of patients with unexplained acute pancreatitis.

Keywords: endoscopic ultrasound, idiopathic acute pancreatitis, microlithiasis, CBD stone, gall bladder or CBD sludge

EE-0142 (PE-0113) Clinical significance of extraluminal compressions according to the site of the duodenum

Authors: CHUL BYUNG CHAE; GWANG HA KIM; SANG KYU PARK; MOON WON LEE; BONG EUN LEE

Affiliation: Department of Internal Medicine-GI/Hepatology, Pusan National University Hospital, Busan, Republic of Korea

Background and Aim: It is not easy to differentiate an extraluminal compression from a true subepithelial tumor (SET) in the duodenum by endoscopy alone. Endoscopic ultrasonography (EUS) is known as a most useful diagnostic modality for differentiating an extraluminal compression from a true SET. Extraluminal compression in the duodenum is occasionally observed, but its clinical significance has not been reported. Therefore, the aim of this study was to evaluate the clinical significance of extraluminal compression in the duodenum according to the location of lesion.

Methods: A total of 22 patients diagnosed as extraluminal compression in the duodenum by EUS from January 2006 to December 2017 were retrospectively analyzed. **Results:** The location of extraluminal compression was duodenal bulb in 10 cases, superior duodenal angle in 10 cases, and second portion of the duodenum in 2 cases. Of 22 cases, 12 were caused by normal structures and 10 were caused by pathologic lesions. The causes of normal structures were vessels, right kidney, gallbladder, and pancreas. The causes of pathologic lesions were hepatic cyst, remnant cystic duct, and dilated common bile duct after cholecystectomy, gallstones, gallbladder polyps, remnant cystic duct cancer, and pseudomyxoma peritonei. The anterior wall of the duodenum was the most frequent location of extraluminal compression. However, the lesions in the anterior wall of duodenal bulb and superior duodenal angle showed a high frequency of pathologic lesions including malignancy. **Conclusion:** If the extraluminal compression is found in the anterior wall of the duodenum, EUS is needed because of a high frequency of pathologic lesions.

Keywords: subepithelial lesion, endoscopic ultrasonography, duodenum, endoscopy, extraluminal compression

Causes of extraluminal compression

Causes	Bulb (n = 10)	SDA (n = 10)	Second portion (n = 2)
Normal structures			
kidney	1	1	1
Vessel	2	4	
Gallbladder	1	1	
Pancreas			1
Pathologic lesions			
Hepatic cyst	1	2	
Remnant cystic duct	1	1	
Dilated bile duct	1		
Gallbladder stones	1		
Gallbladder polyps	1		
Remnant cystic duct cancer		1	
Pseudomyxoma peritonei	1		

SDA : superior duodenal angle

EP-0074 (PE-0114) A case of a successful endoscopic ultrasound (EUS)-guided drainage of a large pancreatic pseudocyst with superior extension into the intrathoracic region

Authors: VICTORIA SHINQ LING KOK; JASMINDER SIDHU; ENG SOON TAN

Affiliation: Department of Internal Medicine-GI/Hepatology, Hospital Kuala Lumpur, Kuala Lumpur, Malaysia

Background and Aim: Pancreatic pseudocyst can develop in up to 20% of patients with pancreatitis. Endoscopic ultrasound (EUS)-guided drainage of pseudocysts is now frequently performed in patients who develop complications due to the enlarging size of the pseudocyst. **Methods:** A 64-year-old Indian gentleman with multiple comorbidities initially presented to Institut Jantung Negara (IJN) for severe back pain and hiccups for 1 month. He had history of severe epigastric pain 3 months prior and was treated with analgesics by his local general practitioner. A computed tomography (CT) scan of the thorax was performed to rule out aortic dissection. It showed a left pleural effusion and a cyst-like lesion in the pancreatic body and tail measuring 5 cm × 6 cm. He was subsequently referred to us. **Results:** A diagnostic EUS done showed a large pancreatic pseudocyst. Subsequently, CT pancreatic protocol confirmed the findings of a large peripancreatic pseudocyst measuring 9.3 cm × 11.8 cm × 15.3 cm with superior extension into the intrathoracic cavity. EUS-guided drainage of the pseudocyst was performed with a single double pig tail stent (10F × 5 cm). Turbid fluid was aspirated. He was also given a course of antibiotics. His symptoms improved following drainage. Repeat CT one week later showed reduction in cyst size of more than 50%. **Conclusion:** EUS-guided drainage of pancreatic pseudocysts is a feasible and safe procedure, if done under experienced hands. This therapeutic strategy decreases morbidity and mortality as compared to the surgical and percutaneous approaches.

Keywords: EUS, pancreatic pseudocyst

EP-0089 (PE-0115) EUS-guided biliary drainage for malignant biliary obstruction in patients with surgically altered anatomy and failed ERCP: A single-center retrospective study

Authors: LEI LU; HANGBIN JIN; GUANGXIN CUI; JING YANG; JIANFENG YANG; XIAOFENG ZHANG

Affiliation: Department of Gastroenterology, Affiliated Hangzhou First People's Hospital, Zhejiang University School of Medicine, Hangzhou, China

Background and Aim: Endoscopic biliary stenting for the treatment of unresectable malignant biliary obstruction (MBO) is challenging among patients with surgically altered anatomy, with technical failure rate of enteroscopy-assisted ERCP (e-ERCP) varied from 48% to 70%. EUS-guided biliary drainage (EUS-BD) is a promising novel biliary drainage method, particularly in patients with surgically altered anatomy as it avoids the need for enteroscopy. However, EUS-BD in patients with MBO and surgically altered anatomy has not been well studied. This study aimed to access the efficacy and safety of EUS-BD for MBO in patients with failed ERCP and surgically altered anatomy. **Methods:** All patients with surgically altered anatomy and MBO who underwent EUS-BD between November 2011 and December 2017 were retrospectively identified from a prospective collected database. EUS-guided rendezvous drainage (RV) was initially attempted in cases with accessible duodenum followed by EUS-guided antegrade deainage (AG), and EUS-guided hepaticogastrostomy (HGS) was performed whenever AG failed. Demographics- and procedure-related outcomes were recorded and analyzed. **Results:** A total of 36 patients (median age 63 years, range 43–85 16 females) were enrolled. Patient anatomy consisted of pancreaticoduodenectomy ($n = 14$), Billroth II gastrectomy ($n = 12$), and gastrectomy with Roux-en-Y reconstruction ($n = 10$). Reasons for failed ERCP included failure to reach the ampulla or enteric-biliary anastomosis ($n = 21$), and difficult cannulation ($n = 15$). RV was initially attempted in 15 patients and 10 were succeeded, AG was then attempted in the remaining 31 patients and was successful in 15 cases. EUS-HGS was successfully performed in the remaining 11 cases. Overall, the technical and clinical success rate was 100%. Complications occurred in 3 patients (8.3%), including 1 cholangitis, 1 bleeding, and 1 pneumoperitoneum, and all were managed conservatively. **Conclusion:** EUS-BD is effective and safe for biliary decompression in patients with surgically altered anatomy. Further evaluation and experience of this method are needed.

Keywords: EUS-guided biliary drainage, malignant biliary obstruction, surgically altered anatomy, ERCP

EP-0162 (PE-0116) The prevalence and natural history of upper GI subepithelial tumors: A Korean multicenter survey

Authors: CHANG KYO OH[1]; YU KYUNG CHO[1]; GWANG HA KIM[2]; JI HYUN KIM[3]; TAE HYEON KIM[4]; EUN SOO KIM[5]; EUN KWANG CHOI[6]; JUN-HO CHOI[7]; SEONG HUN KIM[8]

Affiliation: [1]Department of Internal Medicine, The Catholic University of Korea, Seoul, [2]Department of Internal Medicine, Pusan National University Hospital, [3]Department of Internal Medicine, Inje University Busan Paik Hospital, Busan, [4]Department of Internal Medicine, Wonkwang University School of Medicine and Hospital, Iksan, [5]Department of Internal Medicine, Kyungpook National University Hospital, Daegu, [6]Department of Internal Medicine, Jeju National University School of Medicine, Jeju, [7]Department of Internal Medicine, Dankook University Hospital, Cheonan, and [8]Department of Internal Medicine, Chungbuk National University Hospital, Jeonju, Republic of Korea

Background and Aim: Incidental subepithelial tumors (SETs) are frequently found in screening endoscopy in Korea. We aimed to evaluate the prevalence, lesion characteristics, natural history of upper gastrointestinal SETs. **Methods:** We reviewed medical and endoscopic reports of 93,836 subjects who underwent screening endoscopy at eight university hospitals in Korea during 1 year of 2010. Patients with > 1cm sized of SETs were followed up after 2 years using endoscopy or EUS. The growth patterns was analyzed in the one hospital. We evaluated the characteristics and natural courses of those lesions. **Results:** The overall prevalence of upper GI SET among screening endoscopy was 2.70% (2,535/93,836). The mean ages was 54.5 ± 13.0 years. The prevalence of upper GI SET increased with age and was higher in male (M: F = 57.6%:42.4%). The most common location was stomach (76.8%), esophagus (24.5%), and duodenum (3.9%); 3.8% of SET were found in multiple organs. The mean size was 13.2 ± 7.0 mm, mostly located in the 4th layer (65.5%) and 3rd layer (26.7%); 82.4% of 1- to 2-cm-sized SETs 80.4% of > 2-cm-sized SETs were not changed after 2 years follow up; 12.7% of 1- to 2-cm-sized SETs and 9.5% of > 2-cm-sized SETs which were not resected during follow up period became larger after 2 years. However, the median growth rate was less than 1 cm in short axis. **Conclusion:** The upper GI SET was found incidentally in 2.70% of subjects. The most common lesions was stomach and 2/3 of SET were 4th layer mass. Most small subepithelial lesions do not change as shown by endoscopic examination. Even > 2-cm-sized SET, 80% of lesions were not changed after 2 years.

Keywords: subepithelial tumors, prevalence

OE-0069 (PE-0117) A comparative study of the difference in histologic and diagnostic yield between EUS biopsy needles for evaluation of solid masses

Authors: TIING LEONG ANG[1]; LAI MUN WANG[2]; JAMES WEIQUAN LI[1]; ANDREW BOON EU KWEK[1]; PREM THURAIRAJAH[1]; ENG KIONG TEO[1]; KWONG MING FOCK[1]

Affiliation: Departments of [1]Internal Medicine-GI/Hepatology [2]Laboratory Medicine, Changi General Hospital, Singapore, Singapore

Background and Aim: Endoscopic ultrasound (EUS)-guided fine needle biopsy (EUSFNB) has been reported with the use of 19G fine needle aspiration (FNA) and dedicated biopsy needles. Comparisons between biopsy needles are limited compared to comparisons between EUSFNA and EUSFNB. This study investigated the difference in histologic and diagnostic yield between 19G FNA needles, ProCore® biopsy needles and Acquire™ biopsy needles in patients with solid masses. **Methods:** Patients who underwent EUSFNB of solid masses from January 2014 to October 2017 were identified from a database. The difference in histologic and diagnostic yield between biopsy needles was analyzed. **Results:** A total of 114 patients underwent 130 EUSFNB procedures. The median number of needle passes was 2 (range: 1–4). Overall adequate histologic yield was obtained in 70.2%. Positive tissue diagnosis was achieved in 78.9%. The presence of histologic core was significantly associated with a positive diagnosis (98.8% vs. 32.4%, $p < 0.0001$); 19G FNA, 19G ProCore®, 20G ProCore®, 22G ProCore®, and 22G Acquire™ needles obtained histologic core in 65% (26/40), 71.8% (28/39), 70.8% (17/24), 50% (4/8), and 15/16 (93.8%), respectively ($p = 0.171$); 19G FNA, 19G ProCore®, 20G ProCore®, 22G ProCore®, and 22G Acquire™ needles achieved tissue diagnosis in 80% (32/40), 69.2% (27/39), 79.2% (19/24), 87.5% (7/8), and 87.5% (14/16), respectively ($p = 0.867$). The diagnostic yield was significantly higher with EUSFNB of pancreas (92.7%; 38/41), lymph nodes (84.2%; 16/19), and liver (100%; 11/11) compared to gut wall (61.1%; 33/54), $p = 0.026$. **Conclusion:** EUSFNB with acquisition of histologic core improved the diagnostic yield. The 22G Acquire™ needle showed a trend for a higher rate of histologic core compared to the 19G FNA and Procore® biopsy needles.

Keywords: fine needle aspiration, fine needle biopsy, cytology, histology

OE-0124 (PE-0118) Best modality of management of WON-data analysis

Authors: PANKAJ DESAI[1]; MAYANK KABRAWALA[1]; SUBHASH NANDWANI[1]; RAJIV MEHTA[1]; KEYUR BHATT[2]; DHAVAL MANGUKIYA[2]; CHINTAN PATEL[1]; PARIKA KALRA[1]; RITESH PRAJAPATI[1]; NISARG PATEL[1]

Affiliation: Departments of [1]Internal Medicine-GI/Hepatology [2]Surgery-Hepatobiliary, Surat Institute of Digestive Sciences, Surat, India

Background and Aim: Comparison data of Won management—8 years.

Methods: Acute pancreatitis between October 2010 and March 2018: 1980 necrotizing pancreatitis: 608 (30.7%); walled of necrosis: 283 (46.5%); procedures: open surgery, endoscopic transgastric minimal access necrosectomy (MAN): sessions open: 1/46 of 53 (86.8%), repeat: 7/48 (14.5%) sessions MAN: 58/61 (95.1%) sessions endoscopy: average 4; time: session 1–25 min (plastic stents), 15 min (metal stents). Sessions 2 and 3—20 min. Follow up 8 years. **Results:** Type procedures endoscopic: 169; transgastric: 19; laparoscopic: 12; retroperitoneal: 22; retroperitoneal videoscopic: 8; conventional: 53; bleeding: 3—endoscopy; 1—open; 1—MAN; endoscopic: surgery rest 4; angioembolization mortality: 1 wound infections—44/9; open/MAN, intestinal fistulae: 4/1—open/MAN. Pulmonary complications: 26, 8, and 3—open, MAN, and endoscopy ICU stay—MAN 3.57/8.14 open/2.04 endoscopy. After ICU stay: 11.33 vs 12.7 vs 11.8—open/MAN/endoscopy mortality—(0.6%) endoscopy/3 (5.35%) in MAN/12 (25%) open. Incisional hernia: 8/3—open/MAN timing of endoscopy: 45th day (32–75), MAN—34th day (24 to 50) and open—33rd (18 to 40). **Conclusion:** Later, the better endoscopic necrosectomy—best if $< 50\%$ necrosis MAN $> 50\%$ necrosis. Fistula—open—MAN $>$ endoscopy bleeding: open $>$ endoscopy endoscopy: not early sepsis: open and MAN. Pulmonary complications, ICU, and mortality: More in open and MAN mortality in endoscopy: 1. Sepsis.

Keywords: necrosis, pancreas, endosono, surgery, drainage

Findings Table

	Trans Gastric Surgery	Laparoscopic Surgery	Retroperitoneal MAS	Retroperitoneal+ MAS + Open	Conventional Open	Endoscopic Drainage
No. of Procedures	19	12	22	8	53	169
Avg. Sessions for Clearance	1.2 (1 to 3)	1.5 (1 to 3)	1.4 (1 to 3)	1.4 (1 to 3)	1.1 (1 to 2)	3.4 (2 to 5)
Significant Bleed	3	0	1	0	3	3
Wound Infections	-	-	9	-	44	0
Internal Fistula	-	0	1	0	4	0
Pulmonary Complications	-	-	8	-	28	3
Avg. ICU Stay	-	-	3.57	-	8.14	2.04
Avg. hospital Stay after ICU	-	-	12.7	-	11.33	11.8
Mortality	-	-	3 (5.35)	-	12 (25%)	1 (0.6%)
Avg. Time of Intervention	-	-	34 th day	-	33 th day	45 th day
Amount Of Necrosis	40-70%	50-70%	70-100%	90-100%	80-100%	30-50%
Clearance of Necrosis	97.3%	95.2%	90.1%	88.5%	98.1%	92.3%

OE-0302 (PE-0119) A retrospective study comparing the Franseen and Lancet needles in EUS-FNA of solid pancreatic lesions

Authors: YUKI ISHIKAWA-KAKIYA;
HIROTSUGU MARUYAMA; KAPPEI HAYASHI;
YOSUKE KINOSHITA; KOJIROU TANOUE;
MASAFUMI YAMAMURA; MASAKI OMINAMI;
SHUSEI FUKUNAGA; YASUAKI NAGAMI; KOICHI TAIRA;
HIROKAZU YAMAGAMI; TETSUYA TANIGAWA;
TOSHIO WATANABE; YASUHIRO FUJIWARA

Affiliation: Department of Gastroenterology, Osaka City University School of Medicine, Osaka, Japan

Background and Aim: Endoscopic ultrasound-guided fine-needle aspiration (EUS-FNA) is useful for the diagnosis of solid pancreatic lesions. A Lancet needle (L-needle) is usually used with good cytological results for the diagnosis of malignant or benign lesions. However, not all cases can be cytologically diagnosed using EUS-FNA alone. The amount of tissue is important for difficult-to-diagnose cases such as autoimmune pancreatitis and unique pancreatic tumors. The Franseen needle (F-needle) was designed for performing EUS-fine-needle biopsy (FNB) sampling and is expected to improve the diagnostic yield. We hypothesized that the F-needle was better than the L-needle in terms of accuracy of histological diagnosis. We retrospectively investigated this hypothesis. **Methods:** We retrospectively analyzed consecutive patients who had undergone EUS-FNA for solid pancreatic lesions. In this study, 125 patients were recruited between January 2015 and September 2017. The main outcome measurement was the accuracy of EUS-FNAB. We compared the L- and F-needle groups retrospectively. **Results:** We enrolled 125 patients. The L-needle group consisted of 113 cases; and F-needle group, 12 cases. The size of the lesions was significantly bigger, and the rate of trainee endoscopists was higher in the F-needle group than in the L-needle group ($P = 0.03$ and $P = 0.0002$, respectively). The sensitivity and specificity were 79.3% and 100%, respectively, in the L-needle group and both 100% in the F-needle group. The accuracy of diagnosis was 85.0% in the L-needle group and 100% in the F-needle group, but the difference was not significant. However, the F-needle group had significantly better histological results ($P = 0.02$). No adverse events occurred in both groups. **Conclusion:** For

histological diagnosis, the F-needle was better than the L-needle. The F-needle may improve the diagnostic accuracy for solid pancreatic lesions and contribute to the diagnosis of difficult cases.

Keywords: EUS-FNA, solid pancreatic lesion, Franseen needle, Lancet needle, accuracy

OE-0514 (PE-0120) Comparison between endoscopic ultrasonography and abdominal pelvic CT in diagnosis of gastric subepithelial tumors

Authors: SANG YOON KIM[1]; KI-NAM SHIM[1];
JOO HO LEE[2]; JI YOUNG LIM[1]; TAE OH KIM[1];
A REUM CHOE[1]; CHUNG HYUN TAE[1];
SEONG-EUN KIM[1]; HYE-KYUNG JUNG[1];
CHANG MO MOON[1]; SUNG-AE JUNG[1]

Affiliation: Departments of [1]Internal Medicine-GI/Hepatology [2]Surgery, Ewha Womans University Mokdong Hospital, Seoul, Republic of Korea

Background and Aim: Endoscopic ultrasonography (EUS) is the most preferred imaging procedure for the evaluation of gastric subepithelial tumors (SETs). Recent advances in computed tomography (CT) technology have provided more accurate diagnostic potential for the evaluation of hollow organ. The purpose of this study is to determine if (i) abdominal pelvic CT (APCT) can be sufficient to diagnose gastric SETs (ii) Is EUS superior to APCT in diagnosing gastric SETs? **Methods:** We reviewed the retrospectively collected data of 90 patients who underwent laparoscopic wedge resection for gastric SETs from January 2010 to December 2017 at our institution. Based on surgical histopathology results, we reviewed the presumptive diagnosis of preoperative EUS and APCT. We calculated the diagnostic efficacy of APCT compared to EUS. **Results:** Of the 90 patients for SETs, EUS detected 28/35 cases and APCT detected 46/60 cases in malignant SETs. Meanwhile, EUS detected 7/22 cases and APCT detected 3/26 cases in benign SETs. In malignant SETs, EUS and APCT respectively showed sensitivity (80.0% vs 76.7%), specificity (50.0% vs 50.0%), positive predictive value (71.8% vs 78.2%), and negative predictive value (66.1% vs 48.1). **Conclusion:** Both EUS and APCT has enough sensitivity but low specificity in diagnosing gastric SETs. Compared to

Table 1 Accuracy of EUS and APCT for the diagnosis of SETs

Type of subepithelial tumors	Histopathology results, n(%)	EUS findings				APCT findings				P value		
		correct	wrong	Not performed	accuracy, n/total(%)	correct	wrong	possible	undetected		Not performed	accuracy, n/total(%)
GIST	62 (68.9)	28	6	28	28/34 (82.4)	45	4	5	5	3	45/59 (76.3)	0.96
Lymphoma	1 (1.1)		1		0/1 (0.0)	1					1/1 (100.0)	>0.99
Leiomyoma	11 (12.2)	3	6	2	3/9 (33.3)	0	7	2	1	1	0/10 (0.0)	0.09
Ectopic pancreas	9 (10.0)	4	3	2	4/7 (57.1)	1	4	1	3		1/9 (11.1)	0.11
Schwannoma	3 (3.3)		3		0/3 (0.0)		1	2			0/3 (0.0)	>0.99
Lipoma	1 (1.1)		1		0/1 (0.0)	1					1/1 (100.0)	>0.99
Gastric duplication	1 (1.1)	1			1/1 (100.0)	1					1/1 (100.0)	>0.99
Fibromatosis	1 (1.1)			0	0/0		1				0/1 (0.0)	-
Adenomyoma	1 (1.1)		1		0/1 (0.0)				1		0/1 (0.0)	>0.99

Abbreviations: EUS: endoscopic ultrasonography, APCT: abdomino-pelvis CT, SETs: subepithelial tumors, GIST: gastrointestinal stromal tumor

Table 2 Sensitivity, specificity, predictive values of EUS and APCT in diagnosis of SETs

Histopathology results	EUS					APCT				
	Accuracy, n/total	Sensitivity	Specificity	PPV	NPV	Accuracy, n/total	Sensitivity	Specificity	PPV	NPV
Malignant	28/35	80.0	50.0	71.8	66.1	46/60	76.7	50.0	78.2	48.1

Abbreviations: EUS: endoscopic ultrasonography; APCT: abdomino-pelvic CT; SETs: subepithelial tumors; PPV: Positive predictive value; NPV: Negative predictive value

EUS, APCT is a useful for the evaluation of malignant gastric SETs. However, APCT has a limit to distinguish benign gastric SETs than EUS. In addition, EUS imaging alone is insufficient to accurately diagnose 3rd and 4th layer hypoechoic masses, especially GIST and leiomyoma.

Keywords: gastric subepithelial tumors, endoscopic ultrasonography, abdominal pelvic CT, diagnostic efficacy

OE-0687 (PE-0121) High diagnostic value of endoscopic ultrasound elastography for differentiating ampullary adenoma and adenocarcinoma with high diagnostic consistency with positron emission tomography/computed tomography: A prospective cohort study from a single center

Authors: KAUN CHIH CHEN[1]; YU-TING KUO[2]; TSU-YAO CHENG[3]; MEI-FANG CHENG[4]; HSIU-PO WANG[3]

Affiliation: [1]Department of Internal Medicine, Far Eastern Memorial Hospital, New Taipei City, Departments of [2]Integrated Diagnostics and Therapeutics, [3]Internal Medicine, and [4]Nuclear Medicine, National Taiwan University College of Medicine and Hospital, Taipei, Taiwan

Background and Aim: To differentiate ampullary adenocarcinoma from adenoma is essential before endoscopic papillectomy. Although there have been several modalities for doing this, the potentially additional diagnostic value of endoscopic ultrasound (EUS) elastography has never been investigated, and neither has its diagnostic performance in comparison with positron emission tomography-computed tomography (PET-CT) been studied. We aimed to demonstrate the diagnostic value of EUS elastography for differentiating ampullary adenocarcinoma from adenoma, and its diagnostic performance in comparison with PET-CT was also studied. **Methods:** From May 2011 to June 2015, the patients with ampullary tumor who ever received EUS elastography were included for analysis. The ampullary tumors were divided into two groups according to elastography pattern (blue: harder; green: softer). Among these patients, those who received PET-CT were also included for analysis to study the diagnostic consistency of these two modalities. Final pathological diagnosis was made either by endoscopic biopsy or surgical resection. **Results:** In total, 19 patients with ampullary tumor who received EUS elastography were included in this study. The sensitivity, specificity, positive predictive value, negative predictive value, and accuracy of EUS elastography for differentiating ampullary adenocarcinoma and adenoma were 90.9%, 87.5%, 90.9%, 87.5%, and 89.5%, respectively. Among these patients, 10 patients (52.6%) received PET-CT study. In total, 5 patients with final diagnosis of ampullary adenocarcinoma had positive fluorine-18 fluorodeoxyglucose uptake and blue pattern on elastography. On the other hand, 5 patients with final diagnosis of ampullary adenoma had negative fluorine-18 fluorodeoxyglucose uptake and green pattern on elastography. **Conclusion:** EUS elastography has high diagnostic value for differentiating ampullary adenocarcinoma from adenoma with high diagnostic consistency with PET-CT. It may be a useful workup tool before endoscopic papillectomy.

Keywords: endoscopic ultrasound elastography, ampullary adenoma, ampullary adenocarcinoma, positron emission tomography computed tomography

OE-0741 (PE-0122) Endoscopic ultrasound-guided transhepatic antegrade bile duct access for patients with common bile duct stones or obstruction

Authors: NAN GE; SIYU SUN

Affiliation: Department of Endoscopy center, Shengjing Hospital of China Medical University, Shenyang, China

Background and Aim: Since the advent of endoscopic ultrasound (EUS)-guided biliary drainage in 2001, the efficacy of this intervention has been amply demonstrated. EUS-guided antegrade (EUS-AG) stenting technique is one of this intervention, which is a treatment option for patients with bile duct stones (BDS) or obstruction in whom ERCP has failed, primarily as a consequence of surgically altered anatomy, duodenal obstruction, or inability to cannulate the papilla. The aim of this study was to evaluate the technical feasibility and efficacy of EUS-AG. **Methods:** We retrospectively reviewed the patients who underwent EUS-AG in Shengjing Hospital of China Medical University. This research has been approved by the ethical committee of Shengjing Hospital. **Results:** Seven patients with failed ERCP attempt were enrolled in this study (4 males; the mean age 65 years old). EUS-AG bile duct drainage was performed in 3 patients, and EUS-AG BDS removal was performed in 4 patients (Fig. 1). One patient was failed because the guide wire could not pass the malignant stenosis in common bile duct and only performed EUS-guided hepaticogastrostomy. The overall technical successful rates is 86% and clinical successful rates is 100%. None of the patients were performed puncture site closure. Severe complications were not occurred. Post procedure mild abdominal pain was found in one patient (14%). Other minor complications such as cholangitis, infection, pancreatitis, and fever were not found. **Conclusion:** EUS-AG has the potential to be an effective and safe alternative management method for biliary disorders in patients with surgically altered anatomy or failed papilla cannulation.

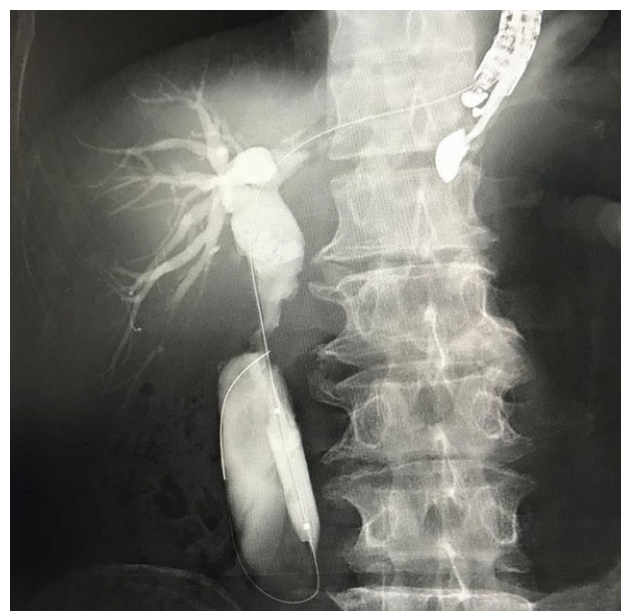

Figure 1

Keywords: antegrade drainage, endoscopic ultrasound, bile duct stones

OE-0766 (PE-0123) The underutilization of EUS-guided biliary drainage: Perception of endoscopists in the East and West

Authors: WON JAE YOON[1]; DO HYUN PARK[2]; JUN HO CHOI[3]; TAE HOON LEE[4]; WOO HYUN PAIK[5]; DONGWOOK OH[2]; TAE JUN SONG[2]; JOON HYUK CHOI[6]; SANG SOO LEE[2]; DONG-WAN SEO[2]; SUNG KOO LEE[2]; MYUNG-HWAN KIM[2]

Affiliation: [1]Department of Internal Medicine, Ewha Womans University Mokdong Hospital, [2]Department of Internal Medicine-GI/Hepatology, Asan Medical Center, [5]Department of Internal Medicine-GI/Hepatology, Seoul National University Hospital, Seoul, [3] Department of Internal Medicine-GI/Hepatology, Dankook University Hospital, [4]Department of Internal Medicine-GI/Hepatology, Soon Chun Hyang University Cheonan Hospital, Cheonan, and [6] Department of Internal Medicine-GI/Hepatology, Inje University Haeundae Paik Hospital, Busan, Republic of Korea

Background and Aim: EUS-guided biliary drainage (EUS-BD) is increasingly utilized to manage unresectable malignant biliary obstruction after a failed ERCP. However, there is no data on how endoscopists perceive EUS-BD. The aim of this study was to investigate the perception of endoscopists on EUS-BD. **Methods:** A survey questionnaire of 6 topics and 22 questions was developed. A total of 17 pancreatobiliary endoscopists (10 from East and 7 from West) were invited to survey. The survey included the following topics: (i) Definition, (ii) Indication, (iii) Resource Requirement and Training, (iv) Techniques, (v) Outcomes of EUS-BD in Expert Hands, and (vi) Areas of Further Research. The opinions of the participants for individual survey statements were assessed using 5-point Likert scale. **Results:** All participants completed the survey. The topic of “Outcomes of EUS-BD in Expert Hands” had the significantly lowest overall mean score. The endoscopists had a trend to perceive EUS-BD as a procedure indicated after a failed ERCP. Various EUS-BD methods were regarded as having different efficacy and safety. Superiority of EUS-BD over percutaneous transhepatic biliary drainage (PTBD) with regard to efficacy, procedure-related adverse events, and unscheduled re-intervention was not in agreement. **Conclusion:** EUS-BD was not yet perceived as the initial procedure to relieve unresectable malignant biliary obstruction. Various EUS-BD methods were regarded as having different efficacy and safety. Superiority of EUS-BD over PTBD was not in agreement. Refining the procedure, developing dedicated devices, and gaining expertise in the procedure are necessary to popularize EUS-BD.

Keywords: endoscopic ultrasound, biliary drainage, perception

Table 1 Survey topics and scores[illegible]

OE-0867 (PE-0124) The diagnosis of invasion depth in superficial esophageal squamous cell carcinoma: Efficacy of endoscopic ultrasonography a single center trial

Authors: NORIKO MATSUURA; RYU ISHIHARA;
SATOKI SHICHIJO; AKIRA MAEKAWA;
TAKASHI KANESAKA; YOJI TAKEUCHI; KOJI HIGASHINO;
NORIYA UEDO

Affiliation: Department of Gastrointestinal Oncology, Osaka International Cancer Institute, Osaka, Japan

Background and Aim: The diagnosis of cancer invasion depth is crucial for selecting the optimal treatment strategy for superficial esophageal squamous cell carcinoma (SESCC). Magnifying endoscopy with narrow-band imaging (ME-NBI) is useful for diagnosis SESC invasion depth. However, microvascular patterns cannot be observed occasionally because the intra-epithelial capillary loop is inaccessible. Endoscopic ultrasonography (EUS) is also an effective modality but needs additional endoscopy, is time-consuming, and its cost-effectiveness is unknown. We investigated the role of EUS in diagnosing invasion depth in SESC. **Methods:** Patients with SESC and suspected muscularis mucosa invasion were included. All patients received WLI and ME-NBI followed by EUS. ME-NBI was performed based on the Japan Esophageal Society (JES) classification. EUS was performed using a high-resolution probe by jelly-filled method. Cancer invasion depth was diagnosed as SM1 or SM2< using each modality. All EUS images were assigned a level of confidence to the prediction (high or low). High or low confidence was defined as tumor echoic area with or without repeatability. The diagnostic accuracy was analyzed while the histologic diagnosis of resected specimen served as reference standard. **Results:** From May 2015 to March 2018, ninety-five lesions treated either by esophagectomy or endoscopic resection. Histologic diagnosis was EP-SM1/SM2 in 55/40 lesions. The accuracy of invasion depth in WLI followed by ME-NBI and WLI, ME-NBI followed by EUS was 71% and 79% ($P = 0.18$), respectively. The overall accuracy of diagnosing invasion depth for lesions with protrusions in WLI followed by ME-NBI and WLI, ME-NBI followed by EUS was 71% (30/42 lesions) and 79% (33/42 lesions) ($P = 0.45$), respectively. The positive predictive value (PPV) in EUS SM2 high confidence and SM2 low confidence was 48% (10/21)

and 81% (21/26) ($P = 0.06$). **Conclusion:** The confidence level in EUS may affect the diagnosis of invasion depth for SESCO.

Keywords: esophageal cancer, EUS, magnifying NBI

OE-0891 (PE-0125) Safety and adverse events of EUS-guided ethanol ablation for pancreatic cystic lesions: A single center experience with 231 patients

Authors: BANG SUP SHIN; SANG HYUB LEE; YOUNG HOON CHOI; MIN SU YOU; WOO HYUN PAIK; JI KON RYU; YONG-TAE KIM

Affiliation: Department of Internal Medicine-GI/Pancreatobiliary, Seoul National University Hospital, Seoul, Republic of Korea

Background and Aim: Endoscopic ultrasound guided-ethanol ablation (EUS-EA) for pancreatic cystic lesions (PCLs) has been used in recent years as a feasible treatment modality for low malignant probability of PCLs or high surgical risk patients. The aim of this study was evaluation of the safety of EUS-EA by the adverse event based on experience of the large number of patients. **Methods:** Retrospective review of adverse events was performed in the prospectively maintained database of patients who diagnosed with PCLs and treated with EUS-EA from June 2006 to February 2018 at Seoul National University Hospital. Patients who underwent cystic fluid analysis and followed up more than once after EUS-EA for PCLs except pseudocyst or cystic degeneration of solid mass were analyzed. **Results:** A total of 230 patients were evaluated, and the diagnosis of PCLs according to cystic fluid analysis were as follows: serous cystic neoplasm (67, 29.1%), mucinous cystic neoplasm (36, 15.7%), intraductal papillary mucinous neoplasm (IPMN) (17, 7.4%), uncategorized cyst (84, 36.5%), and pseudocyst (26, 11.3%). Overall rate of adverse events was 34.3% including 22.6% of abdominal pain, 10.9% of acute pancreatitis and 2 patients (0.87%) were experienced severe adverse event. IPMN (OR = 4.232, 95% C.I. 1.349–13.282), PCLs of uncinate process (OR = 2.849, 95% C.I. 1.031–7.873, $P = 0.043$), and multilocular cysts (OR = 4.596, 95% C.I. 1.375–15.372, $P = 0.013$) were revealed as the risk factors for acute pancreatitis. **Conclusion:** EUS-EA is a safe procedure with a very low rate of severe adverse events. It seems to be possible to predict the adverse events of EUS-EA according to the features of PCLs, and these results may help to establish the proper indication of EUS-EA.

Keywords: EUS, ethanol, ablation

OE-0907 (PE-0126) The value of the cytology guideline for pancreatic cancer by EUS-FNAC

Authors: HIROTSUGU MARUYAMA; YUKI ISHIKAWA; YOSUKE KINOSHITA; KAPPEI HAYASHI; KOJIRO TANOUÉ; MASAFUMI YAMAMURA; MASAKI OMINAMI; SHUSEI FUKUNAGA; YASUAKI NAGAMI; KOICHI TAIRA; KAZUHIRO YAMAGAMI; TETSUYA TANIGAWA; TOSHIO WATANABE; YASUHIRO FUJIWARA

Affiliation: Department of Gastroenterology, Osaka City University School of Medicine, Osaka, Japan

Background and Aim: Guidelines for cytology in Japan were issued in November 2015, and in the 7th edition of the Handling of Pancreatic Cancer, this report style and description of the judgment were quoted. Endoscopic ultrasound-guided fine needle aspiration cytology (EUS-FNAC) for pancreatic disease is mainly used for diagnosis of benign or malignancy. However, guidelines for cytology of pancreatic tumor are based on bile juice cytology, and verification of its usefulness is not sufficient. We retrospectively investigated the usefulness of this guideline. **Methods:** Overall, 121 patients who had performed EUS-FNA for pancreatic tumor were recruited from November 2015 to December 2017 for this study. Among them, 63 patients who were diagnosed pancreatic cancer were recruited. The cell clusters and individual cells were diagnosed by cell technologist and pathologist. We excluded from cases not described in the pathological reports. **Results:** The sensitivity of EUS-FNAC was 73%, and FNAB was 79%. The needle size was selected by each endoscopist. There was no adverse event. In the results of EUS-FNAC, 17 cases were false negatives and 46 cases were positive cases. We investigated factors contributing to the diagnosis of pancreatic cancer. We analyzed false negative/positive as the objective variable using logistic regression analysis. Among the items of guidelines for cytology in Japan, various size of nuclear was statistically significant as a factor contributing to diagnosis of malignancy ($P < 0.05$). **Conclusion:** In the results of EUS-FNAC at our hospital, various size of nuclear was a factor contributing to the diagnosis of malignancy.

Keywords: EUS-FNAC, pancreatic cancer, cytology

OE-0919 (PE-0127) Diagnostic accuracy of computed tomography scan, keeping endoscopic ultrasonography as gold standard for detection of pancreatic carcinoma in Pakistani population

Author: TALAL KHURSHID

Affiliation: Department of Gastro, Holy Family Hospital, Islamabad, Pakistan

Background and Aim: Endoscopic ultrasonography (EUS) and computed tomography (CT) scan are diagnostic techniques that are considerably important in preoperative diagnosis of pancreatic carcinoma (CA). Even though EUS has been confirmed to be more effective in accurate diagnosis but CT scan is still used commonly being easily accessible, cost-effective, and non-invasive in most of developing countries. The objective of this study was to determine the diagnostic accuracy of CT scan findings keeping EUS as the gold standard procedure. **Methods:** This cross-sectional study was conducted at the liver center of Holy Family Hospital, where all 75 suspected cases of pancreatic CA patients who underwent both; computed tomography and EUS, each diagnostic procedure performed by same team of radiologists and gastroenterologists, respectively, in the year 2014 were included. The diagnosis of each individual patient for carcinoma of pancreas, confirmed through EUS, was taken as gold standard. Sensitivity, Specificity, Positive, and Negative predictive values along with 95% confidence intervals (CI) were calculated. Diagnostic accuracy of CT scan compared to EUS was also thereby calculated. **Results:** Sensitivity and Specificity of CT scan was found to be as 97.14% (CI = 85.08–99.93%) and 95% (CI = 83.08–99.39%). The positive predictive value was calculated as 94.44% (CI = 81.74–99.32%) while negative predictive value was 97.44% (CI = 86.52–99.94%). Diagnostic accuracy was 96%. **Conclusion:** The diagnostic capability of CT scan in diagnosis of pancreatic CA is almost nearly effective to EUS.

Keywords: endoscopic ultrasonography, computed tomography, pancreatic cancer

OE-0960 (PE-0128) Endoscopic ultrasonography as a diagnostic tool for the evaluation of suspected rectal subepithelial lesion: A single center retrospective review

Authors: EUI JUNG KIM; JIN TAE JUNG;

JOONG GOO KWON; EUN YOUNG KIM

Affiliation: Department of Internal Medicine-GI/Hepatology, Daegu Catholic University Medical Center, Daegu, Republic of Korea

Background and Aim: Endoscopic ultrasonography (EUS) is now widely used as an important diagnostic tool for various gastrointestinal diseases including subepithelial lesions (SEL). However, most EUS exams were conducted for upper gastrointestinal SEL and reports about rectal SEL are rare. We investigated usefulness of EUS in evaluating suspected rectal SEL.

Methods: We reviewed 242 consecutive EUS reports of suspected rectal SEL on endoscopy which had been performed in Daegu Catholic University Medical Center between August 2001 and November 2017. Analysis was done for 122 of 242 cases which had final diagnosis. **Results:** Mean age of 122 patients was 50.1 years (range, 16–81) and male to female ratio was 2.1:1. Mean of the largest diameter of the lesion was 8.4 mm (range, 2.3–84 mm). Echogenicity of the lesion was mostly hypoechoic. Five cases were extramural lesions and 117 cases were intramural lesions by EUS. The most commonly involved layer was second layer (110/122, 90.2%) for intramural lesions. Final diagnostic or therapeutic modality was chosen according to EUS results: endoscopic resection (112/122, 91.8%), EUS-guided fine needle aspiration (FNA) (3/122, 2.5%), and surgery (7/122, 5.7%). EUS-FNA was performed for 3 cases of extramural lesion and final diagnosis was obtained without complication. The most common final diagnosis was carcinoid tumor (95/122, 77.9%). Others include adenocarcinoma, gastrointestinal stromal tumor, leiomyoma, and malignant schwannoma. Presumptive image-based diagnosis by EUS was correct in 88.5% (108/122). **Conclusion:** EUS is a good diagnostic tool to differentiate intramural lesions from extramural lesions when those were suspicious of SEL from endoscopy. EUS shows 88.5% diagnostic accuracy in evaluation of rectal SEL by the originating layer and echotexture. EUS was helpful in choosing suitable modality for tissue harvest or definite treatment.

Keywords: endoscopic ultrasonography, subepithelial lesion, rectum

OE-0971 (PE-0129) The diagnostic efficacy of contrast enhanced-endoscopic ultrasonography in differential diagnosis of gastric gastrointestinal stromal tumor (GIST) and non-gastrointestinal stromal tumor

Authors: HYUNGKIL KIM; HYUNIL JANG; GYESOOK GWON; YONWOON SHIN

Affiliation: Department of Internal Medicine-GI/Hepatology, Inha University Hospital, Incheon, Republic of Korea

Background and Aim: The differential diagnosis of GISTs is important because of malignant potential, in contrast to other SETs. Endoscopic ultrasound (EUS) and contrast-enhanced endoscopic ultrasound (CE-EUS) is frequently used to diagnose GISTs; however, the characteristic features to distinguish GISTs from other SETs are still unknown. The aim of this study is to find specific features on CE-EUS in differential diagnosis of GIST with other SETs. **Methods:** The presence and degree of tumor vessel in the SET on CE-EUS was evaluated. In addition, the SETs were classified also according to enhancement pattern as hypoenhancement, isoenhancement, and hyperenhancement. The results were compared to histological diagnosis, in which obtained by EUS-guided fine needle aspiration with biopsy or/and surgical resection. **Results:** Seventeen of 25 SETs were diagnosed as GIST by histological results. Six SETs were diagnosed as leiomyoma and 2 SETs were schwannoma. The presence of tumor vessel was significantly related to GIST (Odds ratio, 4.250; 95% confidential interval, 1.8–10.0; $P < 0.001$); 1 or 2 tumor vessels (1+) in 5 cases, 2 or 3 tumor vessels (2+) in 6 cases, more than 3 tumor vessels (3+) in 3 cases, and no tumor vessels in 3 cases. The sensitivity, specificity, accuracy, and positive predictive value with vessel enhancement were about 100%, 66.7%, 77.4%, and 84%. In 17 of GISTs, hypoenhancement was observed in 5 cases, isoenhancement in 11 cases, and hyperenhancement in 1 case. In 8 of non-GISTs, hypoenhancement was observed in 5 cases, isoinhancement in 2 cases, and unenhancement in 1 case. **Conclusion:** The findings of tumor vessel enhancement in CE-EUS is useful for differential diagnosis between GIST and non-GIST in gastric hypoechoic tumor of proper muscle layer. The echo patterns of contrast enhancement were insufficiency for differential diagnosis between GIST and non-GIST.

Keywords: gastric gastrointestinal stromal tumor, contrast-enhanced endoscopic ultrasound, tumor vessels

EE-0353 (PE-0131) Risk factors of recurrent gastrointestinal bleeding from angiodysplasias

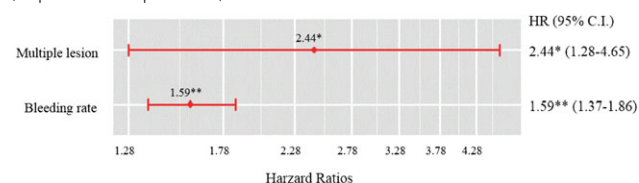
Authors: JUNG MIN MOON; JAEYOUNG CHUN; HYUN JUNG LEE; JONG PIL IM; JOO SUNG KIM

Affiliation: Department of Internal Medicine, Seoul National University Hospital, Seoul, Republic of Korea

Background and Aim: Angiodysplasias account for 5–7% of upper and lower gastrointestinal (GI) bleeding. It remains unclear which patients experienced GI bleeding due to angiodysplasias are at risk of rebleeding. We aimed to investigate the risk factors of recurrent bleeding in GI angiodysplasias. **Methods:** From February 2011 to December 2017, a total of 87 consecutive patients (male, 51.7%; mean age, 72 years old) with a history of GI bleeding because of angiodysplasias which was proven by endoscopic procedures at Seoul National University Hospital were included. Rebleeding was defined as the development of recurrent GI bleeding requiring endoscopy, which was related to GI angiodysplasias. Bleeding rate was defined as the number of overt GI bleeding episodes requiring endoscopic procedures per year, based on the past medical history. **Results:** During a mean follow-up of 21.3 months (range, 0.5–133), rebleeding events related to angiodysplasias occurred in 43 (49.4%) patients. The independent risk factors of rebleeding related to GI angiodysplasias were high bleeding rates (adjusted hazard ratio[HR], 1.57; 95% confidence interval [CI], 1.34–1.84) and more than one angiodysplasia (adjusted HR, 2.57; 95% CI, 1.33–4.95). Endoscopic hemostasis did not prevent rebleedings related to GI angiodysplasias. Among patients who underwent endoscopic hemostasis using argon plasma coagulation (APC), 16 patients experienced rebleeding events within 1 month of the endoscopic hemostasis, and the cause of rebleeding was post-APC ulcers in 9 patients. **Conclusion:** Patients with a past history of high bleeding rates and multiple GI angiodysplasias were at risk of rebleeding related to angiodysplasias.

Keywords: angiodysplasia, rebleeding, risk factor

Figure 1 Independent risk factors of GI rebleeding from angiodysplasias. (*: $p < 0.05$ **: $p < 0.001$)



EP-0067 (PE-0132) A multicenter retrospective study of endoscopic submucosal tunnel dissection for laterally spreading tumors

Authors: XING ZHANG[1]; RUI LI[1]; DONGTAO SHI[1]; WEICHANG CHEN[1]; WEIGANG CHEN[2]; FEIHU BAI[3]; XUDONG WU[4]; CUIE CHENG[1]

Affiliation: [1]Department of Gastroenterology, The First Affiliated Hospital of Soochow University, Suzhou, [2]Department of Gastroenterology, The First Affiliated Hospital of Shihezi University, Shihezi, [3]Department of Gastroenterology, Ningxia Hui Autonomous Region People's Hospital, Yinchuan, and [4]Department of Gastroenterology, Yancheng First Peoples' Hospital, Yancheng, China

Background and Aim: To evaluate the efficacy, safety, and long-term prognosis of endoscopic submucosal tunnel dissection for the treatment of laterally spreading tumors (LSTs). **Methods:** Between June 2013 and June 2017, 108 patients with huge laterally spreading tumors (≥ 3 cm) at five Chinese institutions were enrolled. Of these, 42 underwent ESTD and 66 underwent endoscopic submucosal dissection (ESD). **Results:** ESTD group was associated with a higher dissection speed (15.1 ± 5.1 mm²/min vs 7.0 ± 6.8 mm²/min, $P < 0.01$) and had a higher curative resection rate and en bloc resection rate compared with the ESD group (100% vs 68.2%, $P < 0.01$, 100% vs 80.3%, $P < 0.01$). No perforation occurred in the patients, and the intraoperative bleeding rate and muscular injury rate in ESTD group were lower (47.6% vs 97.0%, $P < 0.01$; 4.8% vs 45.5%, $P < 0.01$). In this study, 100 patients were included in the follow-up (3 were lost to follow-up, 5 underwent additional surgery). The mean follow-up period was 13.7 ± 9.1 months. Recurrence was found in 3 patients in the ESD group and no recurrence occurred in the ESTD group. **Conclusion:** Outcomes of ESTD were excellent with a higher dissection speed and radical curative rate compared with ESD.

Keywords: endoscopic submucosal tunnel dissection, ESD, LSTs, dissection speed

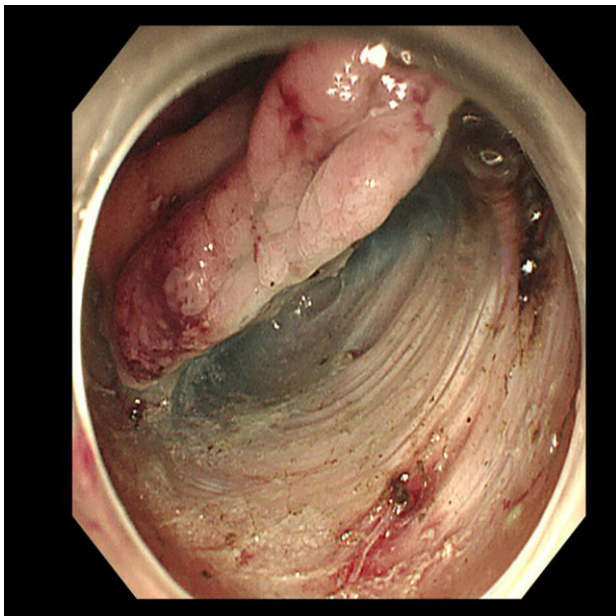


Figure 1 A submucosal tunnel was created.

EP-0068 (PE-0133) Clinical research in the endoscopic management of digestive fistula

Authors: XING ZHANG[1]; SHUCHENG ZHOU[2]; DONGTAO SHI[1]; DEQING ZHANG[1]; RUI LI[1]; WEICHANG CHEN[1]

Affiliation: [1]Department of Gastroenterology, The First Affiliated Hospital of Soochow University, Suzhou, and [2]Department of Emergency, Yancheng Third Peoples' Hospital, Yancheng, China

Background and Aim: Gastrointestinal fistulae can be serious complication or chronic morbid condition resulting from inflammatory and it is associated with a high rate of mortality (80%). Traditional treatments such as surgery, stent placement, and endoscopic suturing are not sufficient to treat the sickness. With the development of endoscopic technology, lots of digestive disease such as bleeding, perforation, and tumor can be treated effectively. How to manage digestive fistulas by endoscopic technologies is a focal point. To evaluate the efficacy and outcomes of endoscopic treatment for digestive fistula and choose suitable endoscopic methods for different fistulas. **Methods:** From July 2015 to July 2017, totally 38 endoscopic treatments for digestive fistulas were gathered. Choose suitable treatments according to the size and the site of the fistulas. The methods including endoscopic clipping, OTSC, and endoscopic jejunal tube placement. **Results:** Totally 38 fistulas were treated endoscopically. Jejunal tube was placed in 13 fistulas, OTSC in 5 fistulas, and endoscopic clipping in 20. All patients completed the endoscopic operation successfully with no significant complication. OTSC group total efficiency is 100%, the postoperative hospital stay is 5.2 ± 1.7 days. In jejunal tube group, one patient died from function failure of organ failure because of infection. Four fistulas fully healed, 3 narrowed, its efficiency is 30.8%, and the postoperative hospital stay is 47.4 ± 14.1 days. For endoscopic clipping group, one patient died from septic shock. In the remaining 19, the total efficiency is 80% and the postoperative hospital stay is 17.9 ± 8.9 days. **Conclusion:** Endoscopic jejunal tube placement as an adjunctive therapy can effectively improve the prognosis when combined to other methods. For small < 1 cm and no anabrotic fistulas, endoscopic clipping can be a suitable method to close the fistula. For big or obviously anabrotic lesions, OTSC may be the best choice.

Keywords: prostate, magnetic resonance imaging, observer variation, methodology

EP-0123 (PE-0134) Peroral endoscopic myotomy for treatment of achalasia in a Philippine tertiary hospital

Authors: ENRIK JOHN TORRES AGUILA; JONARD CO; MARIE ANTOINETTE LONTOK; ARSENIO CABURNAY
Affiliation: Department of Institute of Digestive and Liver Diseases, St. Luke's Medical Center Global City, Taguig City, Philippines

Background and Aim: Achalasia is an uncommon motility disorder characterized by absence of peristalsis of the esophageal body and incomplete lower esophageal sphincter relaxation when swallowing. Treatment is not curative but aims to relieve patient symptoms. Treatment modalities include pharmacologic therapy, pneumatic dilation, laparoscopic Heller myotomy, and recently, peroral endoscopic myotomy. This case series describes one of the first cases of achalasia who were treated with POEM in the Philippines done at St. Luke's Medical Center Global City, a tertiary hospital. **Methods:** This case series reviews two patients diagnosed with achalasia. The first case is based on a 46-year-old male diagnosed to have hypereosinophilia and achalasia who underwent pneumatic dilatation twice prior but presents with recurrent dysphagia. The second case is based on a 48-year-old female who presented with dysphagia for 3 years associated with occasional epigastric pain and night awakenings. Previous gastroscopy done already showed achalasia. Both patients had unremarkable physical examination. After cleared for the procedure, both underwent POEM. The technique was done by creating a submucosal tunnel dissecting the deep submucosa from the muscularis. **Results:** Both patients tolerated the procedure well. Post-procedure, they had no untoward complications. Both reported resolution of dysphagia on follow-up with marked improvement of quality of life. Repeat gastroscopy done on follow-up at an interval also revealed unremarkable results. **Conclusion:** POEM is a novel technique in the treatment of achalasia which have shown promising results even gaining popularity even in a developing country like the Philippines. Its high success rates make it a favorable therapeutic option. Nevertheless, long-term follow-up for its safety and efficacy is recommended. After POEM, patients should be followed up to assess both symptom relief and esophageal emptying.

Keywords: poem, achalasia

EP-0141 (PE-0135) The safety of endoscopic mucosal biopsies in patients receiving direct oral anticoagulants (DOAC)

Authors: ZAKI ALHASHIMALSAYED; TURKI ALAMEEL
Affiliation: Department of Internal Medicine, King Fahad Specialist Hospital Dammam, Dammam, Saudi Arabia

Background and Aim: Current Asian endoscopic societies guidelines advise against stopping direct oral anticoagulants (DOACs) in low risk endoscopic procedures. This is defined as mucosal biopsies without cutting open the mucosa or breaching the deep layers. However, Western societies such as the British Society of Gastroenterology (BSG) and European Society of Gastrointestinal Endoscopy (ESGE) recommend to omit the morning dose of DOACs on the day of procedure if biopsy is planned. Both guidelines have weak recommendation with low quality evidence. In this study, our aim is to evaluate the safety of endoscopic biopsy in patients who are taking DOACs. **Methods:** This study is a retrospective observational study done at a single institution. It included patients who were taking direct oral anticoagulants (DOACs) and underwent endoscopic procedure with mucosal biopsies at King Fahad Specialist Hospital in Dammam between the period of 2013 to 2017. We retrospectively evaluated patients' electronic records. Significant bleeding was defined as bleeding leading to unplanned emergency department visit, unplanned hospital admission, and/or blood transfusion requirement within 2 weeks of endoscopic mucosal biopsy. Patient taking DOACs at the day of endoscopy has been confirmed by electronic ordering system and pre-endoscopy assessment sheet completed by health-care providers on the day of the procedure. **Results:** Among 65 patients undergoing endoscopic mucosal biopsies who were on DOAC, nine patients received DOAC on the day of procedure. Biopsies were performed for five patients who underwent esophagogastroduodenoscopy, one patient had colonoscopy, and three patients had both procedures. DOAC included rivaroxaban in eight patients and one patient on apixaban. None of these patients required unplanned emergency department visit, unplanned hospital admission, and/or blood transfusion within 2 weeks after the endoscopic mucosal biopsy. **Conclusion:** Endoscopic mucosal biopsy without cessation of direct oral anticoagulants appears to be safe. However, larger volume studies are needed to confirm this.

Keywords: anticoagulation, biopsy, safety

EP-0167 (PE-0136) Intra-gastric balloon therapy in the management of obesity in Vietnam

Authors: THANH NGOC NGUYEN[1]; HUNG NGOC DOAN LUU[2]; LUAT VAN TRUONG[2]; KHIEU VAN VU[1]

Affiliation: [1]Department of GI Endoscopy, 108 Central Hospital, Hanoi City, [2]Department of Internal Medicine-GI/Hepatology, Trieu An Hospital, Ho Chi Minh City, Vietnam

Background and Aim: Since 2008, Vietnam started applying intra-gastric balloon therapy for patients with obesity. This study aims to assess the effectiveness and complications of intra-gastric balloon therapy for obese patients in Vietnam (from 2008 to 2016). **Methods:** Fifty obese patients were treated at Trieu An Hospital, Hochiminh City from 01/007 to 12/2016. The patients received a clinical examination, subclinical, and have indication of gastric balloon placement. We only use a Spatz balloon. The balloon was removed after 6 months of placement, and we evaluated the therapeutic effect of this method. **Results:** *Patient characteristics: 50 patients (34 women and 16 men). Average age: 29.9 ± 9.7 (18–55). Average weight: 94.4 ± 17.8 kg (69–144). Average BMI was 35.6 ± 4.3 (30–48.6). *Technical success rate: 50/50 (100%). Average time to perform the procedure is 15.3 ± 4.7 min (12–18 min). *Effective treatment: The average weight loss after 01 weeks of treatment: 4.9 ± 1.6 kg (2–8 kg). Average weight loss after 6 months of treatment: 19.8 ± 9.3 kg. Six patients had abdominal pain after balloon placement and desired the balloon removed. These 6 cases were admitted to the hospital, followed by the use of antispasmodic (Buscopan) and discharged at the same day. Then, 6 cases were convinced and agreed to put the intra-gastric balloon in place. One case, after 3 months of treatment must take the balloon out. *Complication: After the procedure, the patients had some complications in the first week: mild abdominal pain (96%), bloating (100%), and nausea–vomiting (82%). After 6 months of treatment, no gastroesophageal reflux disease (GERD). **Conclusion:** This study showed that placing the balloon in the stomach effectively reduces weight and reduces BMI. This is a safe, easy-to-accept, and effective method of non-surgical treatment for obese patients in Vietnam.

Keywords: gastroesophageal reflux disease

OE-0314 (PE-0137) Successful closure of huge epiphrenic diverticulum using endoscopic suturing closure: A case report

Authors: XUAN LI; GUOXIN ZHANG

Affiliation: Department of Gastroenterology, The First Affiliated Hospital of Nanjing Medical University, Nanjing, China

Background and Aim: Symptomatic epiphrenic diverticula are mostly treated with laparoscopic diverticulectomy. Our study aimed to demonstrate the safety and efficacy of endoscopic suturing closure for treatment of symptomatic huge epiphrenic diverticula. **Methods:** Data of patients with symptomatic huge epiphrenic diverticula who underwent endoscopic suturing closure at Jiangsu Province Hospital (Jiangsu, China) were retrospectively reviewed. The parameters analyzed were the barium radiograph, the incidence of complications, total procedure time, hospital stay, the number of stitch, and patient satisfaction. **Results:** A 37-year-old woman with epiphrenic diverticula was admitted to our hospital because of heartburn and regurgitation for 2 years. Endoscopy showed a large epiphrenic diverticula near by cardia. Computed tomography (CT) scanning and barium radiograph showed the size of epiphrenic diverticula was 6.0 ± 5.0 cm. Endoscopic suturing closure was performed. The procedure time was 78 min. The number of stitch applied was 5. Barium radiograph showed a few barium was infiltrated into epiphrenic diverticula with supine position after 3-day post-procedure. The hospital stay was 5 days. No complications were observed during the follow-up of 1.5 month, and the patient achieved remission of symptoms. **Conclusion:** Endoscopic suturing closure for treatment of symptomatic huge epiphrenic diverticula is feasible and safe.

Keywords: endoscopic suturing closure, huge epiphrenic diverticula

OE-0370 (PE-0138) Feasible and safe of endoscopic suturing closure of large mucosal defects after endoscopic submucosal dissection

Authors: XUAN LI; GUOXIN ZHANG

Affiliation: Department of Gastroenterology, The First Affiliated Hospital of Nanjing Medical University, Nanjing, China

Background and Aim: Our study aimed to demonstrate the safety and efficacy of endoscopic suturing device for closure of mucosal defects after ESD. **Methods:** Data of patients who underwent endoscopic suturing device for closure of mucosal defects after ESD between November 2017 and January 2018 at Jiangsu Province Hospital in China were retrospectively reviewed. The parameters analyzed were the incidence of complications, total procedure time, closure time, visual analogue scale (VAS), hospital stay, mucosal closure costs, and patient satisfaction. **Results:** A total of 4 patients were enrolled in our study. There were 1 man and 3 women with the mean age of 62.50 ± 14.08 years. The mean size of lesion was 20.2 ± 6.9 mm. One patient was located in the gastric antrum, one was in the corpora while the others were located in the gastric fundus. The mean size of mucosal defects was 41.5 ± 12.5 mm. One patient had the perforation during the ESD. The mean procedure time was 45.42 ± 24.10 min, and the mean closure time was 8.42 ± 4.10 min. The number of stitch applied was only 1 per person. The mean VAS score was 2.57 ± 1.04 . The mean hospital stay was 5.57 ± 0.79 days. No complications were observed during the median follow-up of 4.25 months. **Conclusion:** Endoscopic suturing device is a feasible and safe procedure for closure of mucosal defects after ESD.

Keywords: endoscopic submucosal dissection, endoscopic suturing device

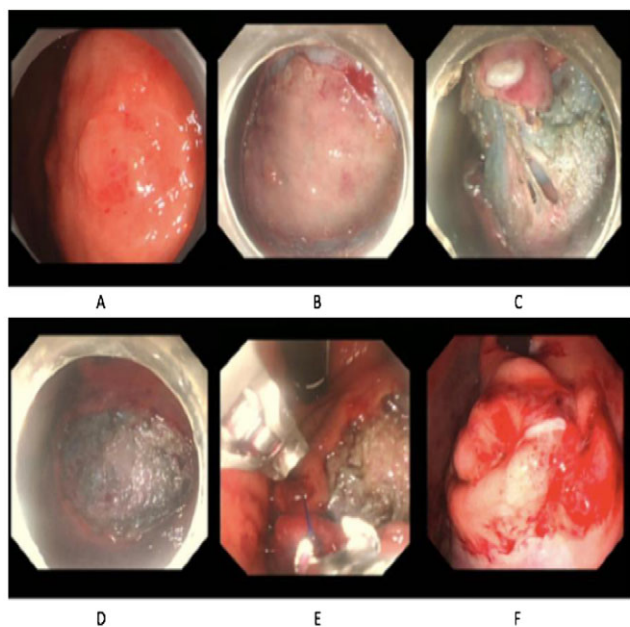


Figure 1 The protocol of this procedure.

OE-0447 (PE-0139) A retrospective analysis of percutaneous endoscopic gastrostomy (PEG) or duodenostomy (PED) in post-gastrectomy patients

Authors: HARUNA NAKAMURA; WONG TOH YOON; KAORI YONEDA; YOHEI KUBOTA; KAZUKI NISHIHARA

Affiliation: Department of Gastroenterology, Hiroshima Kyoritsu Hospital, Hiroshima, Japan

Background and Aim: Percutaneous endoscopic gastrostomy (PEG) is the preferred route for long-term enteral nutrition in dysphagic patients. However, this procedure is difficult to perform in post-gastrectomy patients and in some cases the puncture site may be after the anastomosis, in the duodenum (PED). We report our experience with PEG/PED in post-gastrectomy patients successfully performed at our hospital. **Methods:** Nineteen post-gastrectomy patients (14 men and 5 women) who received PEG for enteral nutrition at our hospital between 2008 and 2018 were included in our study. Baseline characteristics and clinical outcomes were analyzed. **Results:** Mean age was 80.7 ± 7.02 (SD) years old; 13 patients (68%) had cerebrovascular disease, 9 patients (47%) had dementia, and 9 patients (47%) had respiratory diseases as comorbidities contributing to their dysphagia. Twelve patients underwent distal gastrectomy (9 Billroth I procedures and 3 Billroth II procedures), 2 patients received proximal gastrectomy, and 4 had either wedge or central gastrectomy. Except for one patient in which the Introducer technique was used, all patients received their catheter placements using the Push technique. In 4 patients, the catheter was inserted beyond the anastomosis site (PED) while the rest were in the remnant stomach. Postoperatively, 7 patients (37%) developed peristomal infection/leakage, including 3 of the PED patients (60%). Feeding-related aspiration pneumonia was observed in 4 patients (21%) and diarrhea in 3 patients (16%). Average postoperative length of stay in the hospital was 21.5 ± 20.7 days. Three patients (15%) died before discharge and only one within 30 days after the procedure. **Conclusion:** We reported our experience with PEG/PED in 19 post-gastrectomy patients. If successfully performed, PEG can remain a useful procedure for enteral nutrition in these patients. However, we need to be mindful that PED patients may be prone to peristomal complications.

Keywords: PEG, PED, post-gastrectomy

OE-0480 (PE-0140) Disseminated histoplasmosis in an immunocompetent individual diagnosed with gastrointestinal endoscopy: A case report

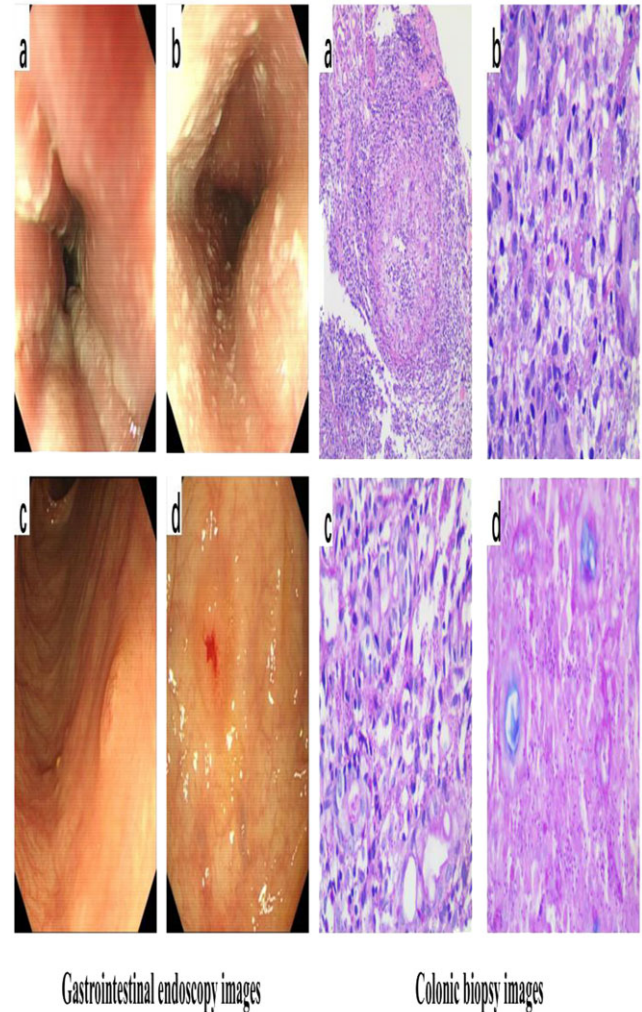
Authors: YINI DANG[1]; LONGFENG JIANG[2]; GUOQIN ZHU[3]; YALI WENG[2]; JUN LI[2]; GUOXIN ZHANG[1]

Affiliation: Departments of [1]Gastroenterology, [2]Infectious Diseases, [3]Geriatric Gastroenterology, The First Affiliated Hospital of Nanjing Medical University, Nanjing, China

Background and Aim: Disseminated histoplasmosis (DH) is rare and the concomitant involvement of liver, spleen, and gastrointestinal tract has never been described in the immunocompetent individuals. Here, we reported a case of disseminated histoplasmosis in the non-endemic area in an immunocompetent patient. **Methods:** A 44-year-old Chinese man admitted to hospital with fever and weakness for 3 months. The patient presented with intermittent high-grade fever with chills and rigor since January 2018. Ultrasonography and CT both revealed hepatosplenomegaly, and bone marrow tests demonstrated hemophagocyte and thrombocytopenia. Since the condition had not improved, he was transferred to our hospital afterwards. His medical history suggested no underlying disease and he denied smoking, alcohol, or illicit drug abuse. Based on the physical examination, the liver was 12 cm below the right rib border and 8 cm below the xiphoid, spleen was 11 cm below the left rib border. **Results:** PET/CT showed that (i) hepatosplenomegaly; (ii) there is 0.8-cm nodule with increased FDG metabolism in the left intestine. Therefore, gastrointestinal endoscopy was performed. Gastroscopy showed fungal esophagitis. Colonoscopy showed protuberant lesions with central depression and erosion along the mucous membrane of the colon. Biopsy specimens indicated histoplasmosis infection. The intravenous amphotericin B deoxycholate treatment was chosen. On the 26th day, a total dose of amphotericin B deoxycholate reached 3000 mg, then it was shifted to oral itraconazole 200 mg bid. **Conclusion:** Disseminated histoplasmosis is an uncommon cause of hepatosplenomegaly in immunocompetent patient. Histoplasmosis should be kept in mind as a possible diagnosis in fever and hepatosplenomegaly patient.

Keywords: disseminated histoplasmosis, endoscopy, esophagus, colon

Figure Endoscopy and colonic biopsy images.



OE-0793 (PE-0141) Long term outcomes, early experience and challenges of establishing endoscopic submucosal dissection (ESD) in a tertiary center in Singapore

Authors: WEI DA CHEW[1]; MANN YIE THIAN[1]; STEPHEN TSAO[1]; YOSHINORI MORITA[2]; TAKASHI TOYONAGA[2]; HIRONORI YAMAMOTO[3]

Affiliations: [1]Department of Gastroenterology and Hepatology, Tan Tock Seng Hospital Singapore, Singapore, Singapore; and [2] Department of Internal Medicine-GI/Hepatology, Kobe University Graduate School Of Medicine, Kobe, and [3]Department of Internal Medicine-GI/Hepatology, Jichi Medical University, Utsunomiya, Japan

Background and Aim: ESD has played an increasingly important role in management of gastrointestinal (GI) lesions since its development in Japan in 1990s. This is a retrospective review of a single's center long-term outcomes of our early experience in ESD. **Methods:** Patients' records from all ESD cases performed in our institution were selected from May 2011 to Dec 2013 with follow up endoscopy were reviewed. All cases were done

by a single endoscopist with the guidance of visiting Japanese experts. **Results:** A total of 22 patients underwent ESD (14 colon, 7 gastric, and 1 esophageal) where the average age was 66.9 years (53–81). The most common site of lesions was rectum (7/14) and incisura (4/7). The mean duration time was 208 min (60–429) and resection velocity was 42 min/cm² for the first 10 cases vs 35 min/cm² for next 11. The en-bloc resection rate was 85.7% (6/7) for gastric and colonic ESD 64.3% (9/14) with time/fibrosis as the limiting factors. The overall complication rate was 9.5% (2/21) with no mortality; 18/22 had a follow up endoscopy post ESD at an average of 207 days (6.5 months). Recurrence at 6 months was (2/4, non-en-bloc) vs (1/14, en-bloc) and the longest follow up is at 5.2 years (no recurrence). **Conclusion:** ESD will play an important role in management of early malignant GI lesion in view of its minimal invasiveness and safety with comparable efficacy in a fast aging population. En bloc, recurrence, and complication rate will improve with case volume, refinement in technique/equipment, and proper patient selection.

Keywords: ESD, long-term outcome

EE-0050 (PE-0144) Per-oral endoscopic myotomy for achalasia: Short-term treatment outcome and adverse events evaluation of a single medical center

Authors: YIN YI CHU; SOH CHING NG; JAU MIN LIEN

Affiliation: Department of Gastroenterology, Chang Gung Memorial Hospital, Taipei, Taiwan

Background and Aim: Achalasia is an uncommon esophageal motility disorder, per-oral endoscopic myotomy (POEM) is a novel modality for the treatment of achalasia. Primary outcome is to evaluate intraoperative and postoperative adverse events. Secondary outcome is to evaluate short-term symptom relief and quantify with Eckardt scores after POEM. **Methods:** Objective testing include esophagogastroduodenoscopy, esophagogram, and manometry study were performed preoperatively and 8 weeks after treatment. A questionnaire was filled out by all patients before and 2nd, 8th week post-POEM. Intraoperative and postoperative adverse events, postoperative numerical rating scale of pain intensity, clinical and endoscopic gastroesophageal reflux disease were recorded. **Results:** There were 31 achalasia patients (male: 15, mean age 39.2 ± 14.7) received POEM, 100% patients had successfully completed the procedure, treatment success (Eckardt score 3) was achieved in all patients, Eckardt score before and after POEM was 7.27 vs 0.52 ($p < 0.001$). Mean resting LES pressure also decreased from 46.8 to 11.7 mmHg on 8th week after POEM. Intraoperative adverse events include capnoperitoneum: 5 (16.1%), subcutaneous emphysema: 3 (9.6%), mucosal perforation: 9 (29%), and capnothorax: 1 (3.2%). Postoperative adverse events include delayed subcutaneous emphysema: 1 (3.2%), fever: 8 (> 38, duration < 72 h, 25.8%). The average of numerical scale of pain intensity was 4.4. On 8th week, there were 7 patients (23%) had symptom of gastroesophageal reflux, EGD examination revealed Los Angeles classification grade A in 10 patients and grade B in 5. **Conclusion:** The success rate of POEM is 100%, all the patients are improvement in clinical symptoms and lower esophageal sphincter pressure. The procedure-related adverse events are conservative manageable, it is a safe and effective treatment, postoperative gastroesophageal reflux is mild. Because of short follow-up period, long-term outcome of POEM's efficacy and symptom recurrence rate should be monitored.

Keywords: achalasia, per-oral endoscopic myotomy

EE-0051 (PE-0145) Evaluation of the role of computed tomography before urgent endoscopy for upper gastrointestinal bleeding

Authors: MANA MATSUOKA; YOHEI FURUMOTO; KATSUMASA KOBAYASHI; TORU ASANO; TAKAO HORIUCHI; KAZUHIKO FUJIKI

Affiliation: Department of Internal medicine, Bokutoh Hospital, Sumida-Ku, Japan

Background and Aim: Rapid identification of the bleeding site is needed for endoscopic hemostasis of gastrointestinal (GI) bleeding. We typically perform computed tomography (CT) in lower GI bleeding for prediction of bleeding sites. However, the effectiveness of CT for upper GI bleeding remains unknown. The aim of this study was to retrospectively evaluate the role of CT before urgent endoscopy for upper GI bleeding. **Methods:** This study included patients who underwent endoscopic hemostasis for upper GI bleeding within 24 h of arrival at Tokyo Metropolitan Bokutoh Hospital. Patients with varix rupture and bleeding after endoscopic treatment were excluded. A predicted bleeding site was defined as thickening or impression in the gastrointestinal wall or extravasation on CT. **Results:** From January 2011 to December 2017, a total of 707 patients (154 men; 65.2 ± 11.5 years old) were included. A total of 457 patients (65%) had gastric ulcers, 127 (18%) had duodenal ulcers, 48 (6.8%) had Mallory–Weiss syndrome, and 73 (10%) had other bleeding sources. Of 144 patients who underwent CT before urgent endoscopy, bleeding sites were predicted in 65 (45%). We compared treatment results in those who were predicted to experience bleeding with results in those who were not predicted to experience bleeding. The respective success rates of endoscopic hemostasis were 94% and 99%; rates of blood transfusion were 64% and 61%. Total procedure times for endoscopic hemostasis were 31.5 ± 18.3 min and 31.5 ± 19.6 min. Time from arrival at the hospital to start of endoscopy was greater in patients who underwent CT than in patients who did not undergo CT (210 ± 172 vs. 159 ± 127 min; $p < 0.01$). **Conclusion:** CT before urgent endoscopy for upper GI bleeding may be helpful in prediction of bleeding sites. Further studies are required to evaluate the role of CT for upper GI bleeding.

Keywords: prediction of bleeding sites, computed tomography, endoscopic hemostasis of gastrointestinal bleeding

EE-0063 (PE-0146) Long-term outcome of noncurative resection cases after endoscopic submucosal dissection for early gastric cancer

Authors: TOMOHIRO OGAWA; AKIO TAMURA; TAKAHISA YAMASAKI; TAKUYA OKUGAWA; TAKASHI KONDO; TOMOAKI KONO; KATSUYUKI TOZAWA; TOSHIHIKO TOMITA; TADAYUKI OSHIMA; HIROKAZU FUKUI; JIRO WATARI; HIROTO MIWA

Affiliation: Department of Internal Medicine, Hyogo College of Medicine, Nishinomiya, Japan

Background and Aim: In Japan, endoscopic submucosal dissection (ESD) is widely performed for early gastric cancer. In the gastric cancer treatment guideline from the Japan Gastroenterological Endoscopy Society and Japanese Gastric Cancer Association, additional surgical resection is recommended when the case is diagnosed as eCuraC after ESD. However, there are cases that are followed up due to various patient's situations such as age and underlying diseases. In this study, we evaluated the patient background and long-term outcome of eCuraC cases in our hospital. **Methods:** From January 2008 to December 2015, 874 patients with early gastric cancer were treated with ESD. Among them, 81 patients who were diagnosed as noncurative resection by pathological diagnosis and had an observation period of 24 months or longer were identified. Clinicopathological findings and long-term outcome were investigated separately for additional surgical resection group and follow up group. **Results:** In 81 patients with noncurative resection, 43 patients underwent additional surgery and 38 patients were followed up without any additional therapies. In additional surgical resection group, the average age was younger than follow up group ($P < 0.001$). The rates of additional surgical resection were significantly higher in the depth with SM2 (500 μ m from muscularis mucosa) of invasion. (69.7% vs 34.2%; $P = 0.004$). However, cancer specific survival rates were not different in both groups. **Conclusion:** These data suggest that follow up is considered as one of the options for elderly patients with noncurative resection.

Keywords: endoscopic submucosal dissection, early gastric cancer, noncurative resection

EE-0086 (PE-0147) Clinical characteristics of multiple metachronous gastric cancers that were endoscopically resected

Authors: IKKO TANAKA[1]; SHOKO ONO[2]; SAYOKO KINOWAKI[1]; MASAKI INOUE[1]; KANA MATSUDA[1]; MARIN ISHIKAWA[2]; MOMOKO TSUDA[2]; KEIKO YAMAMOTO[2]; YUICHI SHIMIZU[2]; NAOYA SAKAMOTO[2]

Affiliation: [1]Department of Internal Medicine-GI/Hepatology, Graduate School of Medicine and Faculty of Medicine, Hokkaido University, and [2]Department of Internal Medicine-GI/Hepatology, Department of Gastroenterology and Hepatology, Hokkaido University Hospital, Sapporo, Japan

Background and Aim: Eradication of *Helicobacter pylori* (*H. pylori*) significantly reduces the occurrence of metachronous gastric cancer (MGC). However, there are some cases of the recurrent multiple MGC despite eradication of *H. pylori*. In this study, we examined the clinical characteristics of multiple MGC that was resected by endoscopic submucosal dissection (ESD). **Methods:** Forty-six early-stage gastric cancers in 11 patients (9 males and 2 females) who received ESD more than three times in the period from January 2003 to April 2018 were reviewed. MGS was defined as a lesion that was not detected previously and was found 1 year or more after last ESD. We classified the cancers into 3 groups (group I: a group of 23 primary cancers, group II: a group of 11 secondary cancers, and group III: a group of 12 tertiary and later cancers). **Results:** The median age of patients with primary gastric cancer was 74.4 years, and all of the patients had severe atrophy. *H. pylori* infection status at the first ESD was as follows: 8 patients were positive for *H. pylori* and 3 patients were negative for *H. pylori* including 2 patients in whom *H. pylori* had been eradicated. The mean durations from primary cancer to secondary cancer and to tertiary and later cancer were 3.5 and 6.3 years, respectively. Lesions that were depressed type in the lower third of the stomach were more frequently in groups II and III. Furthermore, MGC often occurred in the areas near the primary cancers. All of the lesions were intramucosal tubular adenocarcinoma surrounded by intestinal metaplasia. **Conclusion:** Attention should be given to the lower third of the stomach and areas near the primary cancers in follow-up endoscopy after ESD for patients with severe atrophy and intestinal metaplasia.

Keywords: gastric cancer, metachronous gastric cancer, ESD, *Helicobacter pylori*

EE-0134 (PE-0148) The effectiveness of oral Phloroglucin as premedication for non-sedative esophagogastroduodenoscopy: A double-blinded, placebo-controlled, randomized controlled trial

Authors: HYE IN JUNG; YOO JIN LEE; JONG HWAN CHOI; INTAE SO; EUN SUNG CHOI; HYUN JIK LEE; JU YUP LEE; KYUNG SIK PARK; KWANG BUM CHO

Affiliation: Department of Internal Medicine-GI/Hepatology, Keimyung University Dongsan Medical Center, Daegu, Republic of Korea

Background and Aim: Antispasmodic agents are commonly injected before esophagogastroduodenoscopy (EGD) to inhibit gastrointestinal peristalsis. If antispasmodics can be taken orally, that may be convenient in patients who are undergoing non-sedative EGD. This study aimed to evaluate the effectiveness of oral Phloroglucin (Flospan®) as premedication for non-sedative EGD. **Methods:** A prospective, double-blinded, placebo-controlled, randomized controlled trial was conducted at a single tertiary hospital. Subjects who scheduled to undergo non-sedative EGD were randomly assigned to receive oral Phloroglucin (Flospan®) or placebo at 10 min before EGD. The degree of peristaltic movement was evaluated at the beginning and the end of the procedure by independent investigators. We recorded adverse events, taste of drug, willingness to take this premedication at the next examination, and the difficulty of intragastric observation which were assessed by endoscopists who performed the procedure. **Results:** Overall, 140 subjects were included in the study (Phloroglucin 70, placebo 70, age mean \pm SD, 66.31 ± 9.37 , male 47.8%). The degree of peristalsis in Phloroglucin group was significantly lower compared with that of placebo at the beginning of the procedure ($p = 0.02$) and tended to be lower at the end of the procedure, although it did not show statistical significance ($p = 0.064$). The difficulty of intragastric observation was significantly lower in Phloroglucin group compared with placebo at the both time period (beginning of the procedure: $p = 0.002$, end of the procedure: $p = 0.009$). Both groups showed comparable adverse events, taste of the drug, and willingness to take this premedication at the next examination. **Conclusion:** Oral Phloroglucin (Flospan®) significantly suppress gastrointestinal peristalsis during non-sedative EGD compared with placebo. (Clinical trial registration number: NCR03342118)

Keywords: endoscopy, phloroglucin, anti-spasmodics

EE-0157 (PE-0149) Classification of gastric neoplasms using deep convolutional neural networks in endoscopic images

Authors: CHANG SEOK BANG[1]; BUM-JOO CHO[2]; YOUNG JOO YANG[1]; GWANG HO BAIK[1]

Affiliation: Departments of [1]Internal Medicine-GI/Hepatology [2]Ophthalmology, Chuncheon Sacred Heart Hospital, Chuncheon, Republic of Korea

Background and Aim: Visual inspection, detection of the lesion, and differentiation of malignant and benign feature has been one of the key techniques for gastrointestinal endoscopists. Recognition and differentiating ability of medical images using convolutional neural networks (CNNs) has been increasingly adopted in clinical practice. This study aimed to develop a deep learning model automatically classifying gastric neoplasms based on endoscopic images and evaluate its performance. **Methods:** Endoscopic white-light images of pathologically confirmed gastric lesions were collected and classified with 5 categories (advanced gastric cancer, early gastric cancer, low-grade dysplasia, high-grade dysplasia, non-neoplasm). Four CNN models including Inception-v3, VGG-19, Inception-resnet-v2, and ResNet-v2 were constructed using training dataset consisted of 80% of the database, and the classifying performance was evaluated using validation dataset (20% of the database). **Results:** A total of 5,027 images were collected from 1,207 patients. In the five-categorical classification, the accuracy, recall, and precision of the model reached 79%, 80.2%, and 78.8%. In binominal classification of neoplasm vs. non-neoplasms, the accuracy, recall, and precision showed 85%, 91%, and 88%, respectively. The area under the receiver-operating characteristic curve of this model for the prediction of gastric cancer and neoplasm was 0.88 and 0.95, respectively. **Conclusion:** The CNN classifying gastric neoplasms on endoscopic white-light images reached high performance comparable to experienced endoscopists. This algorithm has potential for real-time add on testing for the accurate prediction of gastric lesions.

Keywords: artificial intelligence, endoscopy, neural networks, stomach neoplasms

EE-0161 (PE-0150) Effect of ilaprazole on the healing of endoscopic submucosal dissection-induced gastric ulcer:

Randomized-controlled, multicenter study

Authors: CHANG SEOK BANG[1]; WOON GEON SHIN[2]; SEUNG IN SEO[2]; MIN HO CHOI[3]; HYUN JOO JANG[3]; SE WOO PARK[3]; SEA HYUB KAE[3]; YOUNG JOO YANG[1]; SUK PYO SHIN[1]; GWANG HO BAIK[1]; HAK YANG KIM[2]

Affiliation: [1]Department of Internal Medicine-GI/Hepatology, Chuncheon Sacred Heart Hospital, Chuncheon, [2]Department of Internal Medicine-GI/Hepatology, Kangdong Sacred Heart Hospital, Seoul, and [3]Department of Internal Medicine-GI/Hepatology, Dongtan Sacred Heart Hospital, Dongtan, Republic of Korea

Background and Aim: The optimal treatment regimen or the duration of treatment for an endoscopic submucosal dissection (ESD)-induced gastric ulcer has not been established. The aim of this study was to assess the efficacy of novel proton-pump inhibitor, ilaprazole, for the treatment of ESD-induced gastric ulcer. **Methods:** This was a prospective, open-label, randomized multicenter study. Between June 2015 and March 2018, a total of 176 patients (178 lesions) who underwent ESD for a gastric neoplasm were randomly allocated to receive the oral proton-pump inhibitor ilaprazole 20 mg or rabeprazole 20 mg daily for 8 weeks. The primary outcome was the ulcer healing rate at 4 and 8 weeks. **Results:** A total of 155 (157 lesions) and 154 patients (156 lesions) were included in the modified intention-to-treat (mITT) and per-protocol analyses, respectively. There was no significant difference in the ulcer healing rate (ilaprazole vs. rabeprazole, 97.4% vs. 97.0% $p = 0.78$ at 4 weeks, 100% vs. 100%, $p = 0.95$ at 8 weeks in the mITT analysis) or stage of ulcer (scar stage, 25.6% vs. 17.7%, $p = 0.25$ at 4 weeks, 92.3% vs. 88.6%, $p = 0.59$ at 8 weeks in the mITT analysis) between the treatment groups. The quality of ulcer healing was not significantly different between the 2 groups. No independent predictive factor for higher quality ulcer healing was found in the multivariate analysis. **Conclusion:** According to this trial, ilaprazole and rabeprazole showed no significant difference in the healing of artificial gastric ulcers. Most of the ulcers achieved complete healing within 4 to 8 weeks (ClinicalTrials.gov NCT02638584).

Keywords: gastric ulcer, endoscopic submucosal dissection, ilaprazole, rabeprazole, endoscopy

EE-0167 (PE-0151) Is it more effective to prescribe a proton pump inhibitor separately before a meal for the eradication of *Helicobacter pylori*?

Authors: JAE HYUN KIM; GYU WON LEE; SEUN JA PARK; MOO IN PARK; SUNG EUN KIM; KYOUNGWON JUNG; WON MOON

Affiliation: Department of Internal Medicine-GI/Hepatology, Kosin University Gospel Hospital, Busan, Republic of Korea

Background and Aim: The current standard regimen for treatment of *Helicobacter pylori* (*H. pylori*) is a proton pump inhibitor (PPI), amoxicillin, and clarithromycin. The aim of this study was to determine the effectiveness of prescribing PPIs before a meal separately for treatment of *H. pylori*. **Methods:** Between January 2008 and December 2012, a total of 160 patients who tested positive for rapid urease in our hospital were reviewed retrospectively. We divided these patients into two groups according to the administration method of triple therapy for the eradication of *H. pylori*. One group of people took all three medicines at once after a meal (group A). Another group of people took a PPI before a meal and took amoxicillin and clarithromycin after a meal (group B). After 4 weeks, a ¹³C-urea breath test was performed to validate eradication of *H. pylori*. **Results:** The eradication rate of group A was 72.5% (58/80) and the eradication rate of group B was 75% (60/80). There was no significant difference between the two groups ($p = 0.719$). Some patients in both groups experienced adverse effects. Specifically, four out of 80 patients (5%) in group A and 6 out of 80 patients (7.5%) in group B reported adverse events. There was also no significant difference between the groups in the occurrence of adverse effects ($p = 0.232$). **Conclusion:** To recommend administration of all medicines at once after a meal may be the better prescription, considering the convenience to the patient and improved likelihood of compliance.

Keywords: *Helicobacter pylori*, proton pump inhibitor, prescription

EE-0181 (PE-0152) Endoscopic application of autologous platelet-rich plasma on gastric ulcer after endoscopic submucosal dissection: A pilot study

Authors: JONG HWAN CHOI[1]; YOO JIN LEE[1]; HYUN JIK LEE[1]; EUN SOO KIM[2]; IN TAE SO[1]; HYE IN JUNG[1]; SO YEON LEE[1]; JU YUP LEE[1]; KYUNG SIK PARK[1]; KWANG BUM CHO[1]

Affiliation: [1]Department of Internal Medicine-GI/Hepatology, Keimyung University Dongsan Medical Center, and [2]Department of Internal Medicine-GI/Hepatology, Kyungpook National University Hospital, Daegu, Republic of Korea

Background and Aim: Platelet-rich plasma (PRP) is a concentrate of platelet-rich plasma protein derived from whole blood, centrifuged to remove red blood cells. Although PRP has been shown to promote healing and regeneration in various of tissue, little is known about its effect on gastric ulcer. This study aimed to investigate the efficacy of endoscopic application of autologous PRP on artificial gastric ulcer after endoscopic submucosal dissection (ESD). **Methods:** Prospective randomized placebo-controlled trial was conducted at a single tertiary hospital. Consecutive patients who underwent ESD for gastric neoplasm were randomly assigned to the PRP or control group. Immediately after ESD, prepared autologous PRP or saline was applied to artificial ulcer. The ulcer diameter was measured immediately after ESD, 2nd weeks, and 4th weeks after the procedure using endoscopic ruler. The efficacy of PRP was evaluated based on the ulcer size and the occurrence of post ESD complications between the two groups. **Results:** Overall, twenty patients were enrolled in this pilot study (PRP group 10, control 10, age, mean \pm SD, 61.00 \pm 10.15, male 11). The mean size of long diameter of ulcer immediately after ESD was significantly larger in the PRP group than in the control (51.00 \pm 11.26 vs. 38.50 \pm 8.52, $p = 0.012$). When the changes in ulcer size were compared between the two groups, the mean ulcer size decreased more in the PRP group than in the control group at 2 weeks (1648.20 \pm 1004.66 vs. 851.60 \pm 502.53, $p = 0.043$) and 4 weeks (1898.20 \pm 1021.18, 1096.30 \pm 553.40, $p = 0.047$) after ESD. Post ESD bleeding rate was not different between the groups. No adverse events related to the application of PRP were occurred. **Conclusion:** Endoscopic application of PRP may be effective treatment modality for artificial gastric ulcers after ESD.

Keywords: Platelet-rich plasma, endoscopic submucosal dissection, ulcer healing

EE-0230 (PE-0153) Complications of percutaneous endoscopic and radiologic gastrostomy tube insertion: A KASID (Korean Association for the Study of Intestinal Diseases) study

Authors: SOO-KYUNG PARK[1]; JI YEON KIM[1]; SEONG-JOON KOH[2]; YOO JIN LEE[3]; HYUN JOO JANG[4]; SOO JUNG PARK[1]

Affiliation: [1]Department of Internal Medicine and Institute of Gastroenterology, Severance Hospital, Yonsei University College of Medicine, [2]Department of Internal Medicine-GI/Hepatology, Seoul National University Boramae Medical Center, Seoul, [3]Department of Internal Medicine-GI/Hepatology, Keimyung University Dongsan Medical Center, Daegu, and [4]Department of Internal Medicine-GI/Hepatology, Dongtan Sacred Heart Hospital, Hwaseong-si, Republic of Korea

Background and Aim: This study aimed to investigate the indications and complications of both percutaneous endoscopic gastrostomy (PEG) and percutaneous radiological gastrostomy (PRG). **Methods:** This was a retrospective multicenter cohort study. Patients who underwent initial PEG or PRG tube insertion for nutritional purpose between January 2010 and December 2015 at five university hospitals were included in the study. We analyzed the indications and all complications related to gastrostomy, which were divided into the major (systemic or life-threatening) and minor (local and non-life-threatening) categories. **Results:** A total of 418 patients who underwent PEG ($n = 324$) and PRG ($n = 94$) were reviewed. The indications for gastrostomy tube insertion were different and included mainly neurological disease ($n = 240$, 74.1%) such as cerebrovascular accident in the PEG group ($n = 119$, 36.7%) and mainly surgical disease ($n = 28$, 29.8%) such as head and neck cancer ($n = 16$, 17.0%) in the PRG group ($p = 0.05$). There were no differences in the minor (16.4% vs. 19.1%, $p = 0.52$) and major (12.3% vs. 14.9%, $p = 0.51$) complication rates between the PEG and PRG groups. The risk factors for complications were age (yearly increments; odds ratio [OR] 1.03, 95% confidence interval [CI] 1.01–1.06), tube diameter (1-Fr increments; OR 1.26, 95% CI 1.01–1.58), insertion time (1-min increments; OR 1.07, 95% CI 1.01–1.13), and neurological disease as the gastrostomy indication (vs. surgical disease; OR 4.61 95% CI 1.47–14.42). **Conclusion:** In our study, both PEG and PRG provided a safe route for nutrition delivery despite their different indications. Our data suggest that PEG might be the procedure of choice for patients with medical or neurological disease and PRG for patients with surgical disease in whom PEG is technically difficult or contraindicated.

Keywords: percutaneous endoscopic gastrostomy, percutaneous radiological gastrostomy, nutrition

EE-0255 (PE-0154) Efficacy of endoscopic size measurements of signet ring cell early gastric cancer

Authors: JU SEOK KIM; SUN HYUNG KANG; HEE SEOK MOON; JAE KYU SUNG; HYUN YONG JEONG
Affiliation: Department of Internal Medicine-GI/Hepatology, Chungnam National University Hospital, Daejeon, Republic of Korea

Background and Aim: Indications for endoscopic submucosal dissection (ESD) of early gastric cancer (EGC) are expanding, but signet ring cell (SRC) carcinoma is still unclear because of its unclear boundaries. The purpose of this study was to compare pathologic size and endoscopic size in SRC type EGC and to find risk factors associated with tumor size underestimation. **Methods:** A retrospectively medical records reviewed of total 137 patients with diagnosed SRC type EGC between January 2009 and December 2016 at our tertiary hospital. According to pathologic and endoscopic tumor sizes, classified into correct estimation, underestimation, and overestimation groups, and risk factors related to underestimation were analyzed. **Results:** Among 137 patients with SRC type EGC, 77 patients (56.2%) had undergone correct estimation, 43 patients (31.4%) had underestimation, and 17 patients (12.4%) had overestimation. Mean pathologic size (SD) was 20.1 (13.8) mm and mean endoscopic size (SD) was 17.9 (10.1) mm, the correlation coefficients were 0.919 ($P = 0.000$), and there was no significant difference between the two groups. Multivariate analysis showed that more than 20-mm tumor size (OR, 3.419; 95% CI, 1.271–9.194, $P = 0.015$) and atrophy (OR, 6.011; 95% CI, 2.311–15.633, $P = 0.001$) was a risk factor for tumor size underestimation. **Conclusion:** There was no significant difference in pathologic and endoscopic size in SRC type EGC. Therefore, ESD may be considered as a therapeutic option if the size of the tumor is less than 20 mm and atrophy is not present in the surrounding mucosa.

Keywords: early gastric cancer, signet ring cell carcinoma, endoscopic submucosal dissection

EE-0270 (PE-0155) Long-term outcomes of early gastric cancer treated with endoscopic submucosal dissection (ESD) in a tertiary centre in Singapore

Authors: MANN YIE THIAN[1]; WEIDA CHEW[1]; YOSHINORI MORITA[2]; HIRONORI YAMAMOTO[3]; STEPHEN TSAO[1]

Affiliations: [1]Department of Gastroenterology and Hepatology, Tan Tock Seng Hospital, Singapore, Singapore; and [2]Department of Gastroenterology, Kobe University Graduate School of Medicine, Kobe, and [3]Department of Gastroenterology, Jichi Medical University, Utsunomiya, Japan

Background and Aim: A retrospective review of a single center's outcome post ESD for treatment of early gastric cancer. **Methods:** Patients' records from all gastric ESD cases performed in our institution were reviewed from May 2011 till March 2015. A total of 14 cases were performed and 5 cases without follow up endoscopy or low grade dysplasia were excluded. **Results:** A total of 9 patients were followed up with endoscopy post ESD for a median duration of 35 months (range 20–61 months). The site of lesions treated were antrum ($n = 4$), incisura ($n = 4$), body of greater curve ($n = 1$) with a median size of 25 mm (range 20–40 mm). En bloc resection rate was 89%. Histopathology results showed 56% (5/9) had high grade dysplasia and 44% (4/9) had adenocarcinoma. The majority of cases had associated intestinal metaplasia changes and 22% had *Helicobacter pylori* which were treated. Among the adenocarcinoma cases, 50% (2/4) had submucosal invasion with one involving resection margins; however, both cases declined surgery. Local recurrence rate was 11% with one recurrence seen at 3 months with adenocarcinoma but declined surgery and with additional ESD treatment had no further recurrence seen endoscopically and on CT imaging at 61 months follow up. No disease specific deaths were noted during the follow up period for the whole cohort. **Conclusion:** Overall, local recurrence rate remains low with good outcome seen at our center.

Keywords: early gastric cancer, endoscopic submucosal dissection

EE-0275 (PE-0156) Comparative efficacy of various anti-ulcer medications for ulcer healing after gastric submucosal dissection: A systematic review and network meta-analysis

Authors: HYUN JOO CHOI[1]; CHAN HYUK PARK[1]; EUN HYE KIM[2]; SE WOO PARK[3]

Affiliation: [1]Department of Internal Medicine-GI/Hepatology, Hanyang University Guri Hospital, Guri, [2]Department of Internal Medicine-GI/Hepatology, Severance Hospital, Seoul, and [3] Department of Internal Medicine-GI/Hepatology, Dongtan Sacred Heart Hospital, Hwaseong, Republic of Korea

Background and Aim: The comprehensive efficacy of various anti-ulcer medications after gastric endoscopic resection has not been fully evaluated. Recently, vonoprazan, a novel potassium-competitive acid blocker, has also been used in ulcer treatment after endoscopic resection. **Methods:** We searched for all relevant randomized controlled trials examining the efficacy of anti-ulcer medications after gastric endoscopic resection, published through October 2017. Healing of iatrogenic ulcers was investigated at 4–8 weeks after the procedure. A network meta-analysis was performed to calculate the network estimates. **Results:** Twenty-three studies with 2137 patients were included in the meta-analysis. Concerning the comparative efficacy for ulcer healing at 4 weeks after the procedure, no network inconsistency was identified (Cochran's Q-test, $df = 12$, $P = 0.22$; $I^2 = 22\%$). A combination therapy of proton pump inhibitor (PPI) and mucoprotective agent was superior to all other regimens (risk ratio [RR] [95% confidence interval, CI]: vs. PPI, 1.69 [1.23–2.31]; vs. vonoprazan, 1.97 [1.09–3.56]; vs. H2 receptor antagonist, 1.73 [1.02–2.93]; vs. mucoprotective agent, 1.68 [1.06–2.65]). Concerning the ulcer healing rate at 8 weeks after the procedure, however, vonoprazan was superior to PPI (RR [95% CI] = 1.27 [1.03–1.56]). Additionally, vonoprazan tended to be superior to the combination therapy of PPI and mucoprotective agent (RR [95% CI] = 1.20 [0.96–1.51]). **Conclusion:** A combination therapy of PPI and mucoprotective agent was superior to other anti-ulcer drug regimens for ulcer healing at 4 weeks after endoscopic resection. However, vonoprazan tended to be superior to the combination therapy of PPI and mucoprotective agent for ulcer healing at 8 weeks after the procedure.

Keywords: endoscopic submucosal dissection, anti-ulcer drug, proton pump inhibitor, vonoprazan, network meta-analysis

EE-0342 (PE-0157) The effect of vonoprazan for endoscopic submucosal dissection-induced ulceration and postoperative bleeding

Authors: NOBUE UEKI[1]; KUMIKO KIRITA[2]; ERIKO KOIZUMI[2]; SHUHEI AGAWA[1]; GO IKEDA[2]; HIROTO NODA[2]; KAZUTOSHI HIGUCHI[2]; TEPPEI AKIMOTO[2]; HIROSHI YAMAWAKI[1]; YASUHIRO KODAKA[1]; OSAMU GOTO[2]; TETSURO KAWAGOE[2]; SEIJI FUTAGAMI[1]; KATSUHIKO IWAKIRI[2]

Affiliation: [1]Department of Gastroenterology, Nippon Medical School Musashikosugi Hospital, Kawasaki, and [2]Department of Internal Medicine-GI/Hepatology, Nippon Medical School Hospital, Tokyo, Japan

Background and Aim: Proton pump inhibitor (PPI) is effective for the treatment of ESD-induced gastric ulcers. Vonoprazan, a potassium-competitive acid blocker (P-CAB), has a strong and continuous inhibition of gastric acid secretion and is expected to improve effectively ESD-induced gastric ulcerations compared to the treatment with PPIs. Therefore, to determine whether vonoprazan can ameliorate more effectively ESD-induced gastric ulcerations and can reduce the incidence of postoperative bleeding more than PPIs, we compared shrinking rate of ulcerations and bleeding incidence in the patients treated with vonoprazan with those treated with PPI. **Methods:** Two hundred thirty-eight patients who underwent gastric ESD between January 2015 and February 2018 were enrolled in Nippon Medical School Hospital. Fourteen patients who were injected triamcinolone into mucosa preventing stricture of the prepylorus and 8 patients with remnant stomach were excluded; 126 patients were treated with P-CAB for 4 weeks (P-CAB group) and 91 patients were treated with PPI (58 esomeprazole and 33 rabeprazole) for 4 weeks (PPI group), and subsequently underwent endoscopy for evaluation of ulcer size and intra gastric pH was measured from samples of gastric juice. **Results:** The shrinking rate of ESD-induced ulcer at 4 weeks after ESD and the post-ESD bleeding incidence were not significantly different between P-CAB and PPI groups ($94.0 \pm 9.1\%$ vs. $94.0 \pm 7.1\%$, 9.5% vs. 6.6% , respectively). The post-ESD bleeding rate in the patients treated with rabeprazole was higher than that in the patients treated with esomeprazole (15.1% vs. 1.7% , $p = 0.0131$). Intra gastric pH at 4 weeks after ESD in the P-CAB group was significantly higher than that in the PPI group (6.9 ± 1.0 vs 6.2 ± 1.8 , $p = 0.0006$). **Conclusion:** Vonoprazan is superior to PPI in acid suppression, but there were no significant differences in ulcer healing between the two groups.

Keywords: vonoprazan, PPI, ESD, post bleeding, ESD-induced gastric ulcer

EE-0360 (PE-0158) Endoscopic outcomes in elderly patients following acute upper GI bleeding: Experience of a tertiary center in Indonesia

Authors: FILBERT RIADY ADLAR[1]; HASAN MAULAHOLA[2]; KEVIN ARISTYO[1]; JANICE TANUMIHARDJA[1]

Affiliation: [1]Faculty of Medicine, Universitas Indonesia, and [2] Department of Internal Medicine-GI/Hepatology, Division of Gastroenterology, Internal Medicine Department, Faculty of Medicine, Universitas Indonesia/cipto Mangunkusumo National General Hospital, Jakarta, Indonesia

Background and Aim: Presently, there is a lack of epidemiological data on elderly patients suffering from acute upper GI bleeding and their following endoscopic outcomes in Indonesia. Patient's age proved to be an essential prognostic factor. However, practical treatment algorithm approach towards elderly patients was not addressed in the current UGIB guideline. This study aims to compare acute UGIB endoscopic outcomes in two age groups (group I < 60 years of age, group II ≥ 60 years of age). **Methods:** Retrospective analysis of treatment outcomes in 105 patients with acute UGIB was performed in Gastrointestinal Endoscopy Center at Cipto Mangunkusumo National General Hospital, Indonesia. Data between 2015 and 2017 were obtained from medical record and electronic health record system. The treatment outcomes were mortality, length of hospital stay, and need for red packed cell transfusion. **Results:** Mortality rate was 16.1% (group I vs. II: 11.1% vs. 23.8%; $P < 0.001$). The mean length of hospital stay was 6.3 days (group I vs. II: 4.1 days vs. 9.7 days; $P < 0.05$). The number of red pack cell transfusion was similar in both groups (group I vs. II: 2.9 units vs. 3.5 units $P = 0.09$). **Conclusion:** This study showed that patients above 60 years of age compared to younger patients have a significant risk of mortality and increased duration of hospitalization due to acute UGIB regardless of both groups' management adherence to the current UGIB management algorithm. This study demonstrated that the standard management is insufficient and extra precaution needs to be taken to tackle this issue.

Keywords: elderly, upper gastrointestinal bleeding, endoscopy, mortality, red cell transfusion

EE-0385 (PE-0159) The effect and safety of peroral endoscopic myotomy in esophagogastric junctional outflow obstruction

Authors: SUN HWA KIM; IN KYUNG YOO; WON HEE KIM; SUNG PYO HONG; JOO YOUNG CHO

Affiliation: Department of Internal Medicine-GI/Hepatology, Bundang CHA, Seongnam, Republic of Korea

Background and Aim: Limited data exist on the use of per oral endoscopic myotomy (POEM) in esophagogastric junctional outflow obstruction (EGJO). This study investigated the outcomes of POEM for patients with EGJO. **Methods:** This was a retrospective study at single center. Consecutive patients who underwent POEM for EGJO, DES, or JE between 11/2011 and 6/2018 were included. Rates of technical success, clinical response, and adverse events were analyzed. **Results:** Among 208 patients who underwent POEM, 25 patients were diagnosed as EGJO. Technical success was achieved in all patients with a mean procedural time of 59.9 ± 25.7 min. The mean myotomy length was 9.6 ± 2.7 cm. Eckardt score was decreased after POEM (6.5 vs 1.4). Chest pain significantly improved for 16 out of all patients. No serious complications related to POEM were encountered. **Conclusion:** POEM is effective and safe in the management of esophagogastric junction outflow obstruction.

Keywords: per oral endoscopic myotomy, esophagogastric junctional outflow obstruction, clinical outcome

EE-0394 (PE-0160) Factors affecting delayed mucosal healing in artificial ulcer after endoscopic submucosal dissection for gastric neoplasms**Authors:** CHOONG-KYUN NOH; BYOUNG HOON MIN; JI WON YANG; AH REUM KIM; SUNG JAE SHIN**Affiliation:** Department of Gastroenterology, Ajou University Hospital, Suwon, Republic of Korea

Background and Aim: Artificial ulcers after endoscopic submucosal dissection (ESD) for gastric neoplasm would heal faster than peptic ulcer, usually within 8 weeks. However, sometimes mucosal healing is delayed over the period. This retrospective study aimed to determine risk factors associated with delayed artificial-ulcer healing after ESD. **Methods:** We retrospectively reviewed medical records of 2,660 patients who underwent ESD for gastric adenoma/early gastric cancer from February 2005 to February 2015. We checked the healing status of post ESD-induced ulcer at 3-month follow-up endoscopy and analyzed variable factors related to a delayed ulcer after ESD. **Results:** Of 2,660 cases, 87 cases had delayed ulcer healing in 3-month follow-up endoscopy after ESD. Multivariate analysis showed that age (≥ 65 years old, OR 1.686; 95% CI 1.071–8.008, $p = 0.024$), specimen size (≥ 6 cm, OR 2.253; 95% CI 1.137–4.464, $p = 0.020$), early delayed bleeding (< 2 days, OR 6.166; 95% CI 2.541–15.123, $p = 0.001$) and anticoagulants/antiplatelet agents (OR 2.121; 95% CI 1.174–3.833, $p = 0.013$) were significantly related to the risk of delayed healing of ESD-induced ulcer. **Conclusion:** In more than 65 years old individuals who had the specimen more 6 cm, early delayed bleeding after ESD and used anticoagulants/antiplatelet agent, ESD-induced iatrogenic ulcers tend to delay ulcer healing. In these cases, it's beneficial to intensify anti-ulcer medications or increase the dosage of PPI.

Keywords: endoscopic submucosal dissection, gastric neoplasm, delayed ulcer healing, risk factors**EE-0397 (PE-0161) Efficacy of endoscopic vacuum assisted closure treatment for post-gastrectomy anastomotic leakage****Authors:** SOO IN CHOI; JUN CHUL PARK; JEUNG EUN LEE; EUN HYE KIM; SUNG KWAN SHIN; SANG KIL LEE; YONG CHAN LEE**Affiliation:** Department of Internal Medicine-GI/Hepatology, Severance Hospital, Seoul, Republic of Korea

Background and Aim: Endoscopic vacuum assisted closure (EVAC) has been attempted as a new non-surgical therapeutic option for anastomotic leakage, replacing previous self-expanding metal stents (SEMS). There were some reports of EVAC therapy for post-esophagectomy anastomotic leakage. We reviewed the clinical outcomes of EVAC therapy and compared the efficacy of EVAC with SEMS in post-gastrectomy leakage. **Methods:** Between Jan 2007 and Feb 2018, total 39 cases of anastomotic leak occurred after gastrectomy for gastric cancer; 28 patients were treated with SEMS, 7 patients were treated with EVAC after SEMS failure, and 4 patients were treated with EVAC only. We reviewed clinical characteristics and outcomes of these patients retrospectively. **Results:** Median follow up duration of EVAC and SEMS were 11 months (range, 5–24) and 19.5 months (range, 0–48). All cases of EVAC therapy were healing successfully and one case of anastomotic stenosis occurred within 1 year. By comparison, two cases of healing failure and six cases of anastomotic stenosis occurred after SEMS therapy. Median therapeutic duration of EVAC (15 days [range 6–47]) was shorter than SEMS (36 days [range 7–108]). Larger size leakage was treated successfully with EVAC (median 2.1 cm [range 1.5–3.3]) than SEMS (median 1.0 cm [range 0.2–2.5]). Median weight change before and after therapy was similar in EVAC (–8 kg [range –15 to 3]) and in SEMS (–9 kg [range –20 to –2]). **Conclusion:** EVAC can be the effective endoscopic therapeutic option for anastomotic leakage after gastrectomy. Further large number randomized controlled trials are needed to define efficacy and benefit of EVAC.

Keywords: anastomotic leakage, endoscopic vacuum assisted closure, gastrectomy

EP-0128 (PE-0162) Clinical outcomes of endoscopic resection for gastric compared between proximal gastrectomy and distal gastrectomy

Authors: MIN HO JANG; YOUNG SOO PARK; YANG JIN KIM; HYUK YOON; CHEOL MIN SHIN; NA YOUNG KIM; DONG HO LEE

Affiliation: Department of Internal Medicine-GI/Hepatology, Seoul National University Bundang Hospital, Seongnam-Si, Republic of Korea

Background and Aim: Endoscopic submucosal dissection (ESD) or endoscopic mucosal resection (EMR) in remnant stomach is technically difficult procedure. The aim of this study was to assess clinical outcomes of ESD or EMR in remnant stomach. **Methods:** Cases in which ESD or EMR were performed in remnant stomach between June 2006 and June 2018 were retrospectively reviewed and clinical outcomes were evaluated. **Results:** ESD was performed in 23 lesions in 23 patients (male: 91%, mean age: 69 years old) after proximal gastrectomy (5/23), distal gastrectomy (14/23), gastric wedge resection (3/23), and pylorus preserving gastrectomy (1/23). EMR was performed in 20 lesions in 19 patients (male: 77%, mean age: 65 years old) after proximal gastrectomy (2/20), distal gastrectomy (16/20), and gastric wedge resection (2/20). En-bloc resection rate of ESD and EMR after proximal gastrectomy and gastric wedge resection were 100%. However, en-bloc resection rate of ESD and EMR after distal gastrectomy was 92% (13/14) and 81% (13/16), respectively. Procedure duration which ESD after proximal gastrectomy (1 case) involving anastomosis site was 58 min (mean 31 min), ESD after distal gastrectomy (2 cases) involving anastomosis site was 54 min, 20 min (mean 42.3 min), respectively. EMR after distal gastrectomy involving anastomosis site was 69 min (mean 34.7 min). ESD which was performed for lesion involving anastomosis site after pylorus preserving gastrectomy failed. There was only one microperforation during ESD after distal gastrectomy. Recurrence was found only in EMR cases after distal gastrectomy (4/16, 25%). **Conclusion:** ESD or EMR after proximal gastrectomy is technically easier than procedures after distal gastrectomy and require sufficient experience.

Keywords: endoscopic submucosal dissection, endoscopic mucosal resection, proximal gastrectomy, distal gastrectomy, remnant stomach

OE-0024 (PE-0163) Gastric xanthelasma may be an independent endoscopic warning sign of intestinal metaplasia: A single-center retrospective case-controlled study

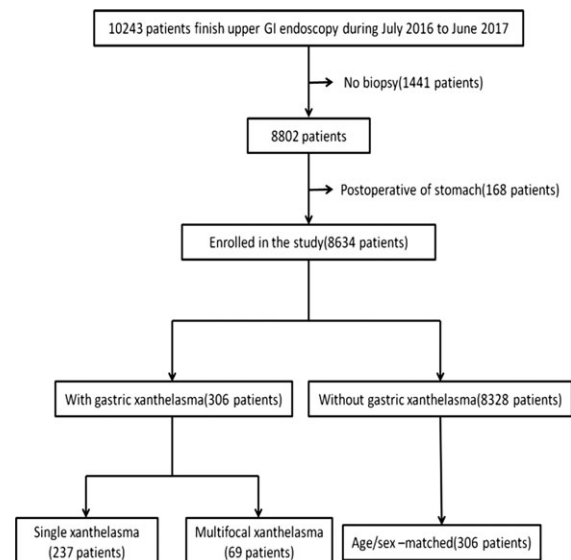
Authors: DINGHONG XIAO[1]; XIAOQIN YUAN[2]; YUNLIN WU[2]; XIN TONG[1]; PING CHEN[2]

Affiliation: [1]Department of Internal Medicine-GI/Hepatology, Jiading Hospital of Traditional Chinese Medicine, and [2]Department of Internal Medicine-GI/Hepatology, Ruijin Hospital North, Shanghai Jiaotong University School of Medicine, Shanghai, China

Background and Aim: Gastric xanthelasma is characterized by presence of lipid islands in the gastric mucosa, and infiltration of lamina propria with foamy macrophages under the microscope. The prevalence of gastric xanthelasma was 0.018–7.7%. Some clinical investigations showed that gastric xanthelasma was related to *H. pylori*, atrophic gastritis and intestinal metaplasia, early gastric cancer. But there were some contrary conclusions. We investigated whether gastric xanthelasma is related with *H. pylori*, atrophic gastritis, intestinal metaplasia, and early gastric cancer. **Methods:** A single-center retrospective case-controlled study was finished; 8,634 patients were enrolled in the study. The relationship between gastric xanthelasma and several endoscopic or pathological features was analyzed. **Results:** Of 8,634 patients, 3.54% patients had xanthelasma. Gastric xanthelasma was significantly associated with age (55.76 years vs. 49.17 years, $P < 0.0001$), duodenal ulcer (OR 0.860, 95% CI 0.369–0.923), atrophy (OR 1.839, 95% CI 1.432–2.362), and intestinal metaplasia (OR 3.296, 95% CI 2.612–4.159). Binary logistic analysis showed that age (OR 1.027, 95% CI 1.017–1.037) and intestinal metaplasia (OR 2.700, 95% CI 2.090–3.487) were independent related to gastric xanthelasma. Age/sex matched control binary logistic analysis demonstrated that gastric xanthelasma was significantly associated with present of intestinal metaplasia (OR 2.338, 95% CI 1.659–3.297). Number ($P = 0.427$) and location ($P > 0.05$) of gastric xanthelasma had no difference for intestinal metaplasia. **Conclusion:** Gastric xanthelasma may be an independent endoscopic warning sign of intestinal metaplasia.

Keywords: gastric xanthelasma, intestinal metaplasia, atrophy

Flow chart of the study



OE-0121 (PE-0164) Magnifying endoscopy with narrow-band imaging in estimating the invasion depth of superficial esophageal squamous cell carcinomas

Authors: TORU HIYAMA[1]; TAKESHI MIZUMOTO[2]; YOJI SANOMURA[3]; YUJI URABE[4]; SHIRO OKA[2]; KOJI ARIHIRO[5]; SHINJI TANAKA[3]; KAZUAKI CHAYAMA[2]

Affiliation: [1]Department of Health Service Center, Hiroshima University, and Departments of [2]Gastroenterology and Metabolism, [3]Endoscopy, [4]Regeneration and Medicine, Medical Center for Translational and Clinical Research, [5]Anatomical Pathology, Hiroshima University Hospital, Hiroshima, Japan

Background and Aim: Intrapapillary capillary loops (IPCLs) of the esophagus are microvessels arising perpendicularly from smooth branching vessels in the squamous subepithelium that can be observed under magnifying endoscopy with narrow-band imaging (ME-NBI). IPCL changes play an important role in the evaluation of esophageal lesions. The aim of this study was to compare the accuracy of ME-NBI for the diagnosis of depth of invasion of superficial esophageal squamous cell carcinomas (SESCCs) by Japan Esophageal Society's (JES) IPCL classification and to examine interobserver and intraobserver agreement of JES's IPCL classification. **Methods:** It was a retrospective observational study that has analyzed 136 patients with esophageal neoplasia with ME-NBI to compare JES's IPCL classification to the histopathologic findings and to evaluate the interobserver and intraobserver agreement. **Results:** Histopathologic examinations revealed 34 (25.7%) intraepithelial neoplasias (IENs), 70 (51.5%) SCCs in the epithelium or with invasion into the lamina propria mucosa (EP/LPM), 21 (15.4%) SCCs with invasion into the muscularis mucosa or scanty ($\leq 200 \mu\text{m}$) invasion into the submucosa (MM/SM1), and 11 (8.1%) SCCs with moderate or deep invasion into the submucosa (SM2/SM3). IPCL Types B1, B2, and B3 also showed high accuracies of 80.8%, 83.1%, and 94.1%, respectively. The kappa values for the interobserver and intraobserver agreements of the IPCL classifications were moderate to almost perfect (kappa value: 0.5036–0.8581). **Conclusion:** In the present study, the JES's IPCL classification has good accuracy to predict the depth of SESCC invasion and moderate to almost perfect intraobserver and interobserver agreements.

Keywords: superficial esophageal squamous cell carcinoma, magnifying endoscopy with narrow-band imaging, Japan esophageal society, intrapapillary capillary loop

OE-0134 (PE-0165) Comparison between redo endoscopic treatment and surgery in patients with locally recurrent gastric neoplasms

Authors: YOUNG KWON CHOI[1]; DO HOON KIM[1]; EUN JEONG GONG[2]; HEE KYONG NA[1]; JI YONG AHN[1]; KEE WOOK JUNG[1]; JEONG HOON LEE[1]; KEE DON CHOI[1]; HO JUNE SONG[1]; HWOON-YONG JUNG[1]; JEONG HWAN YOOK[3]; BYUNG SIK KIM[3]

Affiliation: Departments of [1]Internal Medicine-GI/Hepatology [3]Surgery, Asan Medical Center, Seoul, and [2]Department of Internal Medicine, GangNeung Asan Hospital, GangNeung, Republic of Korea

Background and Aim: Treatment of locally recurrent gastric neoplasms after endoscopic resection remains challenging. We investigated the efficacy and safety of treatment options for recurrent gastric neoplasms localized to the scar of previous endoscopic submucosal dissection (ESD). **Methods:** The clinicopathological characteristics and treatment outcomes of patients who underwent endoscopic treatment or surgery for recurrent gastric neoplasms between June 2010 and May 2017 were retrospectively reviewed. **Results:** Of the 92 patients included, 74 underwent endoscopic treatment (54 redo ESD, 23 argon plasma coagulation [APC] ablation) and 18 underwent surgery. The redo ESD procedure time was significantly longer than that of the primary ESD (31.0 versus 22.0 min, $p = 0.018$). Overall, adverse events occurred in 11 patients (12.0%), with the incidence being significantly higher in the surgery group (27.8% versus 8.1% in the endoscopic treatment group, $p = 0.036$). Local recurrence-free survival rates were 81.1% for the endoscopic treatment group (86.3% and 69.6% for redo ESD and APC groups, respectively) and 100% for the surgery group (log rank $p = 0.033$). Logistic regression analysis showed that tumor size $> 15 \text{ mm}$ (odds ratio [OR]: 7.52, 95% confidence interval [CI]: 1.65–45.3, $p = 0.014$) and tumors located in the upper two thirds of the stomach (OR: 6.10, 95% CI: 1.32–37.1, $p = 0.029$) were associated with non-curative resection after redo ESD. **Conclusion:** Endoscopic treatment could be an effective and safe alternative to surgery for selected patients with gastric neoplasms recurring at the scar of previous ESD.

Keywords: gastric neoplasms, endoscopic submucosal dissection, argon plasma coagulation, gastrectomy

OE-0157 (PE-0166) Usefulness of the thread-traction method for esophageal endoscopic submucosal dissection in ex vivo pig model with ulcer scar

Authors: MITSURU ESAKI[1]; AYA IWAO[1]; YOSUKE MINODA[2]; SEIICHIRO SAKISAKA[3]; YOSHIHIRO OTSUKA[2]; SHINICHI TSURUTA[2]; TAIZO HOSOKAWA[3]; HIROTADA AKIHO[3]; YUDAI TANAKA[1]

Affiliation: [1]Department of Internal Medicine, Nihon University School of Medicine, Tokyo, [2]Department of Internal Medicine, Kyushu University, and [3]Department of Internal Medicine, Kitakyushu Municipal Medical Center, Fukuoka, Japan

Background and Aim: The efficacy of salvage endoscopic submucosal dissection (ESD) for recurrence of esophageal cancer after definitive chemo-radiation therapy has been recently reported. However, ESD for such lesions is considered a technically difficult procedure because of the fibrosis in submucosa. The efficacy of thread-traction method has been reported for esophageal ESD, which may be useful even for ESD of the esophageal lesions with submucosal fibrosis. This study was to clarify the usefulness of the thread-traction method for esophageal ESD in ex vivo pig training model with ulcer scar. **Methods:** This was a pilot study. Four operators conducted a total of 16 esophageal ESD cases. Each operator performed 2 ESD cases with traction (ESD-T) and 2 ESD cases with non-traction (ESD-N). Primary outcome was dissection time of submucosa. Secondary outcomes were the rate of en bloc/complete resection, the rate of perforation during procedure and total amount of injection. **Results:** Median dissection time in ESD-T was significantly shorter than that in ESD-N group (14.5 min vs 19.2 min, $P = 0.040$). En bloc resection was 100% in both groups. Complete resection rate and perforation rate were the same among two groups (Complete resection: 87.5% in both groups, $P = 1$. Perforation: 37.5% in both groups, $P = 1$). Median amount of injection solution in ESD-T was 2.5 mL smaller than that in ESD-N, but not significant (18.0 mL vs 20.5 mL, $P = 0.33$). **Conclusion:** We showed the usefulness of the thread-traction method for esophageal ESD in ex vivo pig training model with ulcer scar. Thread-traction method may be useful for ESD of esophageal cancer with submucosal fibrosis including local recurrence after chemoradiotherapy.

Keywords: endoscopic submucosal dissection, esophageal, traction, ulcer, pig model

OE-0210 (PE-0167) Decision on a treatment strategy in patients with non-curative resection for ESD of early gastric cancer based on the eCura system

Authors: ERIKO KOIZUMI[1]; OSAMU GOTO[1]; HIROTO NODA[1]; KAZUTOSHI HIGUCHI[1]; TEPPEI AKIMOTO[2]; NOBUE UEKI[1]; HIROFUMI KAWAKUBO[3]; NAOHISA YAHAGI[2]; YUKO KITAGAWA[3]; ITSURO FUJITA[4]; KEIICHIRO OTA[4]; MITSURU KAISE[1]; EIJI UCHIDA[4]; KATSUHIKO IWAKIRI[1]

Affiliation: Departments of [1]Gastroenterology, [4]Gastrointestinal and Hepato-Biliary-Pancreatic Surgery, Nippon Medical School, and Departments of [2]Research and Development for Minimally Invasive Treatment, Cancer Center, [3]General and Gastroenterological Surgery, Keio University, Tokyo, Japan

Background and Aim: Additional surgery for non-curative early gastric cancer (EGC) after endoscopic submucosal dissection (ESD) involved two meanings; lymph node dissection for occult metastases and primary site resection for possibly remaining cancer. In terms of lymph node metastasis (LNM), the eCura system was developed to stratify the risk of LNM after ESD that did not meet the curative criteria for EGC (Hatta W et al. Am J Gastroenterol 2017). The aim of this study was to clarify whether the eCura system was useful to predict the potential of LNM and to determine whether additional surgery should be recommended in non-curative EGCs after ESD. **Methods:** Of the 1137 consecutive patients who underwent ESD for EGC from July 2010 to September 2016 at two hospitals, 142 patients who did not meet curative resection of ESD (excluding cases with positive horizontal margins as a single non-curative factor) were initially extracted. Among them, 66 patients who underwent radical surgery were evaluated. The eCura system was applied to them, and we retrospectively investigated existence of LNM at the surgical specimen according to the risk categories by the eCura scoring system. We also investigated a relationship between positive vertical margins and cancer remnant. **Results:** The rates of LNM in each risk category (low: intermediate: high) were 5% (1/20), 8% (2/25), and 38% (8/21), respectively, which significantly increased linearly ($p = 0.0094$). On the other hand, the rate of cancer remnant in cases with positive and negative vertical margin were 38% (8/21) and 9% (12/45), respectively ($p = 0.0571$). **Conclusion:** This study showed the validity of the eCura system for stratifying the potential of LNM. Meanwhile, even in the low-risk group, the risk of cancer remnant is high if it has positive vertical margin. Additional surgery may be taken into account considering non-curative factors after ESD.

Keywords: eCura system, lymph node metastasis, vertical margin, endoscopic submucosal dissection

OE-0255 (PE-0168) Recurrent multiple gastrointestinal stromal tumors presenting as components of incomplete Carney's triad treated with laparoscopic and endoscopic cooperative surgery: A case report

Authors: AKINA OMURA[1]; HIROYUKI TAMAKI[1]; MASAHIRO MORITA[1]; TERUYO NODA[1]; ATSUSHI KUBO[1]; CHIKARA OGAWA[1]; TOSHIHIRO MATSUNAKA[1]; MITSUSHIGE SHIBATOGE[1]; TSUYOSI OTANI[2]; NAOMI KATSUKI[3]; TETSURO OGINO[3]

Affiliation: Departments of [1]Internal Medicine-GI/Hepatology [2]Surgery, [3]Pathology, Takamatsu Red Cross Hospital, Takamatsu, Japan

Background and Aim: Carney's triad is a rare syndrome that involves the coexistence of multifocal pulmonary chondromas, gastrointestinal stromal tumors (GIST), and extra-adrenal paragangliomas. A clinical presentation with 2 of 3 components is called an "incomplete Carney's triad." **Methods:** A 32-year-old woman was diagnosed with an incomplete Carney's triad and underwent an upper and middle lobectomy of the right lung for multifocal pulmonary chondromas and partial gastrectomy for GIST at the age of 25 years. Abdominal computed tomography, upper gastrointestinal endoscopy, and an upper gastrointestinal series revealed 6 gastric submucosal tumors: a 40-mm lesion in the fornix, 2 lesions measuring 20 mm each in the lower gastric body, a 20-mm lesion at the gastric angle, and 2 lesions measuring 10 mm each in the antrum. Endoscopic ultrasonography revealed all lesions to be submucosally located solid tumors showing low echogenicity. Direct-observation biopsy with mucosal cutting revealed all lesions were GIST. **Results:** We performed laparoscopic partial gastrectomy for a 40-mm lesion in the fornix and laparoscopic and endoscopic cooperative surgery (LECS) via en bloc resection for the remaining tumors because the patient refused to undergo total gastrectomy despite the risk of recurrence and gastrointestinal obstruction. Histopathological examination confirmed that all lesions were low-risk GIST (MIB-1 index < 10% (2.7–6.8%), 5 mitosis < /50 high-power fields). Her postoperative course was uneventful, and no gastrointestinal tract dysfunction and recurrence were observed at the 12-week follow-up. **Conclusion:** Although total gastrectomy is usually performed to treat the GIST component of Carney's triad owing to the risk of recurrence, LECS can be an alternative treatment when total gastrectomy is unable to be performed in a few patients (even in those with multiple lesions).

Keywords: Carney's triad, LECS, GIST

OE-0257 (PE-0169) Endoscopic detachable auxiliary manipulator in endoscopic submucosal dissection: Animal model study

Authors: JI HYEONG KIM; SE HYUN JANG; SANG HOON KIM; SEONG JI CHOI; JUNG MIN LEE; SEUNG HAN KIM; JAE MIN LEE; HYUK SOON CHOI; EUN SUN KIM; BORA KIM; YOON TAE JEEN; HOON JAI CHUN; HONG SIK LEE; CHANG DUCK KIM

Affiliation: Department of Internal Medicine-GI/Hepatology, Korea University Anam Hospital, Seoul, Republic of Korea

Background and Aim: Endoscopic submucosal dissection (ESD) is a difficult procedure due to lack of counter traction for unskilled endoscopists. Recently, auxiliary devices have been developed to relieve the difficulties of ESD. We also developed new endoscopic technique using robotic assistant device. The purpose of this study is to evaluate the efficacy and safety of endoscopic detachable assisting device in vitro animal study. **Methods:** A novel robotic manipulator is composed of a control panel and a working arm, which grasp and move objects at the end of scope. A total of 40 porcine stomachs were used for the test. Endoscopists were classified as expert or novice. As a preliminary work, operation time and perforation rate of the experts and novices were recorded when ESD was performed by the conventional method. (C-Expert group, C-Novice group). The same experiment was performed using assistant device (M-Expert group, M-Novice group). During this procedure, robotic manipulator lifts up dissected tissue of stomach to make better visibility. The results were compared. **Results:** The safety of the operation was greatly improved when using the assistant device. Perforation rate of the designed device method was significantly lower than that of the conventional method in the novice group. (10% vs 60%, $P = 0.002$) There was no significant difference between the conventional method and the EDAM in the operation time in the novice group. **Conclusion:** As a result of our in vitro animal study, the endoscopic detachable assisting device significantly improved the safety of ESD in the case of the novice, but there was no change in operation time between conventional method and our new method.

Keywords: endoscopic submucosal dissection, robotic manipulator, efficacy, safety, animal study

OE-0271 (PE-0170) Balloon-assisted endoscopy facilitates endoscopic submucosal dissection of superficial non-ampullary duodenal epithelial tumors and jejunal tumors

Authors: YUJI HIRAOKA[1]; YOSHIMASA MIURA[1]; CHIHIRO IWASHITA[1]; MASATO TSUNODA[1]; YUJI INO[1]; HIROYUKI OSAWA[1]; ALAN K LEFOR[2]; HIRONORI YAMAMOTO[1]

Affiliation: Departments of [1]division of Gastroenterology [2]Surgery, Jichi Medical University, Shimotsuke City, Japan

Background and Aim: Endoscopic submucosal dissection of superficial non-ampullary duodenal epithelial tumors (SNADET) and jejunal tumors is technically challenging. Poor endoscopic maneuverability is one of the main problems in the distal duodenum and jejunum. To overcome this, we performed ESD using balloon-assisted endoscopy (BAE). The aim of this study is to assess outcomes after balloon-assisted endoscopic submucosal dissection (BAESD) in the duodenum and jejunum. **Methods:** We retrospectively reviewed 58 patients who underwent ESD for SNADET and jejunal tumors from October 2006 to September 2017. Nine were performed using BAESD. A short double-balloon endoscope (EC-450BI5 or EI-580BT with 3.2 and 2.8-mm working channels, respectively, Fujifilm, Tokyo, Japan) was used with a BioShield irrigator (US Endoscopy, Ohio, USA) and a small caliber-tip transparent hood (DH-15GR) in all nine cases. We reviewed the location, tumor size, resected specimen size, dissection time, pathological findings, en bloc R0 resection rate, and adverse events. **Results:** The average age was 58 years including five males and four females. One lesion was at the superior duodenal angle and the other eight were in the distal duodenum (3 at the inferior duodenal angle, 4 in the transverse part, and 1 in the jejunum, respectively). A balloon was attached to the tip of the endoscope in two cases. ESD was performed using the pocket-creation method (PCM) in eight cases. The mean diameter of the resected specimens and tumors was 34.0 and 24.4 mm, respectively. The mean procedure time was 119.8 min. The R0 resection rate was 89%. The ratio of adenomas:cancers was 5:4. There were no intraprocedural or delayed perforations. **Conclusion:** BAESD is a safe and reliable method to resect neoplastic lesions in the distal duodenum and jejunum. Endoscopists can perform ESD by ensuring endoscopic maneuverability with safety using the PCM.

Keywords: SNADET, ESD, balloon-assisted endoscopy (BAE)

OE-0282 (PE-0171) Linked color imaging facilitates the detection of synchronous quadruple and quintuple early gastric cancers missed by conventional white light imaging

Authors: TSEVELNOROV KHURELBAATAR[1]; YOSHIMASA MIURA[1]; HIROYUKI OSAWA[1]; TAKAHITO TAKEZAWA[1]; YUJI INO[1]; MASAHIRO OKADA[1]; YASUTOSHI KOBAYASHI[1]; YUICHI SAGARA[1]; MASATO TSUNODA[1]; ALAN KAWARAI LEFOR[2]; HIRONORI YAMAMOTO[1]

Affiliation: Departments of [1]Gastroenterology, [2]Surgery, Jichi Medical University, Shimotsuke City, Japan

Background and Aim: The majority of early gastric cancers (EGCs) are diagnosed because of the presence of an endoscopically identified obvious hyperplastic mass or ulcer. Flat lesions are more likely overlooked by conventional white light imaging (WLI) and diagnosed in advanced stages. **Methods:** We report three patients with synchronous multiple EGCs missed by WLI and diagnosed by linked color imaging (LCI), a new image-enhanced endoscopy technology. A 73-year-old male was referred with a single 3 × 4 cm lesion at the pylorus found at another facility using WLI endoscopy. Detailed endoscopic examination using LCI revealed four more EGCs. An 86-year-old female was referred for endoscopic submucosal dissection of a single EGC in the gastric body, O-IIa measuring 15 mm. Following detailed endoscopic examination using LCI, three more EGCs were found. A 79-year-old male was previously found to have two gastric lesions at another clinic. Detailed precise endoscopic examination using LCI revealed three more small cancers. **Results:** All lesions were dissected en bloc and histological evaluation showed adenocarcinoma. **Conclusion:** LCI differentiates the red color spectrum more effectively than WLI through its optimal preprocess composition of the light spectrum and advanced signal processing. This enhances color contrast, specifically the red color which is adjusted to intensify the visibility of the lesions seen during endoscopy, without magnification. These characteristics make it suitable for improved screening for flat or small lesions in the stomach. Using the accurate color contrast difference, we detected many additional lesions allowing appropriate therapy with preservation of the stomach and most importantly maintaining the patients' quality of life.

Keywords: early gastric cancer, endoscopic diagnosis, synchronous neoplasms, linked color imaging

OE-0317 (PE-0172) The significance of linked color imaging technique in real-time diagnosis of active *Helicobacter pylori* infection

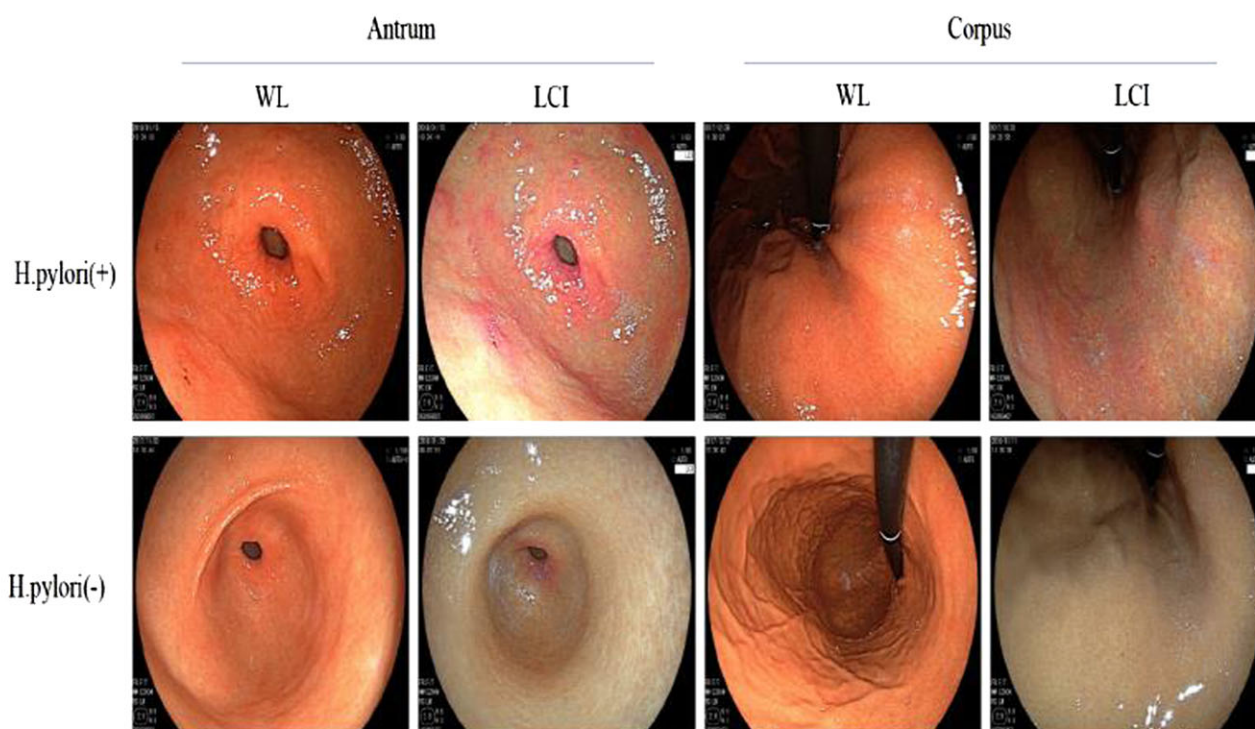
Authors: LI WANG; XIANGCHUN LIN

Affiliation: Department of Internal Medicine-GI/Hepatology, Peking University International Hospital, Beijing, China

Background and Aim: Linked color imaging (LCI) is a novel endoscopic technique. *Helicobacter pylori* (*H. pylori*) positive stomach mucosa shows diffuse redness color compared with negative mucosa that shows light orange color. Our aim was to compare LCI technique with traditional white light (WL) mode in the diagnosis of active *H. pylori* infection. **Methods:** We retrograded analyzed the endoscopic images from 103 patients in our hospital from Nov 2017 to Mar 2018. Images were selected from both antrum and corpus under both LCI and WL mode. All images were labeled with one unique random number and disordered. Four doctors evaluated these images for *H. pylori* state. The results were finally determined by both rapid urease test and pathology staining. **Results:** There were 42 males and 61 females, with medium age 48 (26–82); 388 images were obtained while 24 images were excluded because of poor quality. Twenty-seven patients were *H. pylori* positive. The colors were obviously different between positive and negative mucosa under LCI mode (see Fig. 1). The best results were obtained in corpus LCI group with the sensitivity of 82.76%, specificity 79.71%, positive predictive value 59.42%, negative predictive value 94.02% (see Table 1). We further analyzed the factors that might lead to misjudgment and found that the active inflammation, atrophy and intestinal metaplasia contributed significantly ($P = 0.000, 0.019, 0.003$, respectively). **Conclusion:** LCI mode at corpus was superior than WL mode and antrum site in evaluating *H. pylori* state. Active inflammation, atrophy, and intestinal metaplasia might lead to misjudgment.

Keywords: linked color imaging, *Helicobacter pylori*, real-time diagnosis, active infection state

H. pylori image



OE-0323 (PE-0173) Endoscopic resection for the anxiety level of patients with small gastric GISTs: A randomized prospective research abstract

Authors: MENGYUE JI; DONGTAO SHI; GUOJIAN YIN; JIXIA WU; YUEPING SHEN; DEQING ZHANG; WEICHANG CHEN; RUI LI

Affiliation: Department of Gastroenterology, The First Affiliated Hospital of Soochow University, Suzhou, China

Background and Aim: Gastric GISTs are the most GISTs. Most guidelines recommend small gGISTs without high risks to follow up. However, most patients were anxiety. So we aimed to investigate the influence of endoscopic resection on the anxiety level of patients with small gGISTs. **Methods:** In a randomized prospective clinical research, we compared the degree and the change of anxiety level in patients undergoing endoscopic resection, mind-cure, and non-treatment. Self-Rating Anxiety Scale was used to assess the anxiety of patients at three time points. When gastric GIST was diagnosed, 1 month after treatment/diagnosis and 6 months after treatment/diagnosis, the patients was evaluated; 179 patients completed the research from June 2016 to March 2018. **Results:** In the Endoscopic Resection Group, the S1 was median 57.3 (interquartile range 50–65) and declined to S2: 46.6 (42–50) a month later and S3: median 44.8 (40–50) 6 months later ($P < 0.01$). Similarly, the decline of other two groups were significant either ($P < 0.05$). Educational level, tumor site, and HP infection independently affected the reduction of anxiety. The anxious patients differed significantly from patients not anxious in the aspect of gender, HP infection, family history of gastric cancer, educational level, and diabetes. **Conclusion:** Whether endoscopic resection or mind-cure, or even follow-up only, the anxiety level will decrease significantly; the patients undergoing endoscopic resection showed a more significant decline. Female patients, high educational level patients, patients with diabetes, HP in-

fection, or family history of gastric cancer are more anxious. So individualized treatment is needed.

Keywords: small gastric gastrointestinal stromal tumor, endoscopic resection, mind-cure, anxiety level

Table 1 The comparison of SAS scores

Variable	group1	group2	group3	p value
No of patients	60	60	60	
S1 score	57.3 (40-71)**	54.8 (38-69)*	52.4 (36-69)*	
S2 score	46.6 (37-62)	49.6 (36-71)	50.3 (36-68)	
S3 score	44.8 (35-60)	47.5 (36-62)	48.1 (36-65)	
OS21 [†]	-10.7±7.7	-5.3±4.5	-2.0±3.7	<0.0001 ^a
OS31 [†]	-12.5±7.6	-7.1±4.9	-4.3±4.6	<0.0001 ^a
*Dunnett test p<0.05; **Dunnett test p<0.01.				
[†] OS21, difference S2-S1. OS31, difference S3-S1.				
^a snk t test				
Data are n, median (interquartile range), or mean ± standard deviation.				
Numbers in square brackets indicate the number of missing values.				

OE-0346 (PE-0174) The learning curve for narrow-band imaging in the diagnosis of upper gastrointestinal lesions

Authors: MENGKE FAN; XIAOHUA HOU; HUIYING SHI; RONG LIN

Affiliation: Department of Gastroenterology, Union Hospital, Tongji Medical College, Huazhong University of Science and Technology, Wuhan, China

Background and Aim: Magnifying narrow-band imaging (ME-NBI) is useful for diagnosing of gastrointestinal (GI) diseases. However, the optimal teaching methods have not been developed. Aims to establish an effective training system for GI with ME-NBI. **Methods:** This study was designed as a four-stages in-class teaching training. Fifteen inexperienced endoscopists participated in the training program (ME-NBI basic knowledge—typical cases analysis—hands-on operation/error correction—pathology basic knowledge). Tests were conducted before the training and after each stages. Their diagnoses result were corrected and discussed after each round. Diagnostic accuracy for GI lesions in every stage was analyzed. **Results:** We successfully established an effective training system. The diagnosis accuracy steadily improved with stage I learning for gastric lesions (56.52–90.28%) and ECG differentiation (10.53–75.61%), and significantly improved for esophagus lesions (16.85–76.06%). After II–III–IV stages learning, the diagnosis accuracy significantly improved for gastric lesions (88.64%) and ECG differentiation (72.73%), also for esophageal lesions (90.91%). ME-NBI had higher diagnosis accuracy than WLI (90.91% vs 54.55%, $p < 0.05$). Focused on training methods, case analysis improved fast, followed by pathological teaching, and hands-on operation score significantly improved. Stage I indicated the diagnosis accuracy of m3-SM1 staging SESCC (64.29%) and stomach low-grade intraepithelial neoplasia (33.33%) is poor. Stages II–III showed that WLI alone was poorer than WLI+ME-NBI when diagnosing esophageal lesions; and the diagnosis accuracy for EGC differentiation with ME-NBI was unsatisfactory, significantly improved after error correction. In general, participants were satisfied with our training and the average satisfaction rating was 9.2 ± 1.14 . **Conclusion:** ME-NBI can be easily learned by beginners. We have established an effective training system for GI with ME-NBI. The diagnostic skill of less-experienced endoscopists significantly improved after the training.

Keywords: learning curve, narrow-band imaging, diagnostic accuracy, gastric cancer, esophageal squamous cell carcinoma

OE-0409 (PE-0175) A Durian seed lodged within the esophagus

Authors: YUNN CHENG NG; STEPHEN TSAO

Affiliation: Department of Gastroenterology and Hepatology, Tan Tock Seng Hospital, Singapore, Singapore

Background and Aim: Management of foreign body ingestion and food bolus impaction are common endoscopic challenges. **Methods:** A 68-year-old Chinese male with no known past medical history presented with acute onset dysphagia and vomiting immediately post meals. Esophagogastroduodenoscopy revealed a large durian seed in the lower oesophagus with adjacent ulceration. The rest of the upper gastrointestinal tract was unremarkable. An overtube was inserted for airway protection. Initial attempts to extract the seed from the oesophagus via a roth-net and polypectomy-snare were unsuccessful. The seed was carefully negotiated into the stomach; however, we could not capture it via a roth-net or a polygrab-tripod. Decision was made to postpone the procedure to allow healing of the esophageal ulcer prior to further attempts. Patient was started on oral omeprazole. Further history revealed an accidental ingestion of a durian seed 3 weeks prior to presentation. Esophagogastroduodenoscopy was performed 4 days later under monitored anesthesia care. The esophageal ulcer has healed and the seed was still in the stomach. A reusable lithotripter was used to capture the seed and removed whole via a therapeutic gastroscope. Patient's symptoms of dysphagia and vomiting resolved. **Results:** This case demonstrated both the pushing and extraction technique in successful retrieval of a non-digestible food bolus in the esophagus. **Conclusion:** A prolonged history of food bolus ingestion increases the risk of pressure-induced mucosal surface ulcer and caution should be taken minimize perforation risk. The size and nature of food bolus should be considered when choosing the appropriate equipment for successful and safe extraction.

Keywords: food bolus, esophagus, extraction

OE-0476 (PE-0176) Clinical features of gastric Dieulafoy ulcer

Authors: ERI TSUYUGUCHI; EISUKE NAKAO; SHINSUKE HIRAMATSU

Affiliation: Department of Gastroenterology, Kishiwada Tokushuukai Hospital, Kishiwada, Japan

Background and Aim: Dieulafoy ulcer is defined as a superficial small membrane defect which occurs in the upper part of the stomach. It is a critical emergency disease because of the massive bleeding from thick blood vessels under its mucosa. Recently, a quick diagnosis and treatment has become possible by emergency endoscopy. However, there are still a lot of uncertainty about its clinical features. **Methods:** We enrolled 45 cases diagnosed with gastric Dieulafoy ulcer from November 2010 to June 2018. (33 men and 12 women, with a mean age of 68 years) Comorbidities, medication, location of the ulcer, treatment contents, and rebleeding rate were analyzed. **Results:** The average age was 68. Anti-thrombotic agents and non-steroidal anti-inflammatory drugs were administered to 16 (35.5%) and 7 (15.5%) cases, respectively. Its location was cardia, fornix, upper body, middle body, lower body, and antrum in 4 (8.8%), 4 (8.8%), 13 (28.8%), 9 (20%), 8 (17.7%), and 7 (15.5%) cases, respectively. Forty-two (93.3%) cases were treated with endoscopic coagulation hemostasis. Two cases underwent additional clipping and 2 underwent hypertonic saline-epinephrine together. Two (4.4%) cases experienced rebleeding, but there were no cases bleeding was the direct cause of death. **Conclusion:** Gastric Dieulafoy ulcer occurs not only in the upper part of the stomach. Almost all cases could be managed by endoscopic hemostasis, and the treatment outcome was favorable.

Keywords: Dieulafoy ulcer, stomach, critical emergency disease

OE-0554 (PE-0177) Outcomes following acute upper GI bleeding in relation to time to endoscopy: Experience from single tertiary center in Indonesia

Authors: KEVIN ARISTYO; HASAN MAULAHOLA; FILBERT RIADY ADLAR; JANICE TANUMIHARDJA

Affiliation: Department of Division of Gastroenterology, Department of Internal Medicine, Universitas Indonesia, Cipto Mangunkusumo National General Hospital, Jakarta Barat, Indonesia

Background and Aim: The optimal time for endoscopy in acute upper gastrointestinal bleeding (AUGIB) is unclear. The aim of this study was to evaluate association between the timing of endoscopy and outcomes of patients with AUGIB. **Methods:** Retrospective cohort study performed in Gastrointestinal Endoscopy Center at Cipto Mangunkusumo National General Hospital, Indonesia. Data between 2015 and 2017 were obtained from medical record and electronic health record system. Regression models examined the relationship between time to endoscopy and mortality, need for red cell transfusion, and length of hospital stay. Outcome comparisons were performed for two different urgency times (< 24 h and ≥ 24 h). **Results:** In 105 patients, earlier (< 24 h) endoscopy was not associated with a lower mortality compared with later (≥ 24 h) endoscopy (odds ratio [OR] for mortality 0.93, 95% confidence interval [CI] 0.89–0.94; $P = 0.3$). Later (≥ 24 h) endoscopy was associated with an increase in risk-adjusted of hospital stay (2.2 days longer, 95% CI 1.92–2.14 vs. < 24 h; $P < 0.001$). Earlier (< 24 h) endoscopy were more likely to receive more RBC transfusion than later (≥ 24 h) endoscopy (OR: for red cell transfusion 0.55, 95% CI 0.5–0.6; $P < 0.001$). **Conclusion:** In conclusion, earlier endoscopy for patients with chief complaint of acute upper GI bleeding decreases the length of hospitalization but it does not affect the mortality rate.

Keywords: upper gastrointestinal bleeding, endoscopy, mortality, length of hospital stay, red cell transfusion

OE-0577 (PE-0178) Learning curve for endoscopic submucosal dissection of gastric neoplasia

Authors: SERI RYU; JUN-HYUNG CHO

Affiliation: Department of Internal Medicine-GI/Hepatology, Soon Chun Hyang University Seoul Hospital, Seoul, Republic of Korea

Background and Aim: Endoscopic submucosal dissection (ESD) has been accepted as a standard treatment for early gastric neoplasia. However, number of ESD for achieving the favorable outcome remains undetermined. This study aims to evaluate the learning curve for ESD of gastric neoplasia and factors affecting the procedure time. **Methods:** A total of 243 ESD cases were performed by a single endoscopist. The total ESD cases were divided into three sequential learning phases: phase 1 ($n = 31$), phase 2 ($n = 120$), and phase 3 ($n = 92$). Resection speed was calculated as the area of resected specimen divided by procedure time (cm^2/h). Shorter procedure time was defined when resection speed was over $4 \text{ cm}^2/\text{h}$. Factors affecting a resection speed were analyzed according to age, sex, pathology, tumor size, tumor location, and learning phase. **Results:** The rates of en bloc and complete resection were 90.1% and 81.9%. The mean size of tumor and resected specimen were 18.1 ± 11.2 mm and 35.4 ± 11.7 mm. The mean of procedure time and resection speed were 56.3 ± 44.5 min and $3.7 \pm 1.3 \text{ cm}^2/\text{h}$. The procedure-related complication rate was 9.1% ($n = 22/243$). All post-ESD bleeding ($n = 15$) was treated by endoscopic hemostasis. Gastric perforation ($n = 3$) was treated by endoscopic clips and conservative management. During the phase 3, the mean procedure time was 45.0 ± 41.4 min and mean of resection speed was $4.2 \pm 1.3 \text{ cm}^2/\text{h}$. The factors associated with a faster resection speed was tumor location (middle/lower third of stomach) and phase 3 in multivariate analysis. **Conclusion:** ESD for gastric neoplasms can be performed with faster resection speed after the experience of approximately 150 cases. However, procedure time was significantly longer with lesions located at the upper third of stomach.

Keywords: endoscopic submucosal dissection, learning curve

OE-0596 (PE-0179) Sociodemographic profile of endoscopically managed foreign bodies in the upper gastrointestinal tract: A retrospective study

Authors: MOHAMMAD NAYMUL HASAN;

MD MAKHSUDUL ALAM

Affiliation: Department of Gastroenterology, Shaheed Ziaur Rahman Medical College, Bogra, Bangladesh

Background and Aim: Foreign body ingestion is a relatively common clinical problem in our country. We analyze our clinical data regarding sociodemographic profile in ingestion of foreign bodies of upper gastrointestinal tract in a center of northern Bangladesh. **Methods:** This retrospective study was conducted at Shaheed Ziaur Rahman College and Hospital, Bogura, Bangladesh, over a 2-year period. Patient's social, cultural, and demographic characteristics with endoscopic findings, type of foreign body, and its anatomical location, treatments, and outcomes were analyzed. **Results:** We included 51 patients (male /female: 2.4/1) with foreign bodies in upper gastrointestinal tract. Most of the patients were from rural area (64.71%). Vast majority of patients (about 98.04%) whose educational quality (illiterate 31.37% and primary passed 41.18%) is poor are Muslim. Patients were mostly affected (21.56%) during period of Eid-al-Adha (Islamic festival of sacrifice). Most of them were found in esophagus (94.12%) predominately in lower esophagus (47.92%). Meat bolus (47.06%) and coins (29.41%) were the most common type of foreign bodies in adults and children, respectively. Endoscopic foreign body removal was successful in 98.04% of cases. **Conclusion:** So in conclusion, we found that socioeconomic status and cultural background has a great impact on foreign bodies ingestion. Rural peoples, Muslims, Illiterate persons are more prone to impaction of foreign body. During the period of Islamic festival, people should advise to chew and masticate properly while taking meat bolus. Parents should aware of their children while playing with coins and sharp objects. Finally, endoscopic intervention is simple and safe for removal of foreign bodies from upper gastrointestinal tract.

Keywords: sociodemographic profile, endoscopy, foreign body, upper gastrointestinal tract

OE-0617 (PE-0180) Correlation between gastric mucosal pattern and histopathological *Helicobacter pylori* associated gastritis using narrow band imaging gastroscopy

Authors: SHIRAN SHETTY; SHABEER SHABEER;

GANESH PAI

Affiliation: Department of Gastroenterology and Hepatology, Kasturba Medical College, Udupi, India

Background and Aim: Aim of the study was to find out the correlation of the NBI microvascular findings of the stomach with *H. pylori* infection.

Methods: Forty-five patients scheduled to undergo routine endoscopic examination were enrolled. After conventional endoscopy, stomach was examined with NBI using the Olympus Excera 190 NBI scope and predominant vascular pattern was looked into. Visualized mucosa is classified into 3 patterns. Type 1: slightly enlarged, round pit with unclear or irregular subepithelial capillary networks. Type 2: obviously enlarged, oval or prolonged pit with increased density of irregular vessels. Type 3: well-demarcated, oval or tubulovillous pit with clearly visible coiled or wavy vessels. Subepithelial capillary networks. Biopsy done from the predominant pattern was looked for *H. pylori* infection. **Results:** Three of 20 patients with type 1 pattern was positive for *H. pylori*. Seven of 14 patients with type 3 pattern was positive for *H. pylori* and 6 of 9 patients with type 3 pattern was positive for *H. pylori*. Sensitive, specificity, PPV, and NPV of type 1 pattern for predicting *H. pylori* infection was 15%, 43%, 19%, and 37%, respectively. Sensitivity, specificity, PPV, and NPV for the presence of infection in type 2 pattern was 50%, 68%, 43.5%, and 74%, respectively. For type 3 pattern, it was 66%, 70%, 37%, and 88. **Conclusion:** NBI pattern type2 and type 3 has higher specificity than type 1 in detecting *H. pylori* infection than type 1 pattern. Random biopsies for *H. pylori* can be avoided if type 1 pattern is found on NBI.

Keywords: narrow band imaging, *Helicobacter pylori*

OE-0666 (PE-0181) The different effects between common gastroscopy and painless gastroscopy on endoscopic diagnosis

Authors: HAIFENG JIN; BIN LYU; LIANG HUANG; LINA MENG

Affiliation: Department of GI, GI, Hangzhou, China

Background and Aim: The aim of this study was to determine the effects of common gastroscopy and painless gastroscopy on endoscopic diagnosis. **Methods:** Patients were divided into two group (A: common gastroscopy, $n = 956$; B: painless gastroscopy, $n = 6948$) according to their wishes to receive gastroscopy from Jan. 1, 2015 to Dec.30, 2015, in The First Affiliated Hospital of Zhejiang Chinese Medicine University, performed by the same endoscopic doctors. Those endoscopic diagnosis data were collected; the detection rates of reflux esophagitis chronic, non-atrophic gastritis, chronic atrophic gastritis, gastric ulcer, duodenal ulcer, gastric benign polyps, and early gastric cancer were taken as indexes to assess the differences effects between the two kinds of endoscopy on endoscopic diagnosis. **Results:** (i) The differences of detection rates of chronic non-atrophic gastritis and chronic atrophic gastritis were not significant (57.85%, 33.05% in B group, vs. 58.30%, 36.14% in A group; $P > 0.05$, respectively); (ii) the detection rates of gastric benign polyps and early gastric cancer in B group were higher than those in A group (22.38% and 0.52% in B group, vs. 3.51%, 0.2% in A group; $P < 0.001$, $P < 0.05$, respectively); (iii) the detection rates of reflux esophagitis, gastric ulcer, and duodenal ulcer in B group were lower than in A group (13.81%, 8.58%, and 22.07% in B group, vs. 33.38%, 25.45%, 33.43% in A group; $P < 0.001$, $P < 0.001$, $P < 0.001$, respectively). **Conclusion:** Physicians should pay attention on the different effects of this two gastroscopy on endoscopic diagnosis expect comfort when they make a decision to choose one of them for different patients.

Keywords: endoscopic diagnosis, painless gastroscopy

OE-0681 (PE-0182) Long-term outcomes of endoscopic submucosal dissection for early gastric neoplasms: A single center retrospective study

Authors: RYOICHI MIURA; TOSHIO KUWAI; HIRONA KONISHI; KANAE TAO; YUKI SUMIDA; YUKI MIYASAKO; KAZUTAKA KUROKI; YUZURU TAMARU; ATUSHI YAMAGUTI; HIROTAKA KOUNO; HIROSHI KOHNO

Affiliation: Department of Gastroenterology, National Hospital Organization Kure Medical Center and Chugoku Cancer Center, Kure, Japan

Background and Aim: Endoscopic submucosal dissection (ESD) has been widely accepted for the treatment of early gastric neoplasms (EGN). The aim of our study was to assess the long-term outcomes of EGN after ESD. **Methods:** From June 2007 to December 2012, ESD was carried out for 459 cases (493 lesions) of EGN. Among these cases, the following short- and long-term outcomes were examined in 271 patients (328 lesions) who were reliably followed up for at least 5 years after treatment or death (211 males and 60 females, mean age: 71.1 years, median follow-up period: 76 months, follow-up rate: 59.0%): resection rates, adverse events rates, recurrence rates, and 5-year overall and disease-free survival rates (OS and DSS). **Results:** Among 328 lesions, 69.2% (227/328) were absolute-indication lesions, 17.9% (59/328) were expanded lesions, and 12.8% (42/328) were non-indication lesions. The en block resection rate was 94.5%, the histological complete resection rate was 92.7%, and the curative resection rate was 78.1%. Adverse events such as bleeding after the procedure, perforation, and pyloric stenosis occurred in 4.3% (14/328), 0.6% (2/328), and 0.3% (1/328) cases, respectively. Regarding recurrence rate, local and distant recurrences occurred in four and three cases (1.2 and 0.9%), respectively. Thirty-four patients died, two of whom died because of primary gastric cancer. The overall 5-year OS and DSS rates were 88.7% and 99.3%, respectively. The 5-year OS and DSS rates of absolute-indication lesions, expanded lesions, and non-indication lesions were 90.3% and 100%, 89.8% and 100%, and 78.5% and 93.9%, respectively. **Conclusion:** From the viewpoint of long-term outcomes, ESD appears to be effective for EGN, and absolute-indication and expanded lesions are appropriate gastric cancers for ESD.

Keywords: ESD, EGN, gastric, cancer, treatment

OE-0682 (PE-0183) Effectiveness of a newly designed covered stent without trans-nasal fixation for anastomotic leakage treatment after gastrectomy for gastric cancer

Authors: WON NYOUNG YUN; YOUNG-IL KIM; CHAN GYOO KIM; SOO-JEONG CHO; JONG YEUL LEE; IL JU CHOI; BANG WOOL EOM; HONG MAN YOON; KEUN WON RYU; YOUNG-WOO KIM

Affiliation: Department of Center for Gastric Cancer, National Cancer Center, Goyang, Gyeonggi, Republic of Korea

Background and Aim: A covered self-expandable metal stent using trans-nasal fixation with silk thread was an effective treatment for leakage after total gastrectomy or proximal gastrectomy. However, trans-nasal fixation with silk thread needs long hospital stay and severe discomfort. Recently, Niti-S Beta stent which does not need trans-nasal fixation (Niti-S Beta stent) was developed. This newly designed stent has double layer and double-bump shaped to prevent migration without trans-nasal fixation materials. We investigated the efficacy of Niti-S Beta stent for anastomotic leakage developed after gastrectomy. **Methods:** From January 2014 to March 2018, 23 gastric cancer patients who underwent stent placement for anastomotic leakage after gastrectomy were included. Of the study periods, a stent with trans-nasal fixation was placed in 9 patients until January 2016 (thread-fix group), and thereafter, Niti-S Beta stent was used in 14 patients (Beta stent group). **Results:** Of 23 included patients, 18 patients (78.3%) underwent total gastrectomy and 5 patients (21.7%) underwent proximal gastrectomy. Leakages were completely healed in Beta stent group, but 44% of thread-fix group needed additional endoscopic therapy after stent removal (0% vs. 44.4%, $p=0.014$). The half of Beta stent group discharged before stent removal but none of fixation group (50% vs. 0%; $P = 0.019$). Beta stent group had the tendency of shorter hospitalization days than fixation group (median, 16 days vs. 29 days; $P = 0.186$). The stent maintenance durations were significantly longer in Beta stent group compared to fixation group (median, 28 days vs. 17 days; $P = 0.009$). Stent migration occurred in one case of Beta stent group (7.1% vs. 0%; $P > 0.999$), and the migrated stent repositioned to the leakage site using grasping forceps. **Conclusion:** Insertion of Niti-S Beta stent was an effective treatment for anastomotic leakage in gastric cancer patients underwent total or proximal gastrectomy. Stent maintenance was possible without hospitalization.

Keywords: stent, anastomotic leakage

OE-0776 (PE-0184) Feasibility and long-term efficacy of endoscopic treatment of gastrointestinal stromal tumors in upper gastrointestinal tract

Authors: SOONG GOO JUNG[1]; JONG-JAE PARK[1]; JIN SUNG KOH[1]; MOON KYUNG JOO[1]; BEOM JAE LEE[1]; HOON JAI CHUN[2]; SANG WOO LEE[3]

Affiliation: [1]Department of Internal Medicine-GI/Hepatology, Korea University Guro Hospital, [2]Department of Internal Medicine-GI/Hepatology, Korea University Anam Hospital, Seoul, and [3] Department of Internal Medicine-GI/Hepatology, Korea University Ansan Hospital, Ansan, Republic of Korea

Background and Aim: Endoscopic resection has been introduced for the treatment of subepithelial tumors (SETs) in the upper GI tract (UGIT). We aimed in this study to investigate the feasibility and long-term efficacy of endoscopic resection of gastrointestinal stromal tumor (GIST) in UGIT. **Methods:** Between March 2005 and February 2018, 126 cases of GIST in UGIT were resected. We retrospectively analyzed clinicopathologic parameters and recurrence rate. **Results:** Mean age was 57.6 ± 12.4 years, and male:female ratio was 50:76. Fifty-one tumors (40.5%) were located in the (40.5%) body of the stomach, followed by 34 (27.0%) on fundus, 24 (19.0%) on cardia, and 16 (12.7%) on antrum; 104 cases (82.5%) was resected by endoscopic submucosal dissection (ESD), followed by endoscopic mucosal resection (EMR) in 10 (7.9%), and endoscopic submucosal tunnel dissection (ESTD) in 8 (6.3%). Endoscopic full thickness resection (EFTR) was performed in 3 cases (2.4%). In terms of complication, 8 macroperforation (6.3%), 8 microperforation (6.3%), and 7 major bleeding (5.6%) were noted. According to the NIH classification, 64 patients (50.8%) were corresponding to very low risk, followed by low risk 42 (33.3%), intermediate risk 14 (11.1%), and high risk 6 (4.8%). En bloc resection rate was 72.2% (91/126), and R0 resection rate was 22.2% (28/126). R1 resection rate was 68.3% (86/126) and R2 resection rate was 7.1% (9/126). Among 68 patients who were followed-up longer than 12 months, 2 patients (2.9%) showed recurrence during 31.7 months of follow-up period. **Conclusion:** Endoscopic resection of GIST appears to be a feasible procedure with relatively low rate of recurrence, even low R0 resection rate.

Keywords: endoscopic resection, gastrointestinal stromal tumor, R0 resection

OE-0787 (PE-0185) EVL for an awake esophageal varices patient whose airway was protected by the LMA in the pharynx

Authors: BIH-CHERN LIN; YI-SING SHIH

Affiliation: Department of Anesthesiology, China Medical University Hospital, Taichung, Taiwan

Background and Aim: During gastroscopy under sedation, it is often found that the patient's blood oxygen saturation level decreases, but the treatment is often delayed because there is no prior establishment of a positive pressure breathing airway. To start positive pressure breathing, the provider needs to establish airway before Bag-mask ventilation and delays the time to increase the oxygen saturation level. Although the anesthesiologist can shorten the processing time due to the skillfulness of the treatment, the delay may be up to 2 min. When esophageal varices are ligated, the delay will be longer and there may be higher incidence of hypoxia and hypoxic time will be longer. If the patient is awake during the procedure and a device (laryngeal mask) is already in the pharynx prior to the procedure, it can prevent blood aspiration in case the blood vessels rupture and protect the respiratory tract and the positive pressure ventilation can be started immediately. **Methods:** The patient is 156 cm tall, weighs 56 kg, age 56 years, female, Cirrhosis with esophageal varices. The ligation operation was performed after a size 2.5# OPLAC was inserted into the patient's pharynx awake. **Results:** The examination time was 6 min, and the operation time was 9 min, total procedure time 18 min. A total of 6 bands

were tied (see Video). **Conclusion:** The procedure was completed successfully which caused only minimal discomfort to the patient with save guard to the patient airway by the laryngeal mask in case there was rupture of the varices during the procedure.

Keywords: endoscopic esophageal varices ligation, laryngeal mask, awake, airway protection, hypoxia

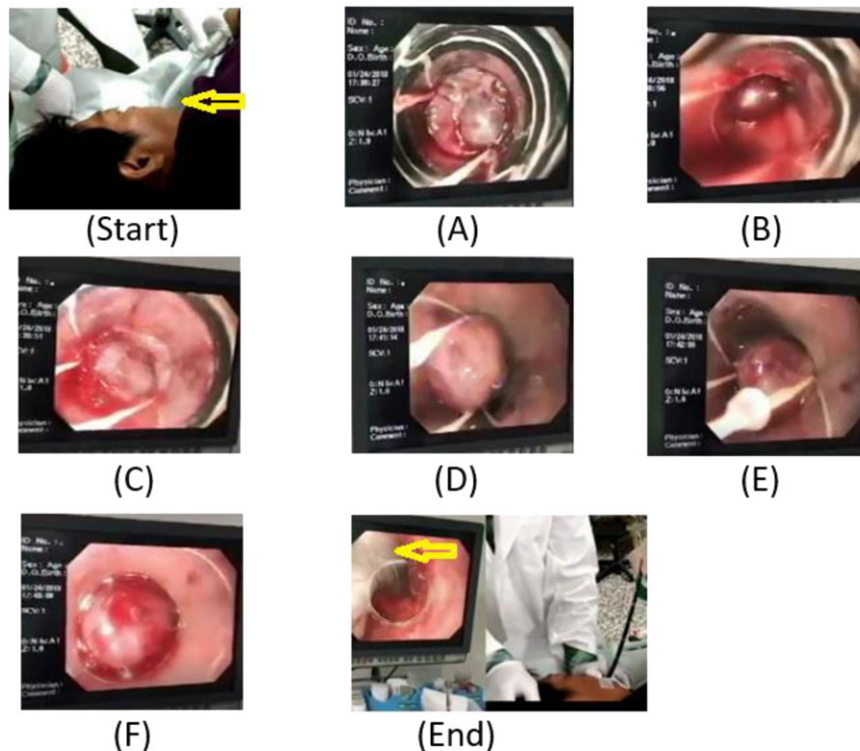
OE-0836 (PE-0186) Effect of antithrombotic therapy on bleeding after argon plasma coagulation for gastric neoplasm


Authors: SEOL SO; JI YONG AHN; HEE KYONG NA; KEE WOOK JUNG; JEONG HOON LEE; DO HOON KIM; KEE DON CHOI; HO JUNE SONG; GIN HYUG LEE; HWOON-YONG JUNG

Affiliation: Department of Internal Medicine-GI/Hepatology, Asan Medical Center, Seoul, Republic of Korea

Background and Aim: Antithrombotic therapy has been known to be relatively safe on post-argon plasma coagulation (APC) bleeding; however, there are few studies proving the effect of antithrombotic agents. This study aimed to analyze the incidence of delayed bleeding (DB) based on anti-thrombotic agents administered and to identify the risk factors of DB in

Video snapshot of the procedure



(Start)Preprocedure airway establishment with laryngeal mask intubation ,(A) is the first round, (B) is the second round, (C) is the third round, (D) is the fourth round, (E) is the fifth round, (F) is the sixth round and (End)End of the procedure extubation.  LMA

gastric APC. **Methods:** Between January 2011 and January 2018, 785 patients with 824 lesions underwent APC for single gastric neoplasm. After exclusion, 719 and 102 lesions were classified as the non-antithrombotics (AT) group and AT group and the clinical outcomes of two groups were compared. We also determined the risk factors of DB in gastric APC. **Results:** The DB of the non-AT and AT groups was found in 17 and 3 cases, respectively (2.4% vs. 2.9%, $p = 0.728$). A thromboembolic event was not observed in all patients taking antithrombotic agents. According to the analysis of the risk factors for DB, univariate analysis revealed significant risk factors: male (OR 8.13, $p = 0.042$), CKD (OR 4.90, $p = 0.003$), tumor in upper third of stomach (OR 3.41, $p = 0.034$), and continued antithrombotic therapy (OR 5.90, $p = 0.026$). Multivariate analysis confirmed significant, independent risk factors: male (OR 7.66, $p = 0.048$) and CKD (OR 4.51, $p = 0.005$). **Conclusion:** Antithrombotic therapy is acceptably safe in gastric APC because of not significantly increasing the incidence of DB. However, the patients with CKD or male need to receive a careful follow-up survey on post-APC bleeding.

Keywords: stomach neoplasm, antithrombotic therapy, argon plasma coagulation

OE-0853 (PE-0187) Diagnostic accuracy and safety of deep biopsy using forceps in patients with submucosal tumors of the upper and lower gastrointestinal tract: A retrospective single-center trial

Authors: NORIKO MATSUURA; NORIYA UEDO; SATOKI SHICHIJO; TAKASHI KANESAKA; AKIRA MAEKAWA; YOJI TAKEUCHI; KOJI HIGASHINO; RYU ISHIHARA

Affiliation: Department of Gastrointestinal Oncology, Osaka International Cancer Institute, Osaka, Japan

Background and Aim: Submucosal tumors (SMTs) include gastrointestinal stromal tumors (GISTs). Histological diagnosis is needed for treatment decision. Endoscopic ultrasound-guided fine needle aspiration biopsy (EUS-FNAB) is a valuable method for obtaining tissue samples. The overall diagnostic accuracy of EUS-FNAB is reported to be 43.3–78.4%. EUS-FNAB requires a specialized endoscope and skills, making it impractical in some hospitals. Deep biopsy using forceps is other way to obtain samples for histology, but the diagnostic yield is reported to be roughly 17% to 38%. Therefore, we investigated the method and usefulness of deep biopsy to obtain a definitive diagnosis. **Methods:** Nineteen patients underwent outpatient biopsies for GI SMTs. First, we exposed the SMT with multiple membrane and submucosal biopsies using disposable forceps (Radial Jaw 4, Boston Scientific Japan). Then, a biopsy forceps was inserted in the mucosal defect. When the SMT was reached, the biopsy forceps was opened and the SMT was grasped to obtain histology. We performed this procedure several times. We closed the mucosal defect after deep biopsy when bleeding that required endoscopic hemostasis during the examination occurred. **Results:** Between January 2017 and June 2018, 19 patients

Table 3 The risk for DB after APC

	Non-DB (n=801)	DB (n=20)	Univariate analysis		Multivariate analysis	
			OR (95% CI)	P value	OR (95% CI)	P value
Sex, n (%)						
Female	240 (30.0)	1 (5.0)	1		1	
Male	561 (70.0)	19 (95.0)	8.13 (1.08–61.1)	0.042	7.66 (1.02–57.69)	0.048
Age, years, mean (SD)	65.2 (9.8)	66.3 (9.5)	1.01 (0.97–1.06)	0.647		
LC, n (%)						
No	785 (98.0)	20 (100.0)	1			
Yes*	16 (2.0)	0 (0.0)	N/A	N/A		
CKD, n (%)						
No	750 (93.6)	15 (75.0)	1		1	
Yes†	51 (6.4)	5 (25.0)	4.90 (1.71–14.02)	0.003	4.51 (1.57–13.02)	0.005
Diagnosis, n (%)						
adenoma or dysplasia	745 (93.0)	17 (85.0)	1			
EGC	56 (7.0)	3 (15.0)	2.35 (0.67–8.25)	0.183		
Tumor size, mm, mean (SD)	9.1 (5.3)	9.9 (2.8)	1.02 (0.96–1.09)	0.505		
Location, n (%)						
Lower third	328 (40.9)	5 (25.0)	1		1	
Middle third	319 (39.8)	7 (35.0)	1.44 (0.45–4.58)	0.537	1.25 (0.38–4.05)	0.714
Upper third	154 (19.2)	8 (40.0)	3.41 (1.10–10.59)	0.034	2.85 (0.88–9.18)	0.080
Antithrombotic therapy, n (%)						
No	702 (87.6)	17 (85.0)	1		1	
Continuation	14 (1.7)	2 (10.0)	5.90 (1.24–28.01)	0.026	3.31 (0.57–19.32)	0.183
Regular cessation	46 (5.7)	1 (5.0)	0.90 (0.12–6.89)	0.917	0.56 (0.07–4.54)	0.583
Prolonged cessation	39 (4.9)	0 (0.0)	N/A	N/A	N/A	N/A

DB, delayed bleeding; APC, argon plasma coagulation; OR, odds ratio; 95% CI, 95% confidential interval; SD, standard deviation; LC, liver cirrhosis; CKD, chronic kidney disease; EGC, early gastric cancer

* All of patients with LC had mild liver dysfunction, as CTP score A

† None of patients with CKD received dialysis.

underwent deep biopsy of 2 lesions in the esophagus, 15 in the stomach, 1 in the duodenum, and 1 in the rectum. Before deep biopsy, EUS was performed in all patients, with the diagnosis of GIST in 13 cases, aberrant pancreas in 3, leiomyoma in 2, and lipoma in 1. Median SMT size was 20 mm (10–40). Definite histological diagnosis was possible for 12 lesions (63%). Immunopathology showed that 9 were GISTs, 2 were aberrant pancreas, and 1 was a leiomyoma. Median biopsy samples needed for definitive histology were 2 (1–5). Median procedure time was 11 min (2–32). There were no adverse events with deep biopsy. **Conclusion:** Deep biopsy has tolerable diagnostic accuracy and low adverse event rates.

Keywords: submucosal tumor, deep biopsy, EUS

OE-0856 (PE-0188) Feasibility of esophagogastroduodenoscopy (EGD) for evaluation of hypopharyngeal cancer extent and safety of EGD guided biopsy

Authors: YU JIN KIM[1]; HHYUNJUN HONG[2]; WON SHIK KIM[3]; MYONG-GI BAEK[1]; SSUKOO JUNG[1]; YU SIK MYUNG[1]; JUNG EUN LEE[1]; PHILL HOON YOON[1]; GANGLOK LEE[1]

Affiliation: [1]Department of Internal Medicine-GI/Hepatology, Catholic Kwandong University, [2]Department of Otorhinolaryngology, Catholic Kwandong University International St. Mary's Hospital, Incheon, and [3]Department of Otorhinolaryngology, Seoul National University Hospital, Seoul, Republic of Korea

Background and Aim: Hypopharyngeal cancer is rare and hard to diagnose for its anatomical location. Advanced stage of hypopharyngeal cancer is lethal due to its early metastasis and structural vicinity to the vital organs. Standard pretreatment diagnosis and tissue sampling methods is not currently established. The present study aimed to evaluate feasibility of esophagogastroduodenoscopy (EGD) as preoperative evaluation of hypopharyngeal cancer extent and safety of EGD guided forceps biopsy. **Methods:** We reviewed nine patients with hypopharyngeal cancer who underwent EGD for evaluation of tumor extent and tissue biopsy from March 2014 to March 2017 at the International St. Mary's Hospital. One experienced endoscopist performed all the EGD procedures in the presence of a head and neck surgeon. Details of procedure included location, tumor extent (presence of pyriform sinus apex involvement), tumor size, passing of endoscope through the upper esophageal sphincter, and complication. **Results:** All the patients were male, and mean age was 69.9+/-10.9 (61–69). Biopsy using forceps was performed in six out of nine patients (66.7%). No complications related to moderate sedation and biopsy were reported, including post biopsy bleeding or respiratory distress. Histologic confirmation was successful in 4 out of 6 patients (66.7%). **Conclusion:** EGD is feasible for evaluation of hypopharyngeal cancer extent and EGD guided forceps biopsy is safe.

Keywords: hypopharyngeal cancer, esophagogastroduodenoscopy, forceps biopsy

OE-0866 (PE-0189) Prospective evaluation of the efficacy of peroral endoscopic myotomy (POEM) in patients with achalasia: A preliminary report

Authors: EUN JEONG GONG[1]; HEE KYONG NA[2]; JI YONG AHN[2]; KEE WOOK JUNG[2]; DO HOON KIM[2]; KEE DON CHOI[2]; HO JUNE SONG[2]; HWOON-YONG JUNG[2]

Affiliation: [1]Department of Internal Medicine-GI/Hepatology, GangNeung Asan Hospital, Gangneung, and [2]Department of Internal Medicine-GI/Hepatology, Asan Medical Center, Seoul, Republic of Korea

Background and Aim: Peroral endoscopic myotomy (POEM) has been performed as an endoscopic alternative to surgical myotomy in patients with achalasia. The aim of this study was to evaluate the efficacy and clinical outcomes of POEM in the treatment of achalasia. **Methods:** Patients who underwent POEM between October 2016 and November 2017 were consecutively recruited. Intraoperative esophagogastric junction distensibility index (EGJ-DI) was measured before and after the myotomy using functional lumen imaging probe (FLIP). Procedural characteristics and clinical outcomes were assessed using prospectively collected data. This study was registered on clinicaltrials.gov (NCT 02989883). **Results:** A total of 20 patients were included in the analyses. The median age of patients was 43 years (range 24–82) and the median symptom duration was 2.5 years (range 0.2–13.0). Regarding the subtype of achalasia, 8 patients (40.0%) were type I, 9 (45.0%) were type II, and 3 (15.0%) were type III. The median procedure time was 68.5 min (range 50.0–120.0), and the median length of the myotomy was 13 cm (range 11–18). Major adverse events were encountered in 3 cases, including bleeding, perforation, and mucosal tear. Based on FLIP measurements, EGJ-DI (mm^2/mmHg) was significantly higher after the completion of the myotomy than baseline (1.3 [range 0.8–6.9] and 6.3 [range 2.5–19.2] at 40-mL volume distension, $p < 0.001$). During a median follow-up of 7.4 months, symptom scores were significantly improved after POEM: Eckardt score, 5 (range 2–11) to 1 (range 0–3), $p < 0.001$; SF-36 score, 67.5 (range 34.5–93.9) to 85.7 (range 53.4–93.3), $p = 0.004$. **Conclusion:** POEM is an effective treatment for achalasia, based on the improvement of both objective measures and symptom.

Keywords: achalasia, myotomy, symptom assessment

OE-0894 (PE-0190) Clinical features of gastric submucosal tumors and evaluation of endoscopic treatment: A single-center study of 858 cases

Authors: XIAOYU WANG; QINGXIANG YU; BANGMAO WANG; HAILONG CAO

Affiliation: Department of Gastroenterology and Hepatology, Tianjin Medical University General Hospital, Tianjin, China

Background and Aim: Gastric submucosal tumors (SMTs) refer to a variety of lesions located beneath mucosal layer, histopathological diagnoses of which are difficult to confirm. Our aim was to investigate the clinical features of gastric SMTs in different histopathological types and evaluate the efficacy and safety of endoscopic treatment. **Methods:** A total of 858 patients with 921 SMTs underwent endoscopic submucosal dissection (ESD) (95.11%) or submucosal tunneling endoscopic resection (STER) (4.89%) between June 2008 and June 2017 in Tianjin Medical University General Hospital. Demographics, clinical data, therapeutic outcomes, complications, pathological characteristics, risk classification, and follow-up outcomes were recorded. **Results:** Among 858 patients, 279 were male (32.52%) and 579 were female (67.48%), and the mean age was 53.76 ± 11.70 years (range 18–80). A total of 921 SMTs with average diameter of 1.18 ± 0.82 cm (range 0.10–8.00) were subdivided into 21 types according to postoperative histopathological diagnosis. Gastrointestinal stromal tumors (36.37%) and leiomyomas (33.01%) were the most common types, and the former appeared predominantly in the fundus (65.33%) while the latter occurred more often adjacent to the esophagogastric junction (EGJ) (69.77%) ($P < 0.001$). SMTs frequently occurred in the fundus (35.07%) and EGJ (28.01%), and mainly originated from muscularis propria (70.4%). The highest diversity (80.95%) of SMTs types was in the antrum including ectopic pancreas, lipoma, inflammatory fibroid polyp, Dieulafoy lesion, etc. En bloc complete resection was achieved in 92.18% of the lesions whereas perforation happened in 159 tumor dissections (17.26%). Follow-up of 45.34 ± 24.31 months (range 9–104) showed no recurrence or metastasis. **Conclusion:** Present study provides a new insight into diagnosis of different SMTs according to their distributions, origins, and sonographic features. ESD and STER are safe and effective in the treatment for gastric SMTs.

Keywords: Gastric submucosal tumor, gastrointestinal stromal tumor, leiomyoma, endoscopic submucosal dissection, submucosal tunneling endoscopic resection

OE-0943 (PE-0191) New frontier interventional therapeutic endoscopy of diode laser for endoscopic submucosal dissection

Authors: JUNSU CHANG; SUNGPYO HONG; WONHEE KIM; JOOYOUNG CHO; INKYUNG YOO

Affiliation: Department of Internal Medicine-GI/Hepatology, Bundang CHA, Sungnam, Republic of Korea

Background and Aim: To evaluate the utility of a novel laser system when performing endoscopic submucosal dissection (ESD) of gastric epithelial neoplasia. **Methods:** From October 2014 to May 2018. A total of 20 patients were enrolled. All patients were diagnosed with gastric epithelial neoplasia. ESD performed by expert endoscopists. **Results:** In 20 patients, ESD was completed using laser system without the need to change other endoscopic knives. The median age was 63 years old. The median time for total procedure was 42 min. The location of the lesions were antrum ($n = 10$), angle ($n = 5$), and body ($n = 5$). Diagnoses before ESD were adenoma ($n = 14$) and adenocarcinoma ($n = 6$). The lesion size were 12 mm on average. As a result of the final histopathological examination, the mean specimen size was 16 mm and final diagnoses were LGD ($n = 14$), ADC ($n = 4$), signet ring cell carcinoma ($n = 1$), and medullary carcinoma ($n = 1$). All lesions were confined to the mucosa, each m1 ($n = 14$) and m2 ($n = 6$). All patients underwent en bloc resection, but two were positive for lateral margin. So curative resection was done in 75.0% of patients. In 4 of 20 patients, active bleeding was observed during ESD, but all case were easily controlled by laser system. No significant complications, such as delayed bleeding and perforation. **Conclusion:** So using the laser system as new dissection tool for endoscopic management of gastric epithelial neoplasia can be safe and useful method.

Keywords: diode laser, endoscopic submucosal dissection

OE-0945 (PE-0192) Endoscopic resection of gastric submucosal masses by a dental floss traction method

Authors: CHUNYAN ZENG[1]; YIN ZHU[1]; XU SHU[1]; NONGHUA LV[1]; QIANG CAI[2]; YOUXIANG CHEN[1]

Affiliations: [1]Department of Gastroenterology, The First Affiliated Hospital of Nanchang University, Nanchang, China; and [2]Department of Internal Medicine-GI/Hepatology, Division of Digestive Diseases, Emory University School of Medicine, Atlanta, USA

Background and Aim: Endoscopic submucosal dissection (ESD) is widely used for treatment of digestive diseases. Dental floss traction method (DFT) has been successfully used in facilitating of ESD to resect mucosal lesions such as early gastric cancer. DFT has not been used in ESD to remove submucosal masses. This study aimed to examine the efficacy of DFT assisted ESD (DFT-ESD) for the removal of submucosal masses.

Methods: From March 2017 to May 2017, a total of 12 patients presenting with gastric submucosal masses at the First Affiliated Hospital of Nanchang University, Jiangxi, China, were enrolled. The tumor characteristics, en bloc resection rates, complications, and outcomes on follow-up were evaluated for all patients. **Results:** The 12 submucosal tumors were completely removed by DFT-ESD. Nine were gastrointestinal stromal tumor. Two were Schwannoma, which located in the greater curvature of gastric corpus. One was gastric ectopic pancreas. All the resected tumors were removed completely with intact tumor capsules. There were no complications, such as bleeding or perforation, and no recurrences identified at the time of follow-up. **Conclusion:** The DFT method efficiently and safely facilitated the ESD procedure during the resection of gastric submucosal tumors.

Keywords: endoscopic submucosal dissection, dental floss traction method, submucosal tumors

OE-0976 (PE-0193) The effect of endoscopic manipulation and belching/retching on the Los Angeles classification of gastroesophageal reflux disease

Authors: SEUNG-JOO NAM; KIL WOO NAM; JI HYUN KIM; SANG HOON LEE; JIN MYUNG PARK; SUNG CHUL PARK; CHANG DON KANG; SUNG JOON LEE

Affiliation: Department of Internal Medicine-GI/Hepatology, Kangwon National University Hospital, Chuncheon, Republic of Korea

Background and Aim: Gastroesophageal junction (GEJ) is a narrow area easily affected by endoscopic manipulation and belching or retching of patients. No study was performed to assess the effect of these factors on the LA classification of reflux oesophagitis. **Methods:** Still images of GEJ were captured during insertion and withdrawal phases of EGD. All the image sets of GEJ (each subject has two image sets, one during insertion, and the other during withdrawal) were mixed randomly and reviewed by two endoscopists. LA classification was recorded as normal, minimal change, A, B, C, and D. For incongruent results, final grading was made by mutual agreement after discussion. **Results:** We prospectively enrolled 369 subjects and 11 subjects were excluded because of unclear GEJ image (finally 358 subjects, mean age 59.6 years). Belching was occurred in more than 70% of subjects (none: 29.7%, mild: 52.1%, moderate: 15.7%, severe: 2.5%). Retching was occurred in 7.5% of subjects (none: 92.4%, mild: 3.4%, moderate: 4.2%, severe: 0%). LA classifications graded from image sets during withdrawal phase were upgraded significantly compared to classifications graded from image sets during insertion phase ($p < 0.001$). LA classification change was occurred in 49 subjects (13.7%). The most common change between insertion and withdrawal phase was from “normal” to “minimal change” (Table 1). **Conclusion:** Endoscopic grading of gastroesophageal reflux disease can be affected by endoscopic manipulation during EGD. We suggest taking pictures of GEJ during insertion phase rather than withdrawal phase for exact classification.

Keywords: gastroesophageal reflux disease, LA classification

Table 1 Insertion *Withdrawal Cross tabulation

		Withdrawal phase				Total
		normal	minimal	LA-A	LA-B	
Insertion phase	normal	159	38	4	0	201
	minimal	5	81	2	0	88
	LA-A	0	0	62	0	62
	LA-B	0	0	0	7	7
Total		164	119	68	7	358

OE-0997 (PE-0194) Comparative study of ESD and surgical resection for gastric SETs originated from muscularis propria

Author: CHANG BEOM RYU

Affiliation: Department of Internal Medicine-GI/Hepatology, Soon Chun Hyang University Bucheon Hospital, Bucheon, Republic of Korea

Background and Aim: Endoscopic resection for gastric subepithelial tumors (SETs) originated from the muscularis propria (GSET-PM) has offered less invasive alternatives to surgical resection. The aims of this study were to compare endoscopic submucosal dissection (ESD) with surgical resection for the removal of GSET-PM. **Methods:** This study involved 17 patients with GSET-PM removed by ESD and 76 patients who underwent curative surgical resection. ESD was attempted in GSET-PM with well margined tumors which was below 5 cm and showed an endoluminal growth pattern according to endoscopic ultrasound (EUS) finding. **Results:** ESD and surgery group were more likely to have upper portion (10/17, 58.8%) and mid portion (41/76, 53.8%) ($p = 0.039$). ESD group were smaller median tumor size (25.6 vs 35.9 mm, $p = 0.037$) and higher endoluminal ratio ($58.5 \pm 9.1\%$ vs $45.8 \pm 15.4\%$, $p = 0.002$). ESD group were mostly to have Yamada type III (10/17, 58.8%) and surgery group were mostly Yamada type I (52/76, 68.4%) ($p < 0.001$). Complete resection by ESD was lower than by surgical resection (82.4% vs 100%, $p < 0.001$). In ESD group, 3 performed surgical resection after ESD and 1 showed perforation was completely resected with endoscopic closure. In surgery group, complications occurred in 6 patients. Although surgery group was lower in complication rate than ESD group ($p = 0.006$), severity of complications were higher in the surgery group and there were no mortalities in the ESD group compared with 2 in the surgery group. There was no statistical difference of recurrence and the follow-up period between two groups. **Conclusion:** ESD can be one of good options for the resection of endoluminal GSET-PM and could be replace treatment by surgical resection in Yamada type III with a high endoluminal ratio.

Keywords: subepithelial tumors (SETs), endoscopic submucosal dissection (ESD)

8.9%) several times. Both of them had retinopathy and one had end-stage renal disease and hyperlipidemia. Gastric scintigraphy revealed severe gastroparesis (case 1 with liquid meal, $T_{1/2}$ 1,065 [reference < 23] minutes, percent of gastric emptying 5%; case 2 with oat meal, $T_{1/2}$ 219 [reference < 85] minutes, percent of gastric emptying 14%). The procedure time was 99 and 65 min. Technical success rate was 100%. Clinical response rate was 50% (case 1 had improvement of symptoms for only 2 weeks). No procedure-related complication or mortality was reported. **Conclusion:** G-POEM is a safe treatment strategy for refractory DG. Clinical response seems to be related to the degree of gastric emptying and the adequacy of DM control. More experiences are needed to elucidate long-term outcome.

Keywords: gastroparesis, peroral endoscopic pyloromyotomy, diabetic mellitus, third space endoscopy

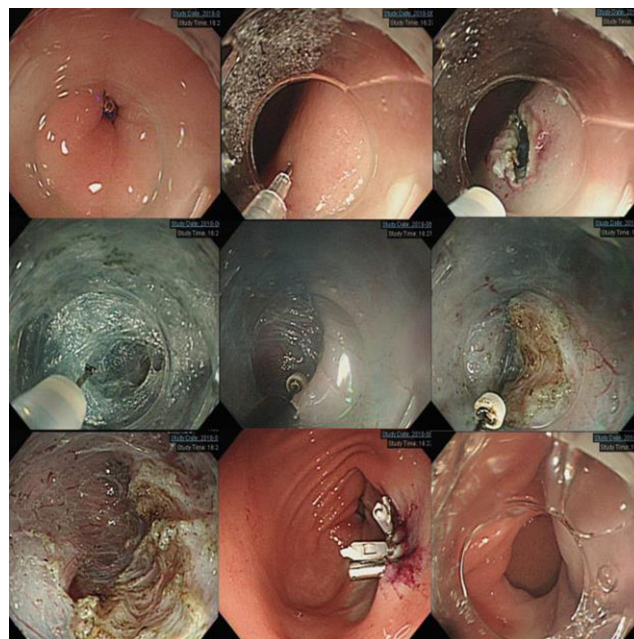


Figure 1: G-POEM procedure.

OE-0448 (PE-0197) Gastric peroral endoscopic pyloromyotomy for diabetic gastroparesis: Preliminary experience in Taiwan

Authors: CHEN-SHUAN CHUNG[1]; CHENG-LU LIN[1]; JIANN-MING WU[1]; KUO-HSIN CHEN[1]; KUANG-CHIH CHEN[1]; KUO-SHYANG JENG[1]; TZONG-HSI LEE[1]; CHENG-KUAN LIN[1]; HSIU-PO WANG[2]

Affiliation: [1]Department of Division of Gastroenterology and Hepatology, Department of Internal Medicine, Far Eastern Memorial Hospital, New Taipei City, and [2]Department of Internal Medicine, National Taiwan University Hospital, Taipei, Taiwan

Background and Aim: Gastroparesis is one of the complications of diabetic mellitus (DM). Patients with refractory diabetic gastroparesis (DG) have poor life quality. Gastric peroral endoscopic pyloromyotomy (G-POEM) is a promising treatment. It was a pioneer study investigating efficacy and safety of G-POEM for DG in Taiwan. **Methods:** Two refractory DG patients who underwent G-POEM were enrolled between December 2017 and June 2018. Clinical and endoscopic data were analyzed. **Results:** The two female DM (case 1-type 1, case 2-type 2) patients had body mass index of 20.8 and 24.8, respectively. The age/period between diagnosis of DM and DG were 26/12 (case 1) and 43/6 (case 2) years. They had been admitted for nutritional support and poor controlled DM (HbA1c case 1-12% and case 2-

OE-0468 (PE-0198) Feasibility study of adipose mesenchymal stem cell membrane transplantation for prevention of esophageal ESD postoperative stenosis

Authors: MEI HONG CHEN; XUAN LI; XU DONG ZHU; GUO XIN ZHANG

Affiliation: Department of Gastroenterology Department, The First Affiliated Hospital of Nanjing Medical University, Nanjing, China

Background and Aim: At present, ESD is the preferred treatment method for esophageal carcinoma and precancerous lesions, but the esophageal stricture caused by extensive mucosal dissection seriously affects the quality of life of patients. Adipose mesenchymal stem cells which is ideal seed cells in regenerative medicine field, combined with the new technology of tissue engineering—cell membrane, help repair the damaged tissues or cells. The purpose of this study was to explore the feasibility of ADSCs combined with cell membrane technology to prevent esophageal ESD postoperative stenosis. **Methods:** The green fluorescent protein-labeled ADSCs membranes were prepared using temperature-sensitive culture dishes. The ADSCs membranes were set as the experimental group, and the conventionally adherent ADSCs were used as the control group. The differences in the levels of VEGF, TGF- β 1, and HGF in the two groups were compared. The skin ulcers of nude mice and mini-pig esophageal artificial ulcers were prepared, and the recovery of the wounds after transplantation was observed. **Results:** We found that the cell contents are high in the cell membrane, rich in extracellular matrix, and there is a connection between cells and cells. The expression levels of VEGF, TGF- β 1, and HGF in the experimental group are higher than those in the control group. The healing time of the skin ulcer in the experimental group was 15 days, and that of the blank group was 18 days. The healing rate of the transplanted group was faster than that of the blank group. In the blank group, the incidence of esophageal stenosis was higher than that in the transplantation group. Dysphagia occurred frequently and weight decreased significantly in the blank group. **Conclusion:** ADSCs combined with cell membrane technology is feasible to prevent esophageal ESD postoperative stenosis, but a large number of clinical studies are needed to further confirm it.

Keywords: endoscopic submucosal dissection, esophageal stenosis, adipose tissue-derived stem cells, membrane transplantation

OE-0744 (PE-0199) Prognosis and risk factors for non-curative resection of early esophageal cancer with endoscopic submucosal dissection

Authors: JIAJIA YANG; GUO XIN ZHANG

Affiliation: Department of Gastroenterology, The First Affiliated Hospital of Nanjing Medical University, Nanjing, China

Background and Aim: Endoscopic submucosal dissection (ESD) is an effective treatment for early stage esophageal cancer. However, the prognosis of patients with non-curative resection is still unclear since the existence of non-curative resection factors. This study was designed to evaluate the prognosis of patients with early esophageal cancer who underwent non-curative ESD and the risk factors of non-curative resection. **Methods:** Retrospective study, from January 2013 to March 2018, including patients with esophageal high-grade intraepithelial neoplasia and early stage esophageal cancer who have undergone ESD treatment. Information mainly based on the preoperative and postoperative pathological results to determine whether the resection is curative. **Results:** A total of 525 patients, including 348 patients with high-grade intraepithelial neoplasia and 177 patients with early-stage esophageal cancer; 79 early-stage cancer cases and 55 high-grade intraepithelial neoplasia cases (remaining high-grade intraepithelial neoplasia) were judged as “non-curative resections.” In addition, fifteen cancer cases remain high-grade intraepithelial neoplasia after ESD. The median follow-up was 26.7 months in curative resection group and 29.2 months in non-curative resection group. There was no significant difference in overall survival ($P = 0.42$). Local recurrence occurred in seven cases, one in curative group and six in non-curative group ($P = 0.037$). Four patients have lymph node metastasis, all in non-curative resection group ($P = 0.029$). Twelve cases underwent additional surgery, and 6 cases underwent re-ESD. No tumor recurrence or distant metastasis compared with simple followed observation ($P = 0.046$). Lesion size, depth of invasion, vascular invasion, etc. may be related to non-curative resection ($P < 0.05$). **Conclusion:** Endoscopic submucosal dissection (ESD) is a reliable treatment for early esophageal cancer. When resection is non-curative, additional surgery or re-ESD can improve the prognosis. Patients with a lower degree of differentiation, larger lesions, deeper submucosal infiltration (exceed the relative indications of ESD) or vascular invasion, ESD treatment should be fully assessed.

Keywords: endoscopic mucosal dissection, esophageal cancer, non-curative resection, risk factors, prognosis