

## 유리체절제술 후 발생한 의인성 수정체유발녹내장

### Iatrogenic Lens Trauma-induced Glaucoma Following Pars Plana Vitrectomy

김유철, 이수진, 강경태

Yu Cheol Kim, Soo Jin Lee, Kyung Tae Kang

계명대학교 의과대학 계명대학교 동산병원 안과학교실

Department of Ophthalmology, Keimyung University Dongsan Hospital, Keimyung University School of Medicine, Daegu, Korea

**Purpose:** To report a case of iatrogenic lens-trauma-induced glaucoma with pseudohypopyon after pars plana vitrectomy, which is a rare presentation that is often confused with postoperative endophthalmitis.

**Case summary:** A 63-year-old male presented with uncontrolled intraocular pressure with suspected postoperative endophthalmitis in the right eye. The intraocular pressure was 50 mmHg, and slit-lamp examination revealed inflammatory cells, multiple iridescent crystalline materials in the anterior chamber, and a blood-tinged pseudohypopyon, resulting in a diagnosis of iatrogenic lens-induced glaucoma secondary to posterior capsular break during pars plana vitrectomy. Phacoemulsification, pars plana lensectomy with vitrectomy, and intraocular lens implantation in the sulcus using the optic capture technique were performed. Intraoperatively, a linear posterior capsular break was identified as expected. One month postoperatively, the patient's visual acuity improved to 20/20, and the intraocular pressure was 8 mmHg without any medication.

**Conclusions:** Iatrogenic crystalline lens damage during pars plana vitrectomy can induce glaucoma, which can be confused with postoperative endophthalmitis owing to the presence of a pseudohypopyon, and the two diseases should be differentiated from each other.

**Keywords:** Endophthalmitis; Glaucoma; Vitrectomy

## Introduction

Touching a crystalline lens in a phakic eye with instruments during vitrectomy is a common mistake made by novice vitreoretinal surgeons and can induce a traumatic cataract from which lens-induced glaucoma may arise. However, lens-induced glaucoma with pseudohypopyon, which is often confused with postoperative endophthalmitis, after pars plana vitrectomy (PPV) is rare. Herein, we report a case of iatrogenic lens-induced glaucoma following PPV.

## Case Report

This case study was approved by the Institutional Review Board (IRB) of Keimyung University Dongsan Hospital (approval No. 2021-01-030), and informed consent was waived under the approval of the IRB. All procedures in this study adhered to the tenets of the Declaration of Helsinki.

A 63-year-old male was referred to the retina clinic for uncontrolled intraocular pressure (IOP) with suspected postoperative endophthalmitis (oculus dexter [OD]) refractory

### Address reprint requests to Yu Cheol Kim, MD, PhD

Department of Ophthalmology, Keimyung University Dongsan Hospital, Keimyung University School of Medicine, #1095 Dalgubeol-daero, Dalseo-gu, Daegu 42601, Korea  
Tel: 82-53-258-7855, Fax: 82-53-258-4558  
E-mail: eyedr@dsmc.or.kr

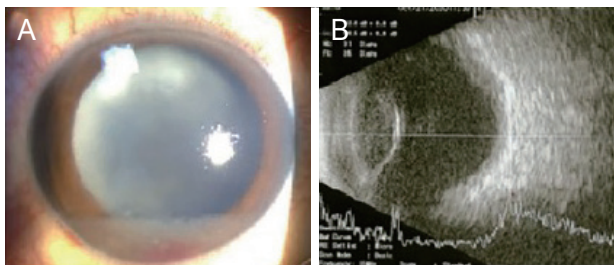
**Received:** 2021. 5. 24.

**Revised:** 2021. 6. 30.

**Accepted:** 2021. 7. 12.

to topical antibacterial agents and glaucoma medication. He underwent PPV with endo-laser photocoagulation and air tamponade for treating a vitreous hemorrhage due to a retinal tear (OD) 8 days before the referral. The patient's past medical history included hypertension, dyslipidemia, and coronary stent implantation for treating a myocardial infarction, as well as a right nephrectomy for treating renal cell carcinoma, but he had no specific ophthalmic history. Postoperatively, the patient continued his regular medications of oral clopidogrel (Plavix<sup>®</sup>, Sanofi-Aventis, Paris, France) and sunitinib malate (Sutent<sup>®</sup>, Pfizer, New York, NY, USA), and he also applied topical levofloxacin (1.5%; Cravit<sup>®</sup>, Santen Pharmaceutical Co, Osaka, Japan) and prednisolone acetate (1%; Predforte<sup>®</sup>, Allergan Inc., Irvine, CA, USA) to his right eye every 2 hours. The patient noted ocular pain and blurry vision (OD) 2 days before visiting our retina clinic, and the pain continued to increase until the visit.

The best-corrected visual acuity using the Snellen chart was hand motion (OD) and 20/20 (oculus sinister [OS]), and the IOP by Goldmann applanation tonometry was 50 mmHg (OD) and 20 mmHg (OS). Slit-lamp examination of the right eye revealed mild, microcystic, corneal epithelial edema, the presence of inflammatory cells (grade 4+ according to Standardization of Uveitis Nomenclature), multiple iridescent crystalline materials floating in the deep anterior chamber with settled-down, white, fluffy materials forming a blood-tinged pseudohypopyon, and an edematous white cataract (Fig. 1A). The left eye was unremarkable aside from mild, age-related, nuclear sclerotic changes. Gonioscopic examination revealed open angles in all quadrants in both eyes. Fundus examination and optical coherence tomography could not be performed owing to a cloudy medium. Ocular sonography showed an echogenic vitreous but no retinal detachment.



**Figure 1.** (A) Slit-lamp examination reveals corneal edema, white fluffy and blood-tinged crystalline materials settled within the anterior chamber, and a hypermature cataract. (B) Ocular sonography shows an echogenic vitreous but no retinal detachment.

tachment (Fig. 1B).

The authors suspected lens-trauma-induced glaucoma secondary to posterior capsular break during PPV and performed phacoemulsification and pars plana lensectomy with vitrectomy. The liquefied cortex seeped into the anterior chamber at the start of continuous curvilinear capsulorhexis. In the middle of phacoemulsification, several lens fragments dropped into the vitreous cavity, and a linear posterior capsular break was identified as expected. Numerous, fluffy, crystalline materials were found floating in the vitreous cavity, and some settled down on the posterior pole. The fluffy crystalline materials and the dropped fragments were removed with a 25-gauge vitreous cutter, and a 3-piece intraocular lens (SENSAR<sup>®</sup>, AR40e, AMO Inc., Santa Ana, CA, USA) was inserted in the sulcus using the optic capture technique.

On postoperative day 1, IOP (OD) was 11 mmHg, and the patient's pain was resolved. Over the next 4 weeks, the anterior chamber inflammation and corneal edema also gradually resolved. One month postoperatively, the patient's vision improved to 20/20, and IOP was 8 mmHg without any medication.

## Discussion

Several types of lens-induced glaucoma exist. Phacolytic glaucoma is a rare form of open-angle glaucoma induced by trabecular outflow obstruction, with lens proteins leaking through capsular micro-ruptures within a hypermature cataract. Phacomorphic glaucoma is a secondary angle-closure glaucoma caused by the forward displacement of an intumescent cataract causing a pupillary block. Lens particle glaucoma is the presence of lens fragments in the aqueous humor with an evident macroscopic capsular disruption, whereas phacolytic glaucoma occurs with a grossly intact capsule. Finally, phacoantigenic glaucoma develops after granulomatous inflammation against lenticular antigens that obstruct the trabecular meshwork [1,2].

Yoo et al. [3] reported full-thickness dehiscence of the anterior lens capsule on scanning electron microscopy, but not on light microscopy, in a patient with phacolytic glaucoma. The mechanism of leakage of soluble contents from a hypermature cataract is still debated; however, recent reports suggest that lens proteins leak through micro-tears produced

by excessive lens maturation, which causes an immunologic phagocytic reaction of macrophages or a direct physical barrier on the trabecular meshwork owing to its large molecular size [2,4].

Mavrakanas et al. [4] categorized phacolytic glaucoma into acute and subacute types. The acute type is caused by the rapid egress of liquefied lens protein alone into the aqueous humor through non-traumatic microscopic ruptures of the anterior lens capsule. This is supported by the findings of Epstein et al. [5], who reported a case of phacolytic glaucoma in which the aqueous humor specimen did not contain macrophages on phase microscopy. In contrast, the subacute type manifests more gradually as the number of phacolytic macrophages increases in the aqueous humor resulting from an immunological response to liquefied lens protein.

In the current case, the posterior lens capsule was presumably torn by a vitrectomy cutter during the first PPV, and the lens proteins began to denature and swell rapidly. Possibly, the absence of anterior hyaloids, which can promote hydration from fluids in the vitreous cavity, accelerated lens-hypermaturation and produced micro-disruptions of the anterior capsule through which the denatured lens protein leaked, while the liquefied lens proteins that degraded owing to the posterior capsule disruption migrated to the anterior chamber through the zonular gap. Accordingly, the current case may demonstrate a mixed mechanism of phacolytic glaucoma and lens particle glaucoma. The pseudohypopyon was presumably composed of nuclear debris, liquefied lens protein, macrophages, and plasma protein. We can differentiate pseudohypopyon in patients with lens-induced glaucoma from hypopyon in patients with postoperative endophthalmitis by its color (whitish or yellowish), the absence of a cyclitic membrane or coagulum, and the presence of a hypermature cataract or floating lens particles, which are larger than inflammatory cells. In the present case, the anterior chamber was deep and within the normal range, although a swollen lens was suspected. This is possibly because the posterior capsular break prevented the lens from severely swelling and spreading due to the lens protein leakage out of the lens capsule, thereby reducing the total lens volume.

The limitation of our case is the lack of a pathologic analysis using light or electron microscopy. Nonetheless, this report describes a rare case of iatrogenic lens-induced glaucoma with pseudohypopyon after PPV masquerading as postoperative endophthalmitis.

In conclusion, our experience highlights that vitreoretinal surgeons should be aware that iatrogenic crystalline lens damage during PPV may cause lens-induced glaucoma, and because lens-induced glaucoma can be confused with postoperative endophthalmitis owing to pseudohypopyon, the two diseases must be correctly differentiated from each other.

### Conflicts of Interest

Yu Cheol Kim is a consultant for Novartis and Bayer and received honoraria from Allergan, Bayer, and Novartis, and research grants from Bayer and Novartis. Kyung Tae Kang received honoraria from Novartis. Soo Jin Lee has no conflicting interests to disclose.

### Acknowledgments

This research was supported by the National Research Foundation of Korea grant (NRF-2019R1G1A1011559). The sponsor had no role in the design or conduct of this research.

### References

1. Ellant JP, Obstbaum SA. Lens-induced glaucoma. *Doc Ophthalmol* 1992;81:317-38.
2. Papaconstantinou D, Georgalas I, Kourtis N, et al. Lens-induced glaucoma in the elderly. *Clin Interv Aging* 2009;4:331-6.
3. Yoo WS, Kim BJ, Chung IY, et al. A case of phacolytic glaucoma with anterior lens capsule disruption identified by scanning electron microscopy. *BMC Ophthalmol* 2014;14:133.
4. Mavrakanas N, Axmann S, Issum CV, et al. Phacolytic glaucoma: are there 2 forms? *J Glaucoma* 2012;21:248-9.
5. Epstein DL, Jedziniak JA, Grant WM. Identification of heavy-molecular-weight soluble protein in aqueous humor in human phacolytic glaucoma. *Invest Ophthalmol Vis Sci* 1978;17:398-402.