

# Complex Variations in the Course of the Sciatic Nerve and Origin of the Inferior Gluteal Nerve: A Case Report

Kwang-Rak Park<sup>1</sup>, Min-Seok Kim<sup>2</sup>, Young-Seop Lee<sup>2</sup>, Jae-Ho Lee<sup>1</sup>

<sup>1</sup>Department of Anatomy, Keimyung University School of Medicine

<sup>2</sup>Medical Course, Keimyung University School of Medicine

**Abstract** : The sciatic nerve (SN) and the inferior gluteal nerve (IGN) exit through the greater sciatic foramen below the piriformis muscle (PM). Its variation is extremely frequent and it may induce clinical symptoms. During an educational dissection in gluteal region, variation in SN and IGN was found. The common fibular nerve (CFN) portion of the SN pierced the PM and then, it gave off a small branch to the gluteus maximus muscle, as IGN. We reported this rare variation and discussed its clinical significance.

**Keywords** : Sciatic nerve, Inferior gluteal nerve, Piriformis muscle, Variation

## INTRODUCTION

The inferior gluteal nerve (IGN) is formed by the contribution of the sacral ventral rami from L5 to S2. It exits through the greater sciatic foramen below the piriformis muscle (PM), leaves the pelvis along the posterior aspect of the sciatic nerve, enters the gluteal region and innervates the gluteus maximus [1]. The sciatic nerve (SN) is the largest peripheral nerve of human body. It is continuation of the upper band of the sacral plexus and provides motor innervation to the posterior compartment of the thigh. This nerve divides into two terminal branches, common fibular nerve (CFN) and tibial nerve (TN) usually

at the superior angle of popliteal fossa [2].

The results of anatomical variation and clinical practice of SN and PM have been described by several authors [3-5]. An explanation of the anatomical variation between IGN and PM has also been reported by some authors [6,7]. Recently, researches on the nerves of the gluteal region for clinical treatment, skin flap surgery, and imaging diagnosis have been conducted [8-10]. Therefore, it is required to review the basic clinical data of SN and IGN exiting the pelvis based on PM.

The SN presented significant variations within its topography and division. Some of them may lead to compression of nerve resulting in piriformis syndrome within the entrapment of SN [4]. Its common variations were described by Beason and Anson [11] into six groups, Type 1: SN passing below the inferior margin of PM; Type 2: The CFN exits through the PM and TN exits below the PM; Type 3: The CFN exits above the PM and TN exits below the PM; Type 4: SN exits through the PM; Type 5: The CFN exits above the PM and TN through the PM; Type 6: SN passing above the superior margin of PM. However,

\*본 연구는 의학과 4학년 학생인턴 과정에 수행되었음.

The author(s) agree to abide by the good publication practice guideline for medical journals.

The author(s) declare that there are no conflicts of interest.

**Received:** November 26, 2021; **Revised:** December 20, 2021;

**Accepted:** December 20, 2021

**Correspondence to:** Jae-Ho Lee (Department of Anatomy, Keimyung University School of Medicine, 1095, Dalgubeoldae-ro, Dalseo-Gu, Daegu 42601, Republic of Korea)

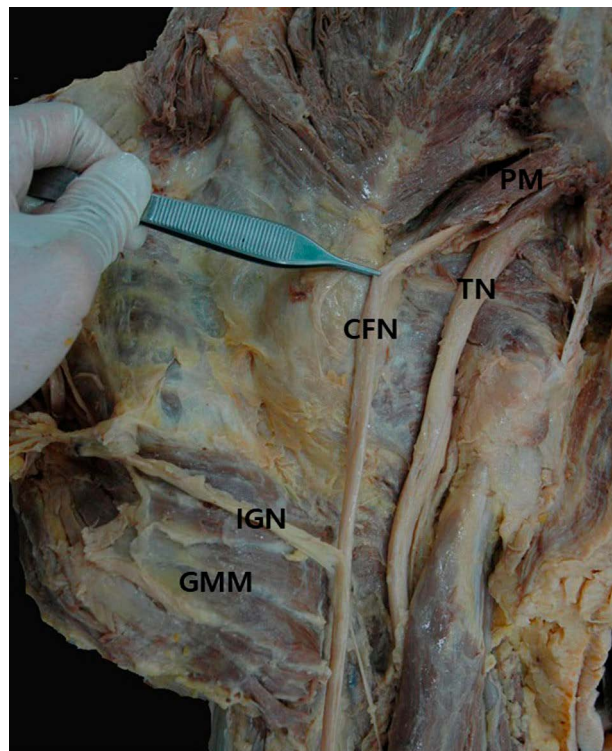
**E-mail:** anato82@dsme.or.kr

there are some variations remaining undefined. The study concerning such variation will be helpful when performing a surgical intervention in the gluteal region and it will reduce the risk of injuring these nerves. In this case, we reported anatomical variations in which IGN derived from the CFN exited through the PM.

## CASE REPORT

During an educational dissection in gluteal region, an abnormal pattern of the SN was found on the left side of body of 66-year-old male cadaver, fixed in 10% formalin (Fig. 1). The routine dissection of a left hemipelvis and gluteal region was performed from superficial to deep planes. Firstly, the skin and subcutaneous tissue were removed, then the gluteus maximus was exposed. This muscle was dissected according to perpendicular line and neurovascular structures were shown.

SN was divided into CFN and TN in pelvis. The TN part of the SN left the pelvis below the piriformis muscle



**Fig. 1.** Posterior view of the right gluteal region. The common fibular nerve (CFN) exited through the piriformis muscle (PM), and the inferior gluteal nerve (IGN) branched from CFN. TN, tibial nerve; GMM, gluteus maximus muscle.

typically. However, the CFN portion of the SN pierced the PM and continued 8 cm more inferiorly. Then, it gave off a small branch to the gluteus maximus muscle, as the inferior gluteal nerve (IGN). The TN and CFN continued inferiorly to innervate lower muscles.

## DISCUSSION

In this study, we showed that the CFN passed through the PM and the TN passed below the inferior border of the PM. The normal course of the SN out of pelvis is through the sciatic foramen below the inferior margin of PM and descends between the greater trochanter and the ischial tuberosity. Then, it ends by dividing TN and CFN in the lower third of the thigh. During embryological development, nerves of the lower limb form two plexuses, namely lumbar and sacral at the base of limb bud. Dorsal and ventral components are formed later from these plexuses. SN is formed by the close downward movement of large dorsal (common fibular) and the ventral (tibial) components during development. Hence, the common fibular and tibial components can separate from each other at various levels from their origin [12]. Beason and Anson [11] classified the anatomical relationship between SN and PM into 6 types, and when applied, our case corresponds to type 2. Type 2 is a pattern that is very vulnerable to nerve entrapment because the CFN exits through the PM. Also, It may be closely related to piriformis syndrome. Piriformis syndrome is estimated to be responsible for 6-8% cases annually of low back pain [13]. Therefore, it is considered that additional studies on the prevalence of each type are needed.

In this case, the IGN was directly originated from the CFN perforating the PM. It did not match any classification and has not been reported any literature. The IGN usually exited below the PM as an independent branch before exiting the greater sciatic foramen. In present case, when the CFN is pressed by the PM, both symptoms of general piriformis syndrome and the IGN nerve entrapment are prevalent.

In this case, IGN branched from the main branch of CFN, showing the innervation of the gluteus maximus muscle. Sumalatha et al. [14] reported that there was no lower gluteal nerve and that one of the two CFN branches innervated the gluteus maximus muscle. This can be seen as similar in that a part of CFN plays the role of IGN. However, unlike

previous studies, which started with two branches from the beginning and finally merged, this case started as a single branch when CFN penetrates the PM, and there is a key difference in terms of branching IGN from the main branch.

Poutoglidou et al. [15] used meta-analysis and systematic review for SN variants in relation to PM, and suggested the prevalence of each type by race. Type 1 had a typical morphological pattern and had the most common prevalence (90%). Type 2, with a pattern similar to our case, had a prevalence of 8%. However, there was no reports of this type which IGN is derived from CFN. In type 2, in terms of prevalence by race, the prevalence in East Asia (24%) was significantly higher than in Europe (9%), the United States (4%), and Africa (3%) [15]. Since this is a result limited to the Chinese and Japanese, it is considered that a follow-up study on the Korean population should be conducted.

Although this study is a report on the origin of the inferior gluteal nerve, there is a limitation in that it does not include a specific report on the relationship of the nerve course with other structures such as vessels.

The diagnostic and therapeutic procedure for the variation of SN division at different body level is difficult in many clinical and surgical cases. The posterior and posterolateral approaches to the hip joint are the most common and practical. However, this approach is vulnerable to iatrogenic damage to the gluteal region. Thus, knowing possible variations will help surgeons explain unexpected pain and prevent increased iatrogenic injuries during surgery and invasive procedures. Therefore, clinician should be aware of this rare variation.

## REFERENCES

1. Moore KL, Dalley AF, Agur AM. Clinically oriented anatomy. 8th ed. Philadelphia: Wolters Kluwer; 2018.
2. Sladjana UZ, Ivan JD, Bratislav SD. Microanatomical structure of the human sciatic nerve. *Surg Radiol Anat.* 2008;30: 619-26.
3. Cassidy L, Walters A, Bubb K, Shoja MM, Tubbs RS, Loukas M. Piriformis syndrome: implications of anatomical variations, diagnostic techniques, and treatment options. *Surg Radiol Anat.* 2012;34:479-86.
4. Güvencer M, Akyer P, Iyem C, Tetik S, Naderi S. Anatomic considerations and the relationship between the piriformis muscle and the sciatic nerve. *Surg Radiol Anat.* 2008;30:467-74.
5. Smoll NR. Variations of the piriformis and sciatic nerve with clinical consequence: a review. *Clin Anat.* 2010;23:8-17.
6. Pavai J, Nayak S. A case of bilateral high division of sciatic nerve with a variant inferior gluteal nerve. *Neuroanatomy* 2006;5:33-4.
7. Yan J, Takechi M, Hitomi J. Variations in the course of the Inferior gluteal nerve and artery: a case report and literature review. *Surg Sci.* 2013;4:429.
8. Ling ZX, Kumar VP. The course of the inferior gluteal nerve in the posterior approach to the hip. *J Bone Joint Surg Br.* 2006;88:1580-3.
9. Skalak AF, McGee MF, Wu G, Bogie K. Relationship of inferior gluteal nerves and vessels: target for application of stimulation devices for the prevention of pressure ulcers in spinal cord injury. *Surg Radiol Anat.* 2008;30:41-5.
10. Windhofer C, Brenner E, Moriggl B, Papp C. Relationship between the descending branch of the inferior gluteal artery and the posterior femoral cutaneous nerve applicable to flap surgery. *Surg Radiol Anat.* 2002;24:253-7.
11. Beaton LE, Anson BJ. The relation of the sciatic nerve and of its subdivisions to the piriformis muscle. *Anat Rec.* 1937; 70:1-5.
12. Anbumani T, Thamarai S, Anthony AS. Sciatic nerve and its variations: an anatomical study. *Int J Anat Res.* 2015;3:1121-7.
13. Fishman LM, Dombi GW, Michaelsen C, Ringel S, Rozbruch J, Rosner B, et al. Piriformis syndrome: diagnosis, treatment, and outcome - a 10-year study. *Arch Phys Med Rehabil.* 2002; 83:295-301.
14. Sumalatha S, D Souza AS, Yadav JS, Mittal SK, Singh A, Kotian SR. An unorthodox innervation of the gluteus maximus muscle and other associated variations: A case report. *Australas Med J.* 2014;7:419-22.
15. Poutoglidou F, Piagkou M, Totlis T, Tzika M, Natsis K. Sciatic Nerve Variants and the Piriformis Muscle: A Systematic Review and Meta-Analysis. *Cureus.* 2020;12:e11531.