JMIS
The Journal of Minimally Invasive Surgery

ORIGINAL ARTICLE
pISSN 2234-778X • eISSN 2234-5248
J Minim Invasive Surg 2024;27(1):14-22

Comparison between liquid skin adhesive and wound closure strip for skin closure after subcuticular suturing in single-port laparoscopic appendectomy: a single-center retrospective study in Korea

Kyeong Eui Kim[1], Yu Ra Jeon[2], Sung Uk Bae[1], Woon Kyung Jeong[1], Seong Kyu Baek[1]

[1]Department of Surgery, Keimyung University Dongsan Medical Center, Keimyung University School of Medicine, Daegu, Korea
[2]Department of Surgery, School of Medicine, Keimyung University, Dongsan Medical Center, Daegu, Korea

Purpose: This study was performed to evaluate the safety and feasibility of skin adhesives and to compare postoperative and cosmetic outcomes after wound closure in single-port laparoscopic appendectomy (SPLA) between skin adhesives and steri-strips.

Methods: This was a single-center retrospective study. We included 22 and 47 patients in whom skin adhesive and steri-strips were used respectively, for skin closure after subcuticular suturing in SPLA between August 2014 and 2020. The patient scar assessment questionnaire (PSAQ) was completed postoperatively to assess postoperative cosmetic outcomes.

Results: On the postoperative day, patients in whom skin adhesive was used had significantly lower numeric rating scores than in whom steri-strips were used (2.8 ± 0.8 vs. 3.9 ± 0.8, $p < 0.001$). The frequency of analgesic administration within 24 hours and between 24 and 48 hours after surgery was significantly lower in the skin adhesive group compared to the wound closure strip group (1.4 ± 0.8 vs. 2.7 ± 1.2, $p = 0.013$ and 0.2 ± 0.4 vs. 0.7 ± 0.9, $p = 0.002$, respectively). In the PSAQ, "satisfaction with appearance" and "satisfaction with symptoms" subitem scores were significantly lower in patients in whom skin adhesive was used (11.3 ± 3.0 vs. 15.1 ± 4.5, $p = 0.006$ and 6.5 ± 1.8 vs. 9.5 ± 3.3, $p = 0.003$), whereas, "appearance" and "consciousness" subitems revealed no statistically significant differences between the groups.

Conclusion: Liquid skin adhesive closures seem to be safe and feasible and cause less postoperative pain, resulting in greater patient satisfaction with postoperative scars than wound closure strip closure after subcuticular suturing in SPLA.

Keywords: Appendectomy, Wound closure techniques, Surgical tape, Laparoscopy, Treatment outcome

Received January 10, 2024
Revised March 6, 2024
Accepted March 11, 2024

Corresponding author
Sung Uk Bae
Department of Surgery, Keimyung University Dongsan Medical Center, Keimyung University School of Medicine, 1035 Dalgubeol-daero, Dalseo-gu, Daegu, Korea
E-mail: hispower@dsmc.or.kr
https://orcid.org/0000-0002-7876-4196

Kyeong Eui Kim and Yu Ra Jeon contributed equally to this work.

INTRODUCTION

Laparoscopic surgery is replacing laparotomy for the treatment of several intraabdominal conditions. It provides numerous benefits over open surgery, including lesser blood loss, fewer analgesic needs and complications, faster recovery, and shorter

hospital stays [1–3]. Since the introduction of laparoscopic appendectomy by Semm in 1983 [4] for appendicitis, it has grown to include more complex conditions, such as perforated appendicitis and periappendiceal abscess [5–7].

With the rapid growth of minimally invasive surgery in recent years, efforts have been made to reduce surgical trauma and enhance cosmetic outcomes, leading to the development of single-port laparoscopic surgery for various diseases [8–10]. Single-port laparoscopic appendectomy (SPLA) was initially presented by Esposito in 1998 [11] with the potential benefits of improved cosmetic outcomes, less postoperative pain, and avoidance of hemorrhagic complications from potential injury to the epigastric arteries. Thus, SPLA has become the preferred treatment choice for acute appendicitis and is considered a viable alternative to the standard multiport laparoscopic appendectomy (MPLA) [12–14].

Since the initial clinical report in 1959, the 1949-developed cyanoacrylate has been utilized as a skin adhesive [15]. There have been investigations on various skin closure techniques in laparoscopic surgery, including non-absorbable monofilament sutures [16], skin staplers [17], and wound closure strips [18] and liquid skin adhesive after subcuticular sutures [19]. Skin adhesives reportedly shorten the time required for wound closure and do not require removal, resulting in a smaller operative scar [20,21]. In addition, the protective film generated by the adhesive limits the penetration of extraneous substances and bacteria, allowing for water-dependent everyday activities. Moreover, it has superior cosmetic results compared to the other closure techniques [22–24].

Skin adhesives are not commonly used in abdominal surgery for inflammatory diseases such as appendicitis, cholecystitis, and peritonitis because of concerns that inflammatory exudate may not drain through the suture site, thereby increasing the risk of surgical site infection (SSI). There has been no research on skin adhesive use for wound closure in SPLA, despite have being assessed and utilized in numerous surgical specialties. This study aimed to evaluate the safety and feasibility of skin adhesives and to compare postoperative and cosmetic outcomes between skin adhesive and wound closure strip use for wound closure after subcuticular suturing in SPLA.

METHODS

Patients

The study group included 86 patients who underwent SPLA for acute appendicitis between August, 2014 and October, 2020 (Fig. 1). The following patients were excluded: (1) those diagnosed with a disease other than appendicitis after surgery, such as appendiceal mucocele, malignancies, etc. (n = 6); (2) those who underwent surgery for appendicitis with generalized peritonitis (n = 2); (3) those with a previous major laparotomy history such as gastrectomy (n = 1); (4) those treated with analgesics for chronic pain (n = 1); (5) those with co-morbidities including cardiopulmonary failure, liver failure or chronic kidney disease (n = 2); (6) pregnant women (n = 1); and (7) those with incomplete medical records (n = 4). A total of 22 patients in whom skin adhesive was used and 47 in whom steri-strips were used for skin closure after subcuticular suturing in SPLA were included in this study.

Evaluation parameters

Patient demographics, including age, sex, preoperative white

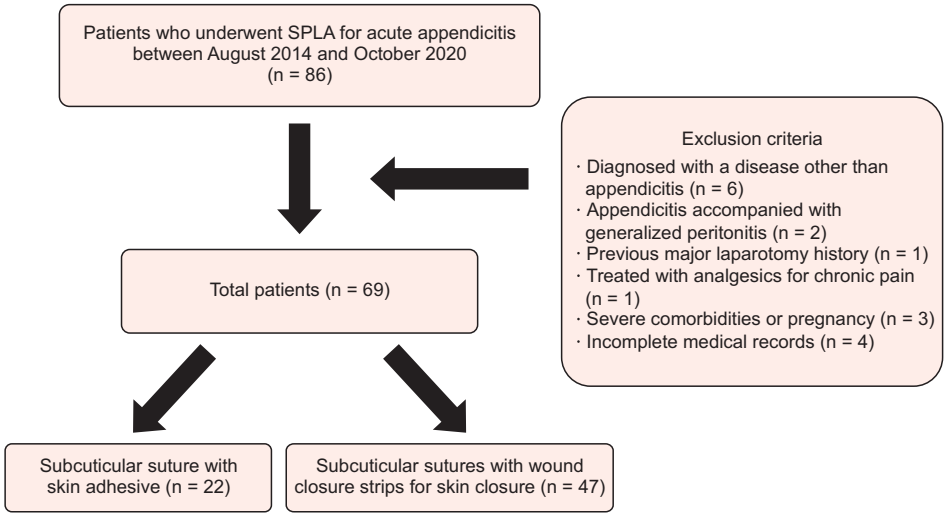

Fig. 1. Flowchart of patient selection. SPLA, single-port laparoscopic appendectomy.

blood cell and C-reactive protein levels, body mass index, and American Society of Anesthesiologists (ASA) grade were collected. The operation type, total operative time, appendicitis type, presence of periappendiceal abscess, diameter and length of the resected appendix, intraabdominal drainage, and total incision length were the operative surgical outcomes recorded. Postoperative outcomes assessed included the length of hospital stay, the numeric rating scale (NRS) pain score on postoperative days 0 and 1, total number and types of analgesics used within 24 hours and 24–48 hours after surgery, complications within 30 days, Clavien-Dindo classification, and postsurgical readmission rates. SSIs were categorized according to their severity; "superficial" infection if all four skin layers were affected, "deep" infection if deep soft tissue was affected, and "organ and body cavity" infection if organs and body cavities were also affected [25].

Surgical technique

Before induction of anesthesia, cefotetan (1.0 g) was administered intravenously as a prophylactic antibiotic. All surgeries were conducted under general anesthesia with the patient in the supine position. Subsequently, the patient was positioned upright at a 30° angle to the horizon, and the operating table was tilted 10°–15° to the lower right side. After abdominal disinfection with chlorhexidine, a single 2.0 cm vertical incision was made at the umbilicus. A single port was placed into the abdominal cavity through the umbilical incision, and the intraperitoneal space was secured by infusing up to 12 mmHg of CO_2. It was rinsed with normal saline, placed in a single-port sterile bag, and collected through the umbilical incision following appendectomy. After port removal, the umbilical muscle membrane was sutured with a 2-0 Vicryl (Covidien) suture, and subcuticular sutures were placed using a 4-0 Monosyn (B. Braun Aesculap AG & Co KG) cutting-needle suture. For the skin adhesive group, skin closure was achieved by breaking a capsule (Dermabond, Ethicon) and applying the bonding solution along the tip of the capsule to the wound site (Fig. 2). In the adhesive tape group, Steri-Strips (3M) was applied to the skin.

Patient scar assessment questionnaire

The patient scar assessment questionnaire (PSAQ) was utilized to determine patient satisfaction with the postoperative scar. It comprises four subitems: appearance, consciousness, satisfaction with appearance, and satisfaction with symptoms [26]. 'Appearance' included color, length, width, flatness, texture, brightness, and overall appearance of the scar. 'Consciousness' included itching, pain, discomfort, numbness, unusual sensations, and general symptoms at the surgery site. 'Satisfaction with appearance' determines how well the surgical site scar is visible to the patient and others and the general scar awareness level. 'Satisfaction with symptoms' evaluates the patient's satisfaction with the sensation, color, and overall appearance of the scar and its harmony with the surrounding skin. Each question was rated from 1 to 4 by the patient (1 point, the most favorable response; 4 points, the least favorable response). At 6 weeks postoperatively, patients completed the PSAQ at outpatient.

Statistical analysis

The results are reported as means and standard deviations for continuous variables and as frequencies and percentages for categorical variables. Categorical variables were examined using the chi-square test. Continuous variables were evaluated using independent *t* tests. Statistical significance was set at the *p*-value of <0.05. Statistical analysis was performed using IBM SPSS version 25 (IBM Corp.).

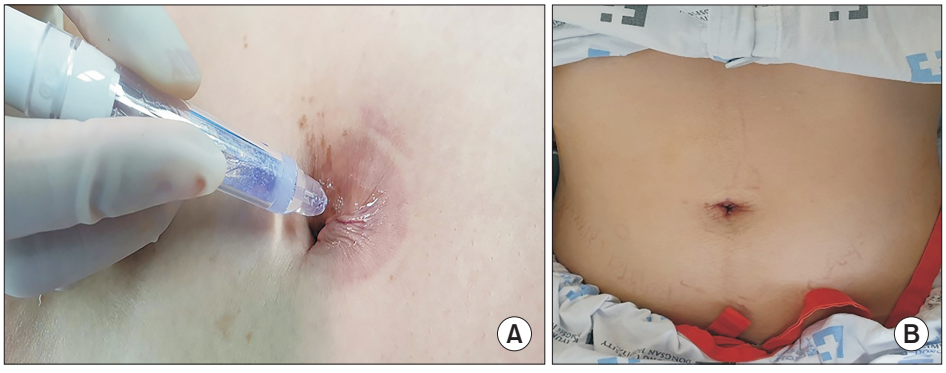

Fig. 2. (A) Application of skin adhesive to the incision after single-port laparoscopic appendectomy. (B) Clinical image of the scar on postoperative day one.

https://doi.org/10.7602/jmis.2024.27.1.14

RESULTS

Patient characteristics

The patient demographics are shown in Table 1. There were no statistically significant differences between the two groups in terms of sex, body mass index, age, preoperative white blood cell count, and C-reactive protein level. The proportion of patients with the ASA grade I in the skin adhesive group was significantly lower than that in the wound closure strip group (59% vs. 87%, $p = 0.013$).

Perioperative outcomes

The perioperative outcomes are shown in Table 2. The total operative time was significantly longer in the skin adhesive group than in the wound closure strip group (83.0 ± 36.9 minutes vs. 55.9 ± 21.8 minutes, $p = 0.003$). The appendicitis severity, periappendiceal abscess presences, diameter and length of the resected appendix, need for drain placement, and total incision length did not differ significantly between the two groups.

Table 1. Patient characteristics

Characteristic	Skin adhesive group	Wound closure strip group	*p*-value
No. of patients	22	47	
Age (yr)	46.4 ± 22.0	42.6 ± 14.3	0.473
Sex			0.934
Male	11 (50.0)	24 (51.1)	
Female	11 (50.0)	23 (48.9)	
Body mass index (kg/m^2)	23.2 ± 3.2	23.5 ± 3.4	0.788
Preoperative WBC (×10^3/μL)	9.4 ± 3.8	12.9 ± 5.2	0.090
Preoperative CRP (mg/dL)	2.0 ± 2.1	3.9 ± 5.6	0.065
ASA grade			0.013
I	13 (59)	41 (87.2)	
II	9 (41)	5 (10.6)	
III	0 (0)	1 (2.1)	

Values are presented as number only, mean ± standard deviation, or number (%).
CRP, C-reactive protein; WBC, white blood cell count; ASA, American Society of Anesthesiologists.

Table 2. Perioperative data of the two groups

Variable	Skin adhesive group (n = 22)	Wound closure strip group (n = 47)	*p*-value
Type of operations			0.728
SPLA	18 (81.8)	40 (85.1)	
SPLA + additional port	4 (18.2)	7 (14.9)	
Total operative time (min)	83.0 ± 36.9	55.9 ± 21.8	0.003
Appendicitis type			0.718
Suppurative	14 (63.6)	29 (61.7)	
Gangrenous	4 (18.2)	12 (25.5)	
Perforated	4 (18.2)	6 (12.8)	
Periappendiceal abscess	3 (13.6)	1 (2.1)	0.057
Diameter of resected appendix (mm)	12.8 ± 7.8	11.6 ± 3.5	0.487
Length of resected appendix (cm)	64.7 ± 20.9	66.6 ± 22.1	0.735
Drain placement	4 (18.2)	9 (19.1)	0.924
Length of incision (cm)	20.8 ± 2.7	20.0 ± 6.4	0.467

Values are presented as mean ± standard deviation or number (%).
SPLA, single-port laparoscopic appendectomy.

Postoperative outcomes

A comparison of the postoperative outcomes of the two groups is shown in Table 3. On postoperative day 0, patients in the skin adhesive group had significantly lower NRS scores than those in the wound closure strip group (2.8 ± 0.8 vs. 3.9 ± 0.8, $p < 0.001$). The number of times analgesics were administered within 24 hours of surgery was significantly lower in the skin adhesive group than in the wound closure strip group (1.4 ± 0.8 vs. 2.7 ± 1.2, $p = 0.013$). Opioid usage was significantly lower in the skin adhesive group than in the wound closure strip group (0.3 ± 0.5 vs. 0.9 ± 0.9, $p = 0.007$). There were no statistically significant differences in the nonsteroidal anti-inflammatory drugs (NSAIDs) usage (1.1 ± 0.8 vs. 1.2 ± 1.2, $p = 0.612$). The adhesive group used significantly fewer analgesics 24 to 48 hours after surgery than the wound closure strip group (0.2 ± 0.4 vs. 0.7 ± 0.9, $p = 0.002$). Opioids were used significantly less (0 vs. 0.3 ± 0.6, adhesive vs. steri-strip; $p = 0.002$) than NSAIDs (0.2 ± 0.4 vs. 0.5 ± 0.8, adhesive vs. steri-strip; $p = 0.033$). There was no statistically significant difference in the hospital stay length, NRS score on postoperative day one, and postsurgical readmission between the two groups. Table 4 provides detailed information on patients who developed SSIs. Among these, three cases involved superficial SSIs. One patient in the skin adhesive group received treatment with dressing changes, while two patients in the wound closure strip group were treated with both dressing changes and antibiotics.

Patient scar assessment questionnaire scores

Of the 69 patients, 13 and 42 in the skin adhesive and wound closure strip groups, respectively, were able to participate in a telephone survey. According to the patients' responses, a total of 28 questions were scored from 1 to 4, and the results are

Table 3. Comparison of postoperative outcomes between the two groups

Variable	Skin adhesive group (n = 22)	Wound closure strip group (n = 47)	*p*-value
Hospital stay (hr)	75.9 ± 103.3	62.1 ± 38.0	0.551
Numeric rating scale			
POD 0	2.8 ± 0.8	3.9 ± 0.8	<0.001
POD 1	3.4 ± 0.6	3.4 ± 1.2	0.877
Analgesic usage <4 hr	1.4 ± 0.8	2.7 ± 1.2	0.013
Opioids	0.3 ± 0.5	0.9 ± 0.9	0.007
NSAIDs	1.1 ± 0.8	1.2 ± 1.2	0.612
Analgesics usage 24–48 hr	0.2 ± 0.4	0.7 ± 0.9	0.002
Opioids	0 (0)	0.3 ± 0.6	0.002
NSAIDs	0.2 ± 0.4	0.5 ± 0.8	0.033
Complications within 30 days of surgery	5 (14.3)	5 (14.7)	0.960
Surgical site infection	1 (4.5)	2 (4.3)	0.956
Clavien-Dindo classification			0.215
I	1 (4.5)	0 (0)	
≥II	0 (0)	2 (4.3)	
Readmission after surgery	0 (0)	2 (4.3)	0.326

Values are presented as mean ± standard deviation or number (%).
POD, postoperative day.

Table 4. Clinical data of the patients with SSI

Case No.	Age (yr)	Sex	Closure method	Appendicitis type	SSI classification	Treatment
Case 1	43	Female	Skin adhesive	Suppurative	Superficial	Dressing
Case 2	60	Male	Subcuticular suture	Suppurative	Superficial	Antibiotics, dressing
Case 3	40	Female	Subcuticular suture	Suppurative	Superficial	Antibiotics, dressing

SSI, surgical site infection.

https://doi.org/10.7602/jmis.2024.27.1.14

Table 5. Comparison of patient scar assessment questionnaire scores between the two groups

Variable	Skin adhesive group (n = 13)	Wound closure strip group (n = 42)	*p*-value
Total	38.8 ± 9.2	49.4 ± 15.1	0.020
Appearance	13.7 ± 3.5	15.7 ± 4.6	0.159
Consciousness	7.3 ± 2.4	9.1 ± 4.2	0.151
Satisfaction with appearance	11.3 ± 3.0	15.1 ± 4.5	0.006
Satisfaction with symptoms	6.5 ± 1.8	9.5 ± 3.3	0.003

Values are presented as mean ± standard deviation.

displayed in Table 5. Total PSAQ scores were lower in the skin adhesive group compared to the wound closure strip group (38.8 ± 9.2 vs. 49.4 ± 15.1, $p = 0.020$). Subitems including 'Satisfaction with appearance' and 'Satisfaction with symptoms' were significantly lower in patients who underwent skin closure with skin adhesive (11.3 ± 3.0 vs. 15.1 ± 4.5, $p = 0.006$ and 6.5 ± 1.8 vs. 9.5 ± 3.3, $p = 0.003$), whereas 'Appearance' and 'Consciousness' subitems revealed no statistically significant differences between groups ($p = 0.159$ and $p = 0.151$, respectively).

DISCUSSION

Our study is the first to report the feasibility and safety of using adhesive agents as opposed to a wound closure strip for skin closure in patients with SPLA and acute appendicitis. The pain score on the day of surgery and the number of analgesics taken within 48 hours after surgery were significantly lower in the skin adhesive group than in the wound closure strip group. In particular, it was possible to significantly reduce the amount of opioids used in skin adhesives. The incidence rates of SSI did not differ significantly between the two groups, and only one patient in the skin adhesive group developed mild SSI. There was no difference in the appearance and consciousness questionnaires between the two groups; however, the skin adhesive group was cosmetically superior to the wound closure strip group in terms of cosmetic satisfaction.

SSI is an important safety indicator in relation to the skin closure method [27]. In a study comparing skin adhesive and subcuticular suture for maxillofacial incision, the incidence of postoperative infection with skin adhesive was one patient (7.69%), which did not differ significantly from that with the conventional suture method [28]. A randomized controlled trial comparing the suture method using skin adhesive and wound closure strip after cesarean section reported a wound infection rate of 7.6% in the patient group using skin adhesive and 7.9% in the patient group using wound closure strip [29]. Another study involving colorectal surgery found that the skin adhesive group had a significantly lower incidence of superficial SSI, with no patients in the skin adhesive group and five patients (2.4%) in the skin staple group [19]. In studies on acute appendicitis, St Peter et al. [30] reported wound infection rates of 3.3% and 1.7% for single-port and multiport laparoscopic appendectomies, respectively, and Jin et al. [31] also reported wound complications in 8.7% of cases in the single-port method compared to 5.6% in the conventional method. In the present study, the incidence of SSI was 4.5% in the skin adhesive group, and there were no significant differences between the wound closure strip and the skin adhesive groups. These findings demonstrate the safety of skin adhesives in SPLA for appendicitis. However, in diseases with severe inflammation, such as perforated appendicitis, skin adhesives should be used with caution and further research is required.

Postoperative discomfort may vary based on the suture technique used to close the surgical incision. In a study comparing the pain caused by a skin adhesive, a stapler, and a simple suture after surgery, the group of patients using a skin adhesive demonstrated statistically significantly lower pain scores at 12, 24, 48, and 72 hours after surgery compared to the other skin closure methods [32]. In a prospective randomized study comparing traditional sutures and skin adhesives for the repair of first-degree peripheral tears, the skin adhesive group had a considerably lower pain score and a shorter time to become pain-free [33]. In the current study, the skin adhesive group demonstrated a significantly lower pain score on the day of surgery and decreased use of analgesics, including opioids and NSAIDs, within 48 hours after surgery, when compared to the wound closure strip group. The improvement in pain cannot be attributed solely to the skin adhesive; however, it can be inferred that this is because the skin adhesive applies more tension to the suture site than the steri-strips and can alleviate the pain of the subcuticular suture on the skin.

Cosmesis is increasingly regarded as a significant surgical

outcome measure, in addition to functional outcomes and quality of life. The postoperative scarring and discomfort at the incision site are closely related to the quality of life after thyroidectomy, appendectomy, and colon resection, and body image—a person's impression of, satisfaction with, and attitude towards his or her own body—has been thoroughly studied [34–37]. Some studies have demonstrated that patients who underwent SPLA, rather than MPLA, achieved superior cosmetic outcomes [38,39]. However, to date, there has been no research comparing the suture method using skin adhesives to other suture methods after SPLA. A randomized controlled trial on skin closure after robotic urogynecologic procedures revealed that the skin adhesive group using cyanoacrylate agents received higher cosmesis ratings than the suture group [40]. In our study, the skin adhesive group demonstrated significantly better PSAQ outcomes than the wound closure strip group in terms of satisfaction with the scar's appearance and symptoms as well as the total PSAQ score, although there was no difference between the two groups in terms of appearance and consciousness. We believe that these results were the result of a high level of satisfaction after the application of the skin adhesive, such as less pain and water resistance, which allowed patients to shower after surgery, in addition to the satisfaction of cosmesis.

Our research is limited by its retrospective design, small sample size, single-center design, and lack of long-term cosmetic outcomes. In addition, the PSAQ relies on the subjective thoughts of the patient. A multicenter randomized prospective study comparing SSI, cosmetic outcomes, and pain assessments using more objective parameters between SPLA and MPLA is needed. In conclusion, this study demonstrated that liquid skin adhesive closures were safe and feasible and caused less postoperative pain, resulting in greater patient satisfaction with postoperative scars than wound closure strip closure after subcuticular suture in SPLA.

Notes

Ethical statement

The current study was performed in accordance with the Declaration of Helsinki and approved by the Institutional Review Board of Keimyung University Dongsan Medical Center (No. DSMC 2022-10-036). Written consent was obtained from patients prior to any study-specific screening procedures.

Authors' contributions

Conceptualization, Data curation, Formal analysis, Methodology: KEK, RJY, SUB
Writing–original draft: KEK, RJY, SUB
Writing–review & editing: WKJ, SKB
All authors read and approved the final manuscript.

Conflict of interest

All authors have no conflicts of interest to declare.

Funding/support

None.

Data availability

The data presented in this study are available upon reasonable request to the corresponding author.

ORCID

Kyeong Eui Kim, https://orcid.org/0000-0001-9984-9976
Sung Uk Bae, https://orcid.org/0000-0002-7876-4196
Woon Kyung Jeong, https://orcid.org/0000-0001-8421-218X
Seong Kyu Baek, https://orcid.org/0000-0001-6427-8675

REFERENCES

1. Bae SU, Yang CS, Kim S, et al. Long-term oncologic outcomes of laparoscopic versus open resection following stent insertion for obstructing colon cancer: a multi-center retrospective study. Surg Endosc 2019;33:3937-3944.
2. Bae SU, Saklani AP, Lim DR, et al. Laparoscopic-assisted versus open complete mesocolic excision and central vascular ligation for right-sided colon cancer. Ann Surg Oncol 2014;21:2288-2294.
3. Kim WJ, Jin HY, Lee H, et al. Comparing the postoperative outcomes of single-incision laparoscopic appendectomy and three port appendectomy with enhanced recovery after surgery protocol for acute appendicitis: a propensity score matching analysis. Ann Coloproctol 2021;37:232-238.
4. Semm K. Endoscopic appendectomy. Endoscopy 1983;15:59-64.
5. Yu MC, Feng YJ, Wang W, Fan W, Cheng HT, Xu J. Is laparoscopic appendectomy feasible for complicated appendicitis ?A systematic review and meta-analysis. Int J Surg 2017;40:187-197.
6. Mentula P, Sammalkorpi H, Leppäniemi A. Laparoscopic

surgery or conservative treatment for appendiceal abscess in adults? A randomized controlled trial. Ann Surg 2015;262:237-242.
7. Bae SU, Jeong WK, Baek SK. Single-port laparoscopic interval appendectomy for perforated appendicitis with a periappendiceal abscess. Ann Coloproctol 2016;32:105-110.
8. Kang SM, Cho JR, Oh HK, et al. Safety and efficacy of single-port laparoscopic ileostomy in palliative settings. Ann Coloproctol 2020;36:17-21.
9. Yang IJ, Seo M, Oh HK, et al. Surgical outcomes of single-port laparoscopic surgery compared with conventional laparoscopic surgery for appendiceal mucinous neoplasm. Ann Coloproctol 2021;37:239-243.
10. Kang BM, Kim CW, Lee SH. Laparoscopic Hartmann's reversal: application of a single-port approach through the colostomy site. Ann Coloproctol 2021;37:29-34.
11. Esposito C. One-trocar appendectomy in pediatric surgery. Surg Endosc 1998;12:177-178.
12. Frutos MD, Abrisqueta J, Lujan J, Abellan I, Parrilla P. Randomized prospective study to compare laparoscopic appendectomy versus umbilical single-incision appendectomy. Ann Surg 2013;257:413-418.
13. Zaman S, Mohamedahmed AYY, Srinivasan A, et al. Single-port laparoscopic appendicectomy versus conventional three-port approach for acute appendicitis: a systematic review, meta-analysis and trial sequential analysis of randomised controlled trials. Surgeon 2021;19:365-379.
14. Aly OE, Black DH, Rehman H, Ahmed I. Single incision laparoscopic appendicectomy versus conventional three-port laparoscopic appendicectomy: a systematic review and meta-analysis. Int J Surg 2016;35:120-128.
15. Singer AJ, Quinn JV, Hollander JE. The cyanoacrylate topical skin adhesives. Am J Emerg Med 2008;26:490-496.
16. Patel SV, Paskar DD, Nelson RL, Vedula SS, Steele SR. Closure methods for laparotomy incisions for preventing incisional hernias and other wound complications. Cochrane Database Syst Rev 2017;11:CD005661.
17. Huda F, Gajula B, Singh S, Kumar S, Lokavarapu MJ, Sowmya D. Staples versus sutures for skin closure in standard four port laparoscopic cholecystectomy: a prospective cohort study. Cureus 2021;13:e13725.
18. Romero P, Frongia G, Wingerter S, Holland-Cunz S. Prospective, randomized, controlled trial comparing a tissue adhesive (Dermabond™) with adhesive strips (Steri-Strips™) for the closure of laparoscopic trocar wounds in children. Eur J Pediatr Surg 2011;21:159-162.
19. Lee CS, Han SR, Kye BH, et al. Surgical skin adhesive bond is safe and feasible wound closure method to reduce surgical site infection following minimally invasive colorectal cancer surgery. Ann Surg Treat Res 2020;99:146-152.
20. Kwon JY, Yun HG, Park IY. n-Butyl-2-cyanoacrylate tissue adhesive (Histoacryl) vs. subcuticular sutures for skin closure of Pfannenstiel incisions following cesarean delivery. PLoS One 2018;13:e0202074.
21. Koonce SL, Eck DL, Shaddix KK, Perdikis G. A prospective randomized controlled trial comparing N-butyl-2 cyanoacrylate (Histoacryl), octyl cyanoacrylate (Dermabond), and subcuticular suture for closure of surgical incisions. Ann Plast Surg 2015;74:107-110.
22. Kent A, Liversedge N, Dobbins B, McWhinnie D, Jan H. A prospective, randomized, controlled, double-masked, multi-center clinical trial of medical adhesives for the closure of laparoscopic incisions. J Minim Invasive Gynecol 2014;21:252-258.
23. Buchweitz O, Frye C, Moeller CP, et al. Cosmetic outcome of skin adhesives versus transcutaneous sutures in laparoscopic port-site wounds: a prospective randomized controlled trial. Surg Endosc 2016;30:2326-2331.
24. Yang YL, Xiang YY, Jin LP, et al. Closure of skin incision after thyroidectomy through a supraclavicular approach: a comparison between tissue adhesive and staples. Scand J Surg 2013;102:234-240.
25. Alkaaki A, Al-Radi OO, Khoja A, et al. Surgical site infection following abdominal surgery: a prospective cohort study. Can J Surg 2019;62:111-117.
26. Durani P, McGrouther DA, Ferguson MW. The Patient Scar Assessment Questionnaire: a reliable and valid patient-reported outcomes measure for linear scars. Plast Reconstr Surg 2009;123:1481-1489.
27. Ku DH, Kim HS, Shin JY. Short-term and medium-term outcomes of low midline and low transverse incisions in laparoscopic rectal cancer surgery. Ann Coloproctol 2020;36:304-310.
28. Soni A, Narula R, Kumar A, Parmar M, Sahore M, Chandel M. Comparing cyanoacrylate tissue adhesive and conventional subcuticular skin sutures for maxillofacial incisions: a prospective randomized trial considering closure time, wound morbidity, and cosmetic outcome. J Oral Maxillofac Surg 2013;71:2152.
29. Braginsky L, Javellana M, Cleveland E, et al. Tissue adhesive compared with sterile strips after cesarean delivery: a

randomized controlled trial. Obstet Gynecol 2019;134:295-301.

30. St Peter SD, Adibe OO, Juang D, et al. Single incision versus standard 3-port laparoscopic appendectomy: a prospective randomized trial. Ann Surg 2011;254:586-590.
31. Jin SG, Cho SH, Kim KY, et al. Transumbilical single-incision laparoscopic-assisted appendectomy (TULAA) is useful in adults and young adolescents: comparison with multi-port laparoscopic appendectomy. Medicina (Kaunas) 2019;55:248.
32. Andana BB, Vikram J, Ramesh BS, Khan HM. A comparative study between conventional skin sutures, staples adhesive skin glue for surgical skin closure. Int Surg J 2019;6:775-782.
33. Dasrilsyah RA, Kalok A, Ng BK, Ali A, Teik Chew K, Lim PS. Perineal skin tear repair following vaginal birth: skin adhesive versus conventional suture. A randomised controlled trial. J Obstet Gynaecol 2021;41:242-247.
34. Koo DH, Kim DM, Choi JY, Lee KE, Cho SH, Youn YK. In-depth survey of scarring and distress in patients undergoing bilateral axillo-breast approach robotic thyroidectomy or conventional open thyroidectomy. Surg Laparosc Endosc Percutan Tech 2015;25:436-439.
35. Lee KH, Kim EY, Park CH, Park YL, Yun JS, Lee GY. Assessing cosmetic results after conventional thyroidectomy using the EASY-EYE_C: a double-blind randomized controlled trial. Ann Surg Treat Res 2017;93:231-239.
36. Bae SU, Jegon WK, Baek SK. Single plus one-port robotic surgery using the da Vinci Single-Site Platform versus conventional multi-port laparoscopic surgery for left-sided colon cancer. Wideochir Inne Tech Maloinwazyjne 2022;17:179-187.
37. Gasior AC, Knott EM, Holcomb GW, Ostlie DJ, St Peter SD. Patient and parental scar assessment after single incision versus standard 3-port laparoscopic appendectomy: long-term follow-up from a prospective randomized trial. J Pediatr Surg 2014;49:120-122.
38. Carter JT, Kaplan JA, Nguyen JN, Lin MY, Rogers SJ, Harris HW. A prospective, randomized controlled trial of single-incision laparoscopic vs conventional 3-port laparoscopic appendectomy for treatment of acute appendicitis. J Am Coll Surg 2014;218:950-959.
39. Jategaonkar PA, Yadav SP. Single site multiport umbilical laparoscopic appendicectomy versus conventional multiport laparoscopic appendicectomy in acute settings. Ann R Coll Surg Engl 2014;96:452-457.
40. Fluellen S, Mackey K, Hagglund K, Aslam MF. Randomized clinical trial comparing skin closure with tissue adhesives vs subcuticular suture after robotic urogynecologic procedures. World J Methodol 2020;10:1-6.

https://doi.org/10.7602/jmis.2024.27.1.14