



Long-term Recovery Patterns of Olfactory Function after Trans-sphenoidal Approach with Nasoseptal Flap Elevation

Bon Min Koo¹ Jong In Jeong¹

¹Department of Otolaryngology, Keimyung University School of Medicine, Dongsan Hospital, Daegu, Republic of Korea

Int Arch Otorhinolaryngol 2023;27(4):e699–e705.

Address for correspondence Jong In Jeong, Department of Otolaryngology, Keimyung University School of Medicine, Dongsan Hospital, 1035, Dalgubeol-daero, Dalseo-gu, Daegu, 42601, Republic of Korea (e-mail: hydeath1@nate.com).

Abstract

Introduction Nasoseptal flap is widely used in reconstruction of the skull base to prevent cerebrospinal fluid leakage after surgery for skull base lesions. There has been a debate on whether more severe olfactory dysfunction occurs after nasoseptal flap elevation than the conventional trans-sphenoidal approach.

Objective To compare the long-term recovery patterns associated with nasoseptal flap and the conventional trans-sphenoidal approach.

Methods The subjects were divided into the conventional trans-sphenoidal approach group and the nasoseptal flap elevation group. We followed up self-reported olfactory score using the visual analogue scale and threshold discrimination identification (TDI) score of the Korean Version of the Sniffin Stick test II for 12 months, with olfactory training.

Results The study included 31 patients who underwent the trans-sphenoidal approach. Compared with preoperative status, the mean visual analogue scale and TDI scores in the conventional trans-sphenoidal approach group recovered 2 months postoperatively, while in the nasoseptal flap elevation group the visual analogue scale and TDI scores recovered 6 months and 3 months after surgery, respectively. Twelve months after surgery, the visual analogue scale and TDI scores in the conventional trans-sphenoidal approach group were 9.3 ± 0.5 and 28.5 ± 4.3 , while those from the nasoseptal flap elevation group were 8.9 ± 1.5 and 27.2 ± 4.7 ($p = 0.326$; 0.473). Only one of the patients in the nasoseptal flap elevation group had permanent olfactory dysfunction.

Conclusion The olfactory function recovered more gradually in the nasoseptal flap elevation group than in the conventional trans-sphenoidal approach group, but there was no difference between the two groups after 6 months.

Keywords

- ▶ trans-sphenoidal approach
- ▶ nasal septal flap elevation
- ▶ pituitary adenoma
- ▶ olfactory function

received
May 20, 2022
accepted after revision
September 4, 2022

DOI <https://doi.org/10.1055/s-0043-1761168>.
ISSN 1809-9777.

© 2023. Fundação Otorrinolaringologia. All rights reserved.
This is an open access article published by Thieme under the terms of the Creative Commons Attribution-NonDerivative-NonCommercial-License, permitting copying and reproduction so long as the original work is given appropriate credit. Contents may not be used for commercial purposes, or adapted, remixed, transformed or built upon. (<https://creativecommons.org/licenses/by-nc-nd/4.0/>)
Thieme Revinter Publicações Ltda., Rua do Matoso 170, Rio de Janeiro, RJ, CEP 20270-135, Brazil

Introduction

With recent developments in endoscopic surgical techniques, the trans-sphenoidal approach (TSA) has been applied to a wide range of cranial lesions. The TSA allows a broader application, from sellar lesions to anterior cranial fossa and infratemporal fossa, in addition to the treatment not only of benign tumors, such as pituitary adenoma, meningioma, and craniopharyngioma, but also malignant tumors such as chordoma.¹

As the prevention of cerebrospinal fluid leaks in the pituitary gland is essential following surgery of large lesions at the base of the skull, reconstruction procedures have been developed along with endoscopic surgical techniques. Various methods using autologous tissue and synthetic materials to reconstruct skull base defects have been proposed, among which the nasoseptal flap (NSF), which can be used in the same endoscopic procedure, has been gaining recognition.² As observed in many studies reporting successful reconstructions of large skull base defects, the NSF has the advantage of a rich vascular distribution and a large mucosal area, making it suitable for treating large skull base defects. Nonetheless, because of the extensive damage inflicted on the donor site, symptoms such as nasal congestion, dryness, and olfactory dysfunction following the surgery have been frequently reported.³ In particular, there have been several studies comparing the incidence or severity of postoperative olfactory dysfunction, an important factor in the quality of life, between NSF and conventional skull base surgery.^{3,4}

Our previous study reported that compared with the conventional TSA, a TSA accompanied by NSF elevation demonstrated a more gradual short-term recovery pattern.⁵ In the present study, the long-term recovery patterns of the two procedures were compared.

Methods

Study Design and Subjects

We retrospectively analyzed the medical records of 35 patients who underwent surgery involving the TSA in the OO Medical Center from March 2016 to July 2017. To exclude olfactory dysfunction caused by the lesion itself, the patients who underwent trans-sphenoidal surgery for lesions within the sellar region were included. The self-reporting olfaction score was defined as indicated on a 10-cm visual analog scale (VAS), with 0 as no olfaction and 10 as the most sensitive level of olfaction without discomfort. Patients who did not complain of a reduced sense of smell at the outpatient clinic prior to surgery and whose self-reported olfactory score was greater than or equal to 7 were included in the study.

Patients with a history of chronic rhinosinusitis diagnosed by an otolaryngologist prior to the surgery, patients with a history of nasal surgery, patients who had previously received a diagnosis of impaired olfaction, patients with a history of head trauma or brain surgery, patients with a history of degenerative neurologic disorders diagnosed with imaging studies, and patients with facial deformities were excluded. Patients with severe systemic diseases such as

cirrhosis and heart failure, which may affect the sense of smell, were also excluded.

Magnetic resonance imaging (MRI) scans of the recruited patients were taken in the neurosurgery clinic to determine the size and location of the sellar lesions. They were then referred to the otolaryngology clinic to check for intranasal lesions through nasal endoscopy. Once the absence of intranasal lesions was confirmed, a computed tomography (CT) scan of the sinuses was performed to confirm the absence of nasal sinus lesions.

Olfactory function was evaluated using the Korean Version of the Sniffin Stick Test II (KVSS II) and the self-reported olfactory score with VAS. The threshold discrimination identification (TDI) score of KVSS II was determined by adding each of the test scores. The baseline olfactory function of all patients with TDI and VAS scores was evaluated before surgery. The TDI scores were followed up 1, 2, 3, 6, and 12 months after surgery. The VAS scores were obtained immediately following the removal of the silicon plates from the nasal septum 2 weeks after surgery, as well as 1, 2, 3, 6, and 12 months after surgery. The Institutional Review Board of OO approved this study (IRB No. 2020-12-0111-002). Individual consent for the study was waived.

Out of the 35 patients recruited, 31 were analyzed upon exclusion of 4 patients, who either did not follow-up or acquired a new disease. The patients were divided into two groups: one that underwent trans-sphenoidal surgery using conventional TSA and another in which NSF elevation was performed. The methods used in each procedure were as follows:⁵

1. Trans-sphenoidal approach

The nasal cavity was approached via the right side of the septum. An incision was made in the mucous membrane 5 mm posterior to the caudal end, then extended to the nasal floor. Upon identification of the mucous cartilage membrane, a small space was made, followed by an anterior tunnel made by exfoliation using an endoscope. The anterior tunnel was then connected to the inferior tunnel where the mucous membrane and bone were detached. The detachment was continued posteriorly along the surface, identifying the vertical plate and vomer, until the sphenoidal rostrum, and then superiorly to identify the sphenoid sinus ostia. After separating the connection between the nasal septal cartilage and the vertical plate-vomer, the vertical plate of the ethmoid bone and the mucous membrane of the vomer were detached posteriorly. Once the rostrum sphenoidale was identified on both sides following the detachment of the vertical plate of the ethmoid bone, the sphenoid sinus was opened wide using a rongeur, osteotome, or drill. Finally, a modified Papavero-Caspar speculum was mounted on the anterior wall of the sphenoid sinus, and surgery was performed by the neurosurgery department using microscopy.

2. Nasoseptal flap elevation

Upon identification of the sphenoid sinus ostia via TSA, an incision was made on the inferior edge of the ostium, along

the NSF up to the upper third of the anterior middle turbinate. Here, the posterior superior olfactory epithelium was preserved as much as possible. The nasoseptal mucous membrane was separated from the nasal septum by connecting it with the incision line on the anterior nasal septum, then placed in the choana. Then, as in the TSA, the rostrum sphenoidale was removed, the modified Papavero-Caspar speculum was mounted, and surgery was performed by the neurosurgery department using microscopy. In the case of defect reconstruction using an NSF following the neurosurgical procedure, the flap was incised with caution to prevent damage to the blood vessels within the flap. The flap was detached and then rotated into the defect for reconstruction. If the NSF was not used for reconstruction, the flap was placed back into its original position, followed by a quilting suture.

Postoperative olfactory dysfunction was defined as a decrease > 6 points in TDI scores after surgery⁶ compared with the baseline TDI score.

In the postoperative outpatient follow-up, massive nasal dressings were administered at weekly intervals for 2 months after surgery to normalize the nasal mucosa from persisting heavy crust, synechia, or granulation. Synechiolysis, silicone plate insertion, or triamcinolone instillation were performed. Patients used saline irrigation twice a day and intranasal corticosteroid spray once a day.

Statistical Analysis

Statistical analysis was performed using SAS software version 9.4 (SAS Institute, Cary, NC, USA). Analysis of the demographic characteristics of the conventional TSA and NSF elevation groups was performed using the Wilcoxon rank sum test and the Fisher exact test. Changes in the VAS and TDI scores in each group were analyzed using the Wilcoxon signed-rank test. To identify the factors influencing the changes in VAS and TDI scores after surgery, multiple linear regression analysis was used to adjust for potential confounders (such as age, sex, surgical methods, lesion size, lesion pathology, and preoperative olfactory function). The results were summarized as correlation coefficients, with *p*-values provided. Given the possibility of colinear relationship among the parameters, we examined variation inflation

factors (VIF). There was no multicollinearity within the regression model ($VIF < 10$). All reported *p*-values are two-sided, with a *p*-value < 0.05 being considered statistically significant.

Results

The mean age of all 31 subjects was 43.1 ± 14.8 years old, compared with the mean age of 45.2 ± 5.7 years old in the TSA group and 40.5 ± 15.5 years old in the NSF elevation group, indicating no significant difference between the groups ($p = 0.154$). Likewise, there were no significant differences in sex, with 14 men and 17 women in total, 8 men and 9 women in the conventional TSA group, and 6 men and 8 women in the NSF elevation group ($p = 0.830$). There was no significant difference in smoking history, with 2 smokers in the conventional TSA group and 3 smokers in the NSF elevation group ($p = 1.000$). The average preoperative lesion size, measured by MRI, was 21.7 ± 5.7 mm, with an average lesion size of 21.0 ± 3.0 mm in the conventional TSA group and 24.5 ± 6.1 mm in the NSF elevation group, indicating no significant difference between the two groups ($p = 0.226$). Pathological findings from postoperative biopsies indicated 23 cases of pituitary adenoma and 8 cases of Rathke cleft cyst in total, with 12 cases of pituitary adenoma and 5 cases of Rathke cleft cyst in the conventional TSA group, and 11 cases of pituitary adenoma and 3 cases of Rathke cleft cyst in the NSF elevation group, indicating no significant difference between the 2 groups ($p = 0.560$) (► **Table 1**). There were no indications of complications requiring reoperation or postoperative treatment, such as cerebrospinal fluid leakage or meningitis, in either group.

The mean preoperative self-reported VAS score in the conventional TSA group was 9.5 ± 0.5 . The scores decreased significantly to 6.2 ± 0.6 until 1 month after surgery ($p = 0.039$) and recovered to 8.9 ± 1.6 by 2 months after surgery. Thereafter, the VAS scores were not significantly different from the preoperative scores ($p = 0.108$; $p = 0.213$; $p = 0.196$; and $p = 0.195$). In the NSF elevation group, the mean preoperative VAS score was 9.2 ± 2.0 and decreased significantly until 3 months after surgery (7.2 ± 0.4 ; $p = 0.046$). The score of the NSF elevation group recovered

Table 1 Demographic characteristics and possible risk factors of olfactory dysfunction of the conventional trans-sphenoidal approach group and the nasoseptal flap elevation group

	Total	Trans-septal app	NSF elevation	<i>p</i> -value
Number	31	17	14	
Age (years old)	43.1 ± 3.1	14.2 ± 5.7	40.5 ± 15.5	0.1541
Gender (male:female)	14:17	8:9	6:8	0.8302
Smoker	5	2	3	1.0000
Tumor size (mm)	21.7 ± 1.7	20.1 ± 0.1	24.5 ± 4.5	0.2256
Tumor pathology				
Pituitary adenoma	23	12	11	0.5604
Rathke cleft cyst	8	5	3	

Abbreviation: NSF, nasoseptal flap.

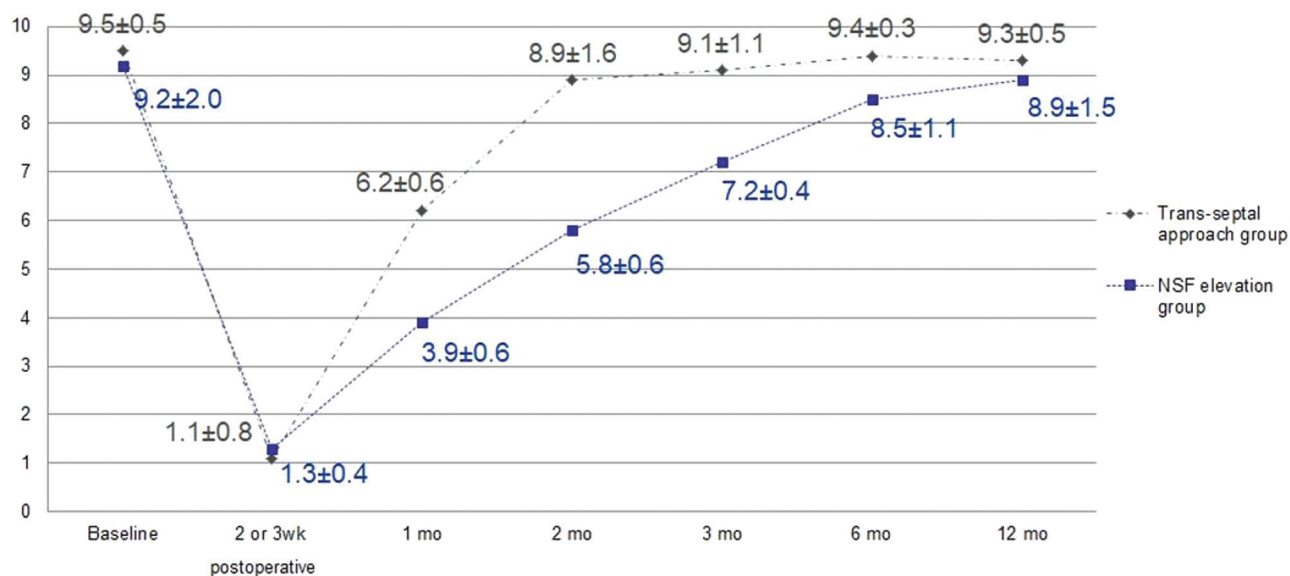


Fig. 1 Visual analog scale (VAS) scores of conventional trans-sphenoidal approach (TSA) group and nasoseptal flap (NSF) elevation group.

to 8.5 ± 1.1 by 6 months after surgery, and there was no significant difference with preoperative scores ($p = 0.248$). Comparing the 2 groups, the NSF elevation group demonstrated significantly lower scores ($p = 0.028$; $p = 0.016$; and $p = 0.031$) at 1, 2, and 3 months after surgery but did not demonstrate statistically significant differences at 6 or 12 months after surgery ($p = 0.187$; $p = 0.205$) (► **Fig. 1**).

The mean preoperative TDI score in the conventional TSA group was 28.3 ± 3.2 . The scores decreased significantly to 12.1 ± 0.8 until 1 month after surgery ($p = 0.024$) and recovered to 25.4 ± 6.3 by 2 months after surgery. The TDI scores after that were not significantly different from the preoperative scores ($p = 0.284$; $p = 0.323$; $p = 0.311$; and $p = 0.295$). In the NSF elevation group, the mean preoperative TDI score was 27.7 ± 5.9 and decreased significantly until 2 months after surgery (19.7 ± 3.9 ; $p = 0.041$). The score of the NSF

elevation group recovered to 24.1 ± 5.4 by 3 months after surgery, and there was no significant difference from preoperative scores ($p = 0.068$). Comparing the two groups, the NSF elevation group demonstrated significantly lower scores at 2 and 3 months after surgery ($p = 0.024$; $p = 0.035$) but did not demonstrate statistically significant differences at 6 or 12 months after surgery ($p = 0.398$; $p = 0.315$) (► **Fig. 2**).

The NSF elevation group demonstrated a significantly higher number of patients with olfactory dysfunction until 2 months after surgery compared with the TSA group ($p = 0.008$). Ten out of 14 patients demonstrated olfactory dysfunction 2 months after surgery. According to the endoscopic exam during postoperative follow-up at the outpatient clinic, crusting of exposed cartilage and bone tissue remained in 10 patients, for whom nasal dressing was continuously administered for 4 to 8 weeks. Granulomatous

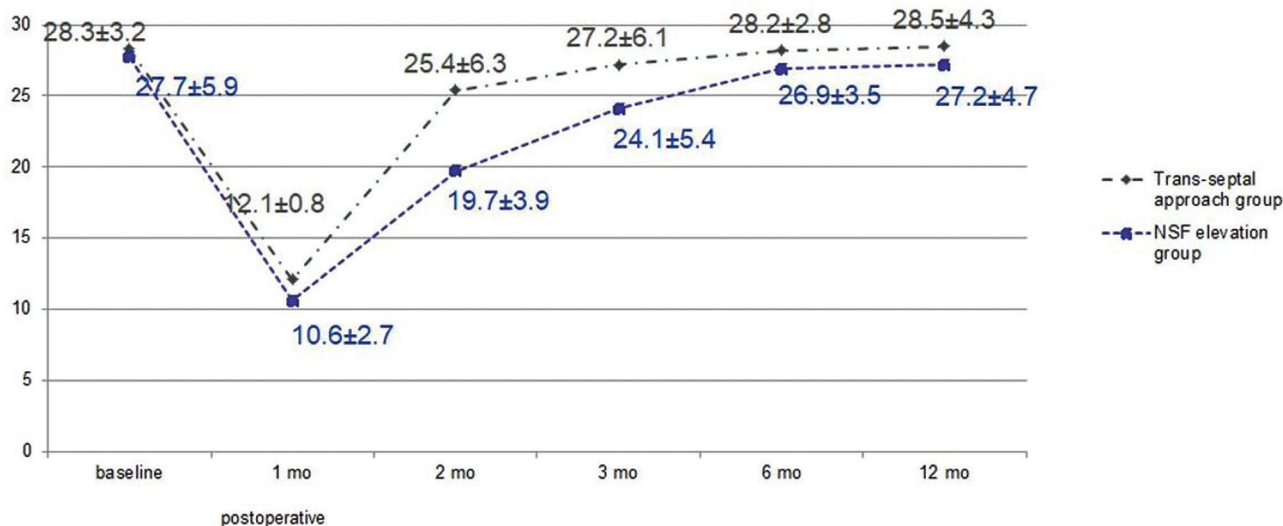


Fig. 2 Threshold, discrimination, identification (TDI) score of the Korean version of Sniffin' stick test II (KVSS II) of the conventional TSA group and NSF elevation group.

Table 2 Results of the interventions in olfactory dysfunction of the NSF group

	Baseline TDI	POD 2mo TDI	Intervention	POD 12mo TDI
Case 1	29	22	ND 4wks	30
Case 2	27	19	ND 3wks, TA #1	25
Case 3	26	19	ND 8wks, SN #1	27
Case 4	27	21	ND 6wks	28
Case 5	25	19	ND 2wks	25
Case 6	31	23	ND 8wks, TA #1, SN #1	27
Case 7	28	20	ND 4wks	2
Case 8	25	19	ND 6wks, TA #1	18
Case 9	30	20	ND 3wks	31
Case 10	22	14	ND 8wks, SN #1	24

Abbreviations: ND, nasal dressing; SN, synechiolysis; TA, triamcinolone application; TDI, threshold discrimination identification.

findings were detected in three patients, and local triamcinolone application was performed on them. Adhesion of nasal mucosa between the nasal septum and the middle turbinate occurred in three patients, who received synechiolysis and silicone plate insertion for 2 weeks. After these procedures, 9 out of the 10 patients demonstrated recovered olfactory functions, indicating no significant difference in the prevalence of permanent olfactory dysfunction between the two groups ($p = 0.469$) (► **Table 2**).

Multiple linear regression analysis adjusted for age, sex, smoking history, lesion size, and lesion pathology was performed to analyze factors that influenced the observed transient olfactory dysfunction. Even with adjusted values for age, sex, smoking history, lesion size, and lesion pathology, the NSF elevation group was still significantly associated with low self-reported VAS and TDI scores at 2 and 3 months after surgery (► **Table 3**).

Discussion

Although craniotomy has been a long-time standard for the surgical treatment of skull base lesions, endoscopic skull base surgery has been recently gaining recognition as an excellent alternative for appropriate candidates.^{1,7} The main complications of skull base surgery are cerebrospinal fluid leakage, cranial nerve dysfunction, vision abnormalities, olfactory dysfunction, and diabetes insipidus. It has been

reported that endoscopic skull base surgery carries a lower risk of such complications compared with open craniotomy, with similar postoperative mortality rates in gross total resection. Thus, endoscopic skull base surgery has been emerging as a safe alternative.⁸ Nonetheless, cerebrospinal fluid leakage, a common cause of meningitis, abscess, and encephalopathy, has been frequently reported in endoscopic skull base surgery.^{9,10}

The NSF was introduced as a reconstruction technique to reduce cerebrospinal fluid leakage and has recently been widely used.¹¹ Its abundant supply of blood vessels and large surface area make it useful for the reconstruction of skull base defects, and it has the advantage of reducing the rate of cerebrospinal fluid leakage to <5%.¹² On the other hand, complications such as septal perforation, cartilage necrosis, and olfactory dysfunction may occur due to the manipulation of the nasal mucosa during NSF.¹⁰ Olfactory dysfunction cannot only be hazardous for patients but is also an important factor in quality of life, causing discomfort in interpersonal relationships and changes in eating habits. There have been many studies on the incidence, severity, and prevention of olfactory dysfunction following NSF.¹³

In our previous study, a slower rate of olfactory recovery in the NSF elevation group, compared with the TSA group, was reported. To compare the long-term influence of each procedure on olfactory outcomes, long-term observations involving more patients and follow-ups were performed in

Table 3 Multiple linear regression analysis of the olfactory function parameters after the trans-sphenoidal approach

Variable	Parameter Estimate	Standard error	t-value	p-value
2 months after surgery				
VAS	-2.14018	0.51965	-4.12	0.0045
TDI	-25.77452	7.06595	-3.65	0.0082
3 months after surgery				
VAS	-21.56049	8.91284	-2.42	0.0462
TDI	-6.94456	2.03294	-3.42	0.0112

the present study. As in the previous study, patients who underwent surgery using TSA demonstrated rapid recovery starting from 1 month postoperatively according to self-reported VAS and TDI scores, with no significant difference in olfactory function 2 months postoperatively compared with preoperative functions. On the other hand, the NSF elevation group demonstrated a much slower recovery, with TDI scores and self-reported VAS scores recovering to preoperative values 3 months and 6 months postoperatively, respectively. Compared with previous research, observations indicated a slower recovery of olfactory function in the NSF elevation group, although recovery to a function similar to pre-operative levels was observed 6 months post-operation. Thus, there was no significant difference in the incidence of permanent olfactory dysfunction, suggesting that despite a difference in the rate of olfactory recovery, NSF elevation does not increase the risk of permanent nerve damage.

The causes of olfactory dysfunction following TSA surgery include direct damage to the olfactory epithelium during surgery, as well as the blockage of airflow to the olfactory epithelium, local inflammation of the surrounding olfactory epithelium, and impaired blood flow.^{5,14} Typically, the regeneration of the epithelium begins in the 1st week following surgery, with complete regeneration of the membrane known to take ~6 weeks.¹⁴ By 8 to 10 weeks postoperatively, symptoms such as nasal obstruction and dryness are improved, and airflow to the olfactory epithelium is normalized. As such, persistent olfactory dysfunction 2 months postoperatively can be attributed to dysfunction caused by local inflammation and impaired blood flow. Proper removal of elements that may induce local inflammation in the mucous membrane or affect airflow within the nasal cavity may be an important factor in olfactory recovery.

Tam et al. reported that endoscopic TSA results in decreased olfactory function, with or without NSF.¹⁵ Furthermore, in the study, 20 patients were enrolled and divided into group 1 and group 2. Group 1 was randomized to undergo NSF and group 2 to undergo reconstruction with Gelfoam (Pfizer, New York, NY, USA) and Tiseel (Baxter, Deerfield, IL, USA). Both groups showed decreased University of Pennsylvania Smell Identification Test (UPSIT) scores postoperatively, and group 1 had significantly worse scores postoperatively.¹⁵ Carvalho et al. reported that endoscopic TSA with NSF resulted in olfactory dysfunction 1 month postoperatively; however, olfactory function recovered after a 3-month follow-up.¹⁶ Rotenberg et al. reported that endoscopic TSA with NSF resulted in decreased UPSIT value to moderate hyposmia (30.8) 6 months postoperatively.¹⁷ Compared with these studies, Carvalho et al.¹⁶ and our study showed less olfactory dysfunction after TSA with NSF. If we carefully suggest the cause of the discrepancy in olfactory dysfunction, there was a difference in how much olfactory epithelium was retained. Tam et al. and Rotenberg et al. retained olfactory epithelium 1 cm from the skull base.^{15,17} In contrast, Carvalho et al. retained olfactory epithelium in the left upper margin 1.5 to 2 cm from the upper nasal septum.¹⁶ In our study, the upper incision was up to the upper third of the anterior middle turbinate to preserve the

superior olfactory epithelium. Research is needed to determine what caused the differences in olfactory outcomes.

Permanent anosmia or hyposmia after TSA rarely occurs. However, we reported one case of anosmia after TSA in the NSF group. Rotenberg et al. also reported 1 case of severe hyposmia after TSA in the NSF group of 17 participants.¹⁷ In future studies, it would be helpful to collect permanent anosmia or severe hyposmia cases and evaluate the causes of permanent olfactory dysfunction through these cases.

The present study was retrospective in nature with a small sample size. Hence, a prospective study on a bigger scale may be needed in the future. As the indications for endoscopic skull base surgery are diversifying, the need for reconstruction through NSF is also increasing. It is expected that a study of the sequelae of NSF and their treatment will be conducted in the future.

Conclusion

Although patients who underwent trans-sphenoidal surgery involving NSF elevation demonstrated slower olfactory recovery than patients who underwent surgery involving the TSA, there were no significant differences in the incidence of permanent olfactory dysfunction.

Conflict of Interests

The authors have no conflict of interests to declare.

Contributions of the Authors

Conceptualization: Jong In Jeong.

Data curation: Jong In Jeong.

Formal analysis: Jong In Jeong.

Funding acquisition: Bon Min Koo

Investigation: Bon Min Koo

Methodology: Jong In Jeong, Bon Min Koo

Project administration: Jong In Jeong

Resources: Bon Min Koo

Software: Jong In Jeong

Supervision: Jong In Jeong

Validation: Jong In Jeong

Visualization: Bon Min Koo

Writing - original draft: Bon Min Koo

Writing - review and editing: Jong In Jeong, Bon Min Koo

References

- Prevedello DM, Doglietto F, Jane JA Jr, Jagannathan J, Han J, Laws ER Jr. History of endoscopic skull base surgery: its evolution and current reality. *J Neurosurg* 2007;107(01):206–213
- Lee KH, Yang CW. Endoscopic endonasal skull base repair with nasoseptal flap. *Korean J Otorhinolaryngol-Head Neck Surg* 2015; 58(01):7–11
- Jaleesi M, Jahanbakhshi A, Amini E, Kamrava SK, Farhadi M. Impact of nasoseptal flap elevation on sinonasal quality of life in endoscopic endonasal approach to pituitary adenomas. *Eur Arch Otorhinolaryngol* 2016;273(05):1199–1205
- Alobid I, Enseñat J, Mariño-Sánchez F, et al. Impairment of olfaction and mucociliary clearance after expanded endonasal approach using vascularized septal flap reconstruction for skull base tumors. *Neurosurgery* 2013;72(04):540–546

- 5 Kim JR, Kim E, Jeong JI. The short-term recovery patterns of olfactory function after trans-sphenoidal approach with nasoseptal flap elevation. *J Korean Skull Base Soc* 2017;12(02):25–32
- 6 Gudziol V, Lötsch J, Hähner A, Zahnert T, Hummel T. Clinical significance of results from olfactory testing. *Laryngoscope* 2006;116(10):1858–1863
- 7 Paluzzi A, Gardner P, Fernandez-Miranda JC, Snyderman C. The expanding role of endoscopic skull base surgery. *Br J Neurosurg* 2012;26(05):649–661
- 8 Graffeo CS, Dietrich AR, Grobelny B, et al. A panoramic view of the skull base: systematic review of open and endoscopic endonasal approaches to four tumors. *Pituitary* 2014;17(04):349–356
- 9 Ciric I, Ragin A, Baumgartner C, Pierce D. Complications of trans-sphenoidal surgery: results of a national survey, review of the literature, and personal experience. *Neurosurgery* 1997;40(02):225–236, discussion 236–237
- 10 Soudry E, Psaltis AJ, Lee KH, Vaezafshar R, Nayak JV, Hwang PH. Complications associated with the pedicled nasoseptal flap for skull base reconstruction. *Laryngoscope* 2015;125(01):80–85
- 11 Rivera-Serrano CM, Snyderman CH, Gardner P, et al. Nasoseptal “rescue” flap: a novel modification of the nasoseptal flap technique for pituitary surgery. *Laryngoscope* 2011;121(05):990–993
- 12 Hadad G, Bassagasteguy L, Carrau RL, et al. A novel reconstructive technique after endoscopic expanded endonasal approaches: vascular pedicle nasoseptal flap. *Laryngoscope* 2006;116(10):1882–1886
- 13 Hummel T, Nordin S. Olfactory disorders and their consequences for quality of life. *Acta Otolaryngol* 2005;125(02):116–121
- 14 Majovsky M, Astl J, Kovar D, Masopust V, Benes V, Netuka D. Olfactory function in patients after transsphenoidal surgery for pituitary adenomas—a short review. *Neurosurg Rev* 2019;42(02):395–401
- 15 Tam S, Duggal N, Rotenberg BW. Olfactory outcomes following endoscopic pituitary surgery with or without septal flap reconstruction: a randomized controlled trial. *Int Forum Allergy Rhinol* 2013;3(01):62–65
- 16 Carvalho ACM, Dolci RLL, Rickli JCK et al. Evaluation of olfactory function in patients undergoing endoscopic skull base surgery with nasoseptal flap. *Rev Bras Otorrinolaringol (Engl Ed)* 2022;88(01):15–21
- 17 Rotenberg BW, Saunders S, Duggal N. Olfactory outcomes after endoscopic transsphenoidal pituitary surgery. *Laryngoscope* 2011;121(08):1611–1613