



## Bilateral snapping triceps syndrome: A case report

Chul-Hyun Cho, Kyung-Hwan Lim, Du-Han Kim

**Specialty type:** Orthopedics

**Provenance and peer review:**

Unsolicited article; Externally peer reviewed.

**Peer-review model:** Single blind

**Peer-review report's scientific quality classification**

Grade A (Excellent): 0

Grade B (Very good): 0

Grade C (Good): C

Grade D (Fair): 0

Grade E (Poor): 0

**P-Reviewer:** Lv L, China

**Received:** October 10, 2023

**Peer-review started:** October 10, 2023

**First decision:** November 22, 2023

**Revised:** November 24, 2023

**Accepted:** November 28, 2023

**Article in press:** November 28, 2023

**Published online:** December 6, 2023



**Chul-Hyun Cho, Du-Han Kim**, Department of Orthopedic Surgery, Keimyung University Dongsan Hospital, Keimyung University School of Medicine, Daegu 42601, South Korea

**Kyung-Hwan Lim**, Orthopedic Surgery, Allright Hospital, Daegu 42038, South Korea

**Corresponding author:** Du-Han Kim, PhD, Doctor, Department of Orthopedic Surgery, Keimyung University Dongsan Hospital, Keimyung University School of Medicine, 1035 Dalgubul ro, Dalseo gu, Daegu 42601, South Korea. [osmdkdh@gmail.com](mailto:osmdkdh@gmail.com)

### Abstract

#### BACKGROUND

Snapping triceps syndrome (STS) is a rare disease, while occurrence of bilateral STS is extremely rare. It is usually accompanied by dislocation of the ulnar nerve and double snapping is a clinically important feature. However, to the best of our knowledge, there has been no report of bilateral STS in young active patient.

#### CASE SUMMARY

A 23-year-old male presented with a complaint of discomfort and snapping on the medial side of both elbows while performing push-ups. On physical examination, two distinct snaps that were both palpable and audible were detected on additional clinical examination. Dynamic ultrasonography showed that the ulnar nerve and the medial head of the triceps were dislocated anteriorly over the medial epicondyle of the elbow during flexion motion. Finally, he was diagnosed as dislocation of the ulnar nerve and STS. Staged anterior subcutaneous transposition of the ulnar nerve combined with partial resection of the snapping portion of the triceps was performed. The patient's pain and snapping symptoms were resolved immediately after surgery. Three months later, the patient was completely asymptomatic and returned to normal activity.

#### CONCLUSION

STS should be included in the differential diagnosis for active young patients who present with painful snapping on the medial side of the elbow joint, particularly when dislocation of the ulnar nerve is detected. Dynamic sonography is used to assist in accurate diagnosis and differentiation between isolated dislocation of the ulnar nerve and STS.

**Key Words:** Triceps; Triceps snapping syndrome; Ulnar nerve; Elbow; Dynamic sonography; Case report

©The Author(s) 2023. Published by Baishideng Publishing Group Inc. All rights reserved.

**Core Tip:** Snapping triceps syndrome (STS) is a rare disease, while occurrence of bilateral STS is extremely rare. It is usually accompanied by dislocation of the ulnar nerve and double snapping is a clinically important feature. Dislocation of the ulnar nerve typically occurs first, at approximately 70 to 90 degrees of elbow flexion, followed by dislocation of the triceps at approximately 100 to 110 degrees of elbow flexion. Dynamic sonography is used to assist in accurate diagnosis and differentiation. Here we reported on the case of a patient who underwent surgery for treatment of bilateral STS.

**Citation:** Cho CH, Lim KH, Kim DH. Bilateral snapping triceps syndrome: A case report. *World J Clin Cases* 2023; 11(34): 8228-8234

**URL:** <https://www.wjgnet.com/2307-8960/full/v11/i34/8228.htm>

**DOI:** <https://dx.doi.org/10.12998/wjcc.v11.i34.8228>

## INTRODUCTION

Snapping triceps syndrome (STS), a relatively rare disease, was first described by Rolfsen in 1970. It is defined as a dynamic phenomenon involving dislocation of the distal portion of the triceps over the medial epicondyle of the elbow[1-3]. Risk factors include cubital valgus or varus, hypertrophy or prominence of the distal triceps muscle, or accessory head of the triceps. STS is more common in abnormal triceps position as well as individuals who perform manual work related to hypertrophy of the triceps muscle through training[4,5]. Movement of the bulked medial triceps is more medial, which causes translocation (snapping) of a portion of the triceps over the medial epicondyle with flexion of the elbow[4].

Patients usually complain of local tenderness and a snapping sensation or sound around the medial side of the elbow. Because the condition usually involves coexistence with ulnar nerve dislocation, neuropathy of the ulnar nerve may also be observed. Two distinct snapping sounds can be detected in patients with typical STS. Dislocation of the ulnar nerve typically occurs first, at approximately 70 to 90 degrees of elbow flexion, followed by dislocation of the triceps at approximately 100 to 110 degrees of elbow flexion[6]. Confirmation of two characteristic snapping sounds around the medial side of the elbow during flexion is important. Recently, dynamic sonography is used to assist in accurate diagnosis and differentiation from diseases around elbow[7-11].

To the best of our knowledge, no previous cases of bilateral STS have been reported. Here we reported on the case of a patient who underwent surgery for treatment of bilateral STS.

## CASE PRESENTATION

### Chief complaints

A 23-year-old male, an amateur bodybuilder, presented with a complaint of discomfort and snapping on the medial side of both elbows while performing push-ups for three years.

### History of present illness

His symptoms had worsened over the past two months. The pain, along with the snapping sound, then became constant with development of an intermittent tingling sensation on the ulnar side forearm and 5<sup>th</sup> finger area. In particular, the symptoms were aggravated by both resisted elbow flexion and resisted elbow extension.

### History of past illness

Because he primarily regarded his symptoms as an inconvenience, he did not undergo treatment.

### Personal and family history

The patient was a college student with no history of elbow surgery, and there was no history of trauma or sport injury as well. There was no other past illness or family history.

### Physical examination

On physical examination, tenderness over the medial epicondyle of the elbow was not observed and there were no clinical findings indicative of ulnar nerve compression. Two distinct snaps that were both palpable and audible were detected on additional clinical examination. The first snap had developed at approximately 90 degrees of elbow flexion and the second snap had developed at above 100 degrees of elbow flexion.

### Laboratory examinations

The results of preoperative laboratory tests were normal.

### Imaging examinations

No bony abnormality such as cubitus varus or valgus was observed on the plain radiographs. A T2-weighted magnetic

resonance image (MRI) showed a high signal change and swelling of the ulnar nerve (Figure 1). Dynamic ultrasonography showed that the ulnar nerve was dislocated anteriorly over the medial epicondyle of the elbow in flexion of the elbow by 90 degrees and the medial head of the triceps was also dislocated anteriorly over the medial epicondyle in flexion of the elbow by 100 degrees (Figure 2).

---

## FINAL DIAGNOSIS

---

The final diagnosis of the presented case was bilateral STS of elbow joints.

---

## TREATMENT

---

Conservative treatment was initially considered. However, the patient was an amateur bodybuilder who usually participated in several sports activities, and he wanted to anticipate returning to participation in sports as soon as possible. Therefore, surgery on the left elbow, which showed more severe symptoms, was planned. Anterior subcutaneous transposition of the ulnar nerve combined with partial resection of the snapping portion of the triceps was our surgical treatment of choice. After inflating a tourniquet, an 8 cm incision was made from 4 cm proximal to 4 cm distal of the medial epicondyle. During performance of the subcutaneous dissection, the medial antebrachial cutaneous nerve was located, and care was taken to avoid damaging it. The ulnar nerve was thickened and dislocated from the posterior to the anterior of the medial epicondyle with flexion of the elbow by 90 degrees (Figure 3). Neurolysis was performed using a vessel loop and the ulnar nerve was mobilized sufficiently to transpose it anteriorly without tension. With further flexion of the elbow, the leading edge of the medial head of the triceps was dislocated over the medial epicondyle. The minimum extent of the dislocated medial head of the triceps was measured by repeat passive flexion of the elbow and the medial head of the triceps, and was located over the medial epicondyle, was resected (Figure 4). After resection, it was confirmed that flexion of the elbow did not cause any dislocation of the triceps. Hemostasis was performed after the tourniquet was delated. Postoperatively, passive motion was subsequently initiated as pain permitted. Active mobilization was allowed after one week and no snap was observed on physical examination. He had no complaint of discomfort after three months of follow up, therefore, surgery on the right elbow was planned. The surgical method was the same as that used for the left side. The ulnar nerve was also thickened and dislocated from the posterior to the anterior of the medial epicondyle with flexion of the elbow by 80 degrees. After dissection and mobilization of the anterior of the ulnar nerve, the bulked-leading edge of the medial head of the triceps was also dislocated over the medial epicondyle with further flexion of the elbow (Figure 5) (Video 1). The minimum extent of the dislocated medial head of the triceps was measured by repeat passive flexion of the elbow and the medial head of the triceps, measuring 3 cm, located over the medial epicondyle, was resected. After resection, anterior transposition of the ulnar nerve was performed (Figure 6).

---

## OUTCOME AND FOLLOW-UP

---

The patient's pain and snapping symptoms showed significant improvement after surgery. Dynamic ultrasonography showed that the ulnar nerve and triceps were not dislocated during flexion and extension of the elbow at six weeks postoperatively. Three months later, the patient was completely asymptomatic and returned to participation in sports. And during the one-year follow-up, there were no symptoms in both elbows.

---

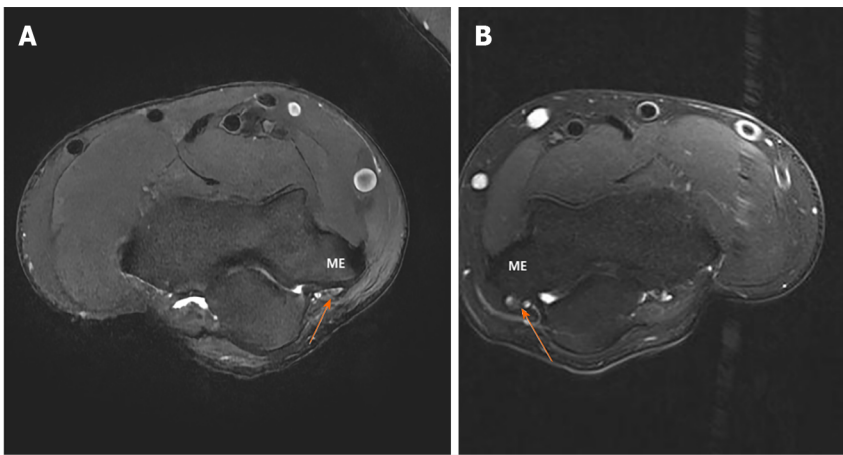
## DISCUSSION

---

This case involves a rare disorder with STS in a bilateral elbow joint. STS with dislocation of the ulnar nerve can be easily overlooked when dislocation of the ulnar nerve and triceps occurs simultaneously at a similar angle during flexion of the elbow, resulting in detection of only one snapping sound, or when the second snapping sound is missed on physical examination. In particular, in cases where this disease is not considered, it is often misdiagnosed as isolated dislocation of the ulnar nerve.

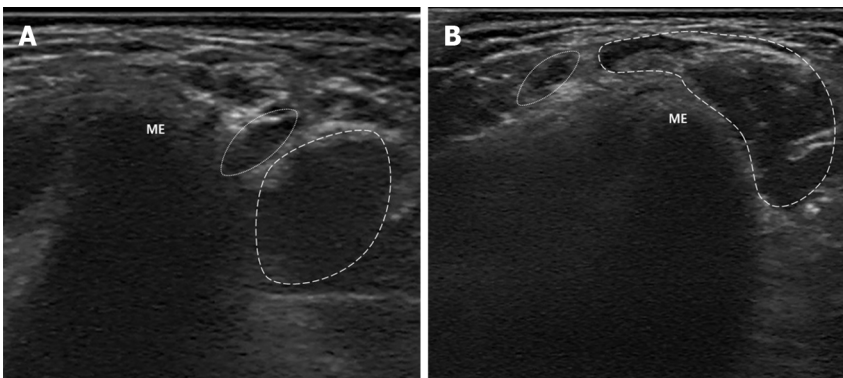
Isolated dislocation of the ulnar nerve is relatively common, occurring in approximately 16.2% of healthy adults (subluxation: 12%, complete dislocation: 4%)[12]. Causes include congenital general laxity, hypoplasia of the trochlea, and dislocation of the medial head of the triceps with or without cubitus varus/valgus deformity[13-15]. Also, several authors insisted that cubitus varus or valgus, fourth muscular head of the triceps, or accessory triceps tendon and hypertrophy of the medial head of the triceps are risk factors for STS[14-16]. However, in our case, there were no risk factors such as congenital general laxity, bony abnormalities or anatomical variances of the triceps were detected. The patient had performed several strengthening exercises, thus the bulk of the triceps could be confirmed. Therefore, we considered that the bulk of the medial head of the triceps may have caused STS.

MRI or dynamic ultrasound can assist in the diagnosis of snapping triceps syndrome. Although MRI can enable accurate identification of anatomical structures of the elbow joint, there is limitation in identifying dislocation or



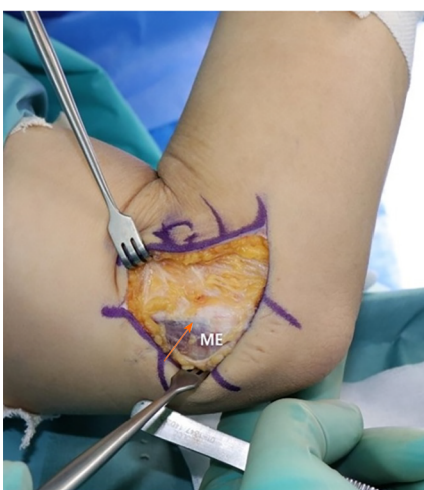DOI: 10.12998/wjcc.v11.i34.8228 Copyright ©The Author(s) 2023.

**Figure 1** Pre-operative axial T2-weighted magnetic resonance image shows the high signal change and swelling of the ulnar nerve. A: Rt. Elbow; B: Lt. Elbow. Arrow: Ulnar nerve, ME: Medial epicondyle.



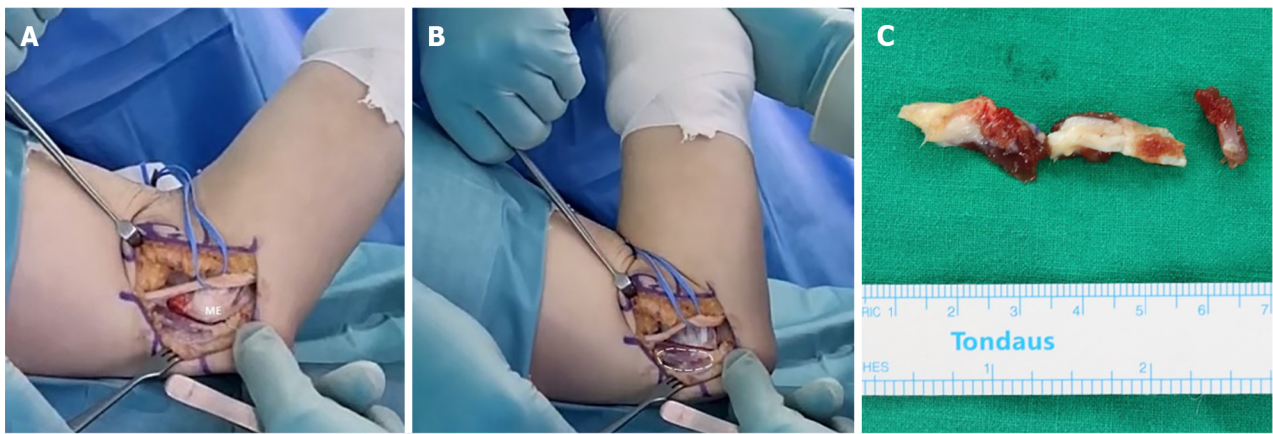
DOI: 10.12998/wjcc.v11.i34.8228 Copyright ©The Author(s) 2023.

**Figure 2** Pre-operative transverse dynamic ultrasonography of the patient. A: In extension of the elbow, the ulnar nerve and medial head of the triceps are located posterior to the medial epicondyle; B: With flexion of the elbow by 100 degrees, the ulnar nerve and medial head of the triceps are dislocated anteriorly over the medial epicondyle. ME: Medial epicondyle, dotted circle: Ulnar nerve, dashed circle: Medial head of the triceps.



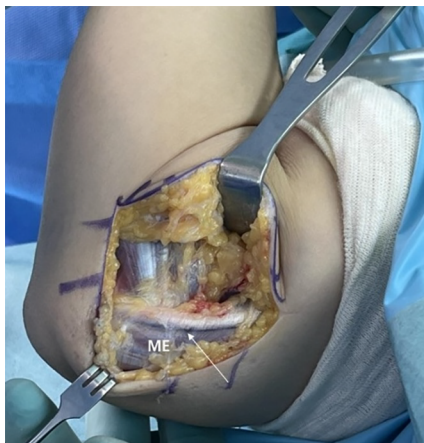DOI: 10.12998/wjcc.v11.i34.8228 Copyright ©The Author(s) 2023.

**Figure 3** Clinical photo of the left elbow. With flexion of the elbow by 90 degrees, the medial head of the triceps is dislocated anteriorly over the medial epicondyle. Arrow: ulnar nerve, ME: Medial epicondyle.



DOI: 10.12998/wjcc.v11.i34.8228 Copyright ©The Author(s) 2023.

**Figure 4 Clinical photo after anterior transposition of the ulnar nerve.** A: With flexion of the elbow by 80 degrees, the medial head of the triceps is located posterior to the medial epicondyle; B: With flexion of the elbow by 100 degrees, the medial head of the triceps is dislocated anteriorly over the medial epicondyle; C: Medial head of the triceps, located over the medial epicondyle, was resected. ME: Medial epicondyle, dashed circle: Dislocated medial head of the triceps.



DOI: 10.12998/wjcc.v11.i34.8228 Copyright ©The Author(s) 2023.

**Figure 5 Clinical photo of the right elbow.** With flexion of the elbow by 90 degrees, the medial head of the triceps is dislocated anteriorly over the medial epicondyle. Arrow: Ulnar nerve, ME: Medial epicondyle.

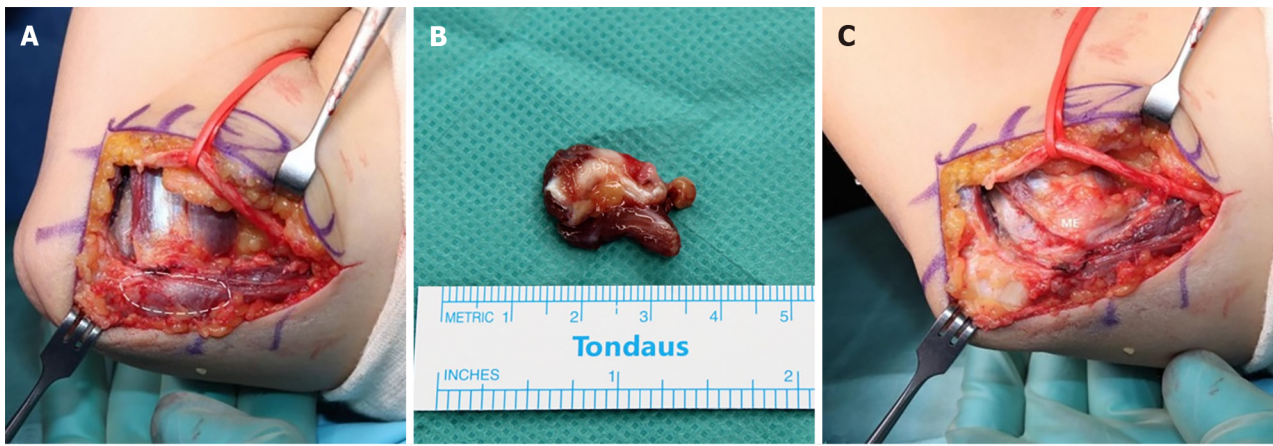
subluxation of the ulnar nerve and triceps. Therefore, dynamic ultrasound is more useful for diagnosis of STS than MRI [7]. However, in cases where dislocation of the ulnar nerve and the medial head of the triceps occurs at a similar degree, diagnosis of snapping triceps syndrome may not be easy. Careful physical assessment is important during repetition of flexion and extension of the elbow in order to determine whether it is isolated dislocation of the ulnar nerve or STS. The ulnar nerve dislocated at 90 degrees and the medial head of the triceps dislocated at approximately 120 degrees[17].

Surgical options include partial resection of the snapping slip, centralization or lateralization of the medial triceps of the triceps, medial condylotomy or corrective osteotomy, addressing humeral malignment[18]. Centralization or lateralization involves detaching the tendon of the medial head of the olecranon and passing it under, interlacing it with the central tendon or lateral tendon. This procedure is typically chosen in cases where the segment of snapping triceps represents a significant bulk of the medial head[19]. Partial resection of a snapping slip is chosen in select cases with small dislocating segments and easier and more rapid recovery can be expected; most studies have reported excellent results [18]. In our case, the snapping slip was not large in size, therefore, partial triceps resection was selected. Care should be taken not to resect an excessive amount of tendon, with the aim of not compromising the triceps function.

A limitation of this case was that preoperative nerve conduction velocity-electromyography was not performed. Because, on the preoperative physical examination, two snapping sounds were detected during flexion of the elbow and only a tingling sensation of the ulnar side of the hand without weakness was observed.

## CONCLUSION

STS should be included in the differential diagnosis for active young patients who present with painful snapping on the



DOI: 10.12998/wjcc.v11.i34.8228 Copyright ©The Author(s) 2023.

**Figure 6 Clinical photo after anterior transposition of the ulnar nerve.** A: With flexion of the elbow by 100 degrees, the medial head of the triceps is dislocated anteriorly over the medial epicondyle; B: Medial head of the triceps, located over the medial epicondyle, was resected; C: After resection, it was confirmed that flexion of the elbow did not cause any dislocation of the triceps with flexion of the elbow by 100 degrees. ME: Medial epicondyle, dashed circle: Dislocated medial head of the triceps.

medial side of the elbow joint, particularly when dislocation of the ulnar nerve is detected. Dynamic sonography is used to assist in accurate diagnosis and differentiation between isolated dislocation of the ulnar nerve and STS.

## ACKNOWLEDGEMENTS

The authors thank Eun-Ji Jeon for her support.

## FOOTNOTES

**Co-first authors:** Chul-Hyun Cho and Kyung-Hwan Lim.

**Author contributions:** Cho CH and Kim DH contributed to conceptualization; Lim KH contributed to investigation; Lim KH and Kim DH contributed to data curation; Lim KH contributed to writing – original draft preparation; Kim DH and Cho CH contributed to writing – review and editing; Cho CH contributed to supervision; Kim DH contributed to project administration; the first two authors contributed equally to this article as first authors; All authors have read and agreed to the published version of the manuscript; Cho CH and Lim KH contributed equally to this article as first authors.

**Informed consent statement:** Informed written consent was obtained from the patient for publication of this report and any accompanying images.

**Conflict-of-interest statement:** All the authors declare that they have no conflict of interest.

**CARE Checklist (2016) statement:** the authors have read the CARE Checklist (2016), and the manuscript was prepared and revised according to the CARE Checklist (2016).

**Open-Access:** This article is an open-access article that was selected by an in-house editor and fully peer-reviewed by external reviewers. It is distributed in accordance with the Creative Commons Attribution NonCommercial (CC BY-NC 4.0) license, which permits others to distribute, remix, adapt, build upon this work non-commercially, and license their derivative works on different terms, provided the original work is properly cited and the use is non-commercial. See: <https://creativecommons.org/licenses/by-nc/4.0/>

**Country/Territory of origin:** South Korea

**ORCID number:** Chul-Hyun Cho 0000-0003-0252-8741; Kyung-Hwan Lim 0000-0002-4010-2867; Du-Han Kim 0000-0002-6636-9340.

**S-Editor:** Liu JH

**L-Editor:** A

**P-Editor:** Yu HG

## REFERENCES

- 1 **Hayashi Y**, Kojima T, Kohno T. A case of cubital tunnel syndrome caused by the snapping of the medial head of the triceps brachii muscle. *J Hand Surg Am* 1984; **9A**: 96-99 [PMID: 6693751 DOI: 10.1016/S0363-5023(84)80194-X]
- 2 **Rolfen L**. Snapping triceps tendon with ulnar neuritis. Report on a case. *Acta Orthop Scand* 1970; **41**: 74-76 [PMID: 5453901 DOI: 10.3109/17453677008991979]
- 3 **Dreyfuss U**, Kessler I. Snapping elbow due to dislocation of the medial head of the triceps. A report of two cases. *J Bone Joint Surg Br* 1978; **60**: 56-57 [PMID: 627579 DOI: 10.1302/0301-620X.60B1.627579]
- 4 **Boon AJ**, Spinner RJ, Bernhardt KA, Ross SR, Kaufman KR. Muscle activation patterns in snapping triceps syndrome. *Arch Phys Med Rehabil* 2007; **88**: 239-242 [PMID: 17270523 DOI: 10.1016/j.apmr.2006.11.011]
- 5 **Kim J-H**, Cho C-H, Koo T-W, Kim D-H. Misdiagnosed Snapping Triceps Syndrome on Ulnar Nerve Dislocation. *J Korean Orthop Assoc* 2023; **58**: 73-77 [DOI: 10.4055/jkoa.2023.58.1.73]
- 6 **Vanhees MKD**, Geurts GFAE, Van Riet RP. Snapping triceps syndrome: a review of the literature. *Shoulder Elbow* 2010; **2**: 30-33 [DOI: 10.1111/j.1758-5740.2009.00033.x]
- 7 **Jeong WK**, Park SW, Song DI, Lee SH. Snapping Triceps Syndrome with Dislocation of the Ulnar Nerve-Usefulness of Dynamic Ultrasonography. *J Korean Orthop Ultrasound Soc* 2008; **1**: 27-30
- 8 **Daliri M**, Ebrahimnejad M, Najafi S, Aminzadeh B, Emadzadeh M, Moradi E, Moradi A. Magnetic Resonance Imaging and Sonographic Features before and after Surgery in Carpal Tunnel Syndrome: Association with Clinical Findings. *Clin Orthop Surg* 2022; **14**: 603-612 [PMID: 36518939 DOI: 10.4055/cios22031]
- 9 **Shim JW**, Jeon N, Jang MC, Park MJ. Clinical Outcomes of Arthroscopic Debridement for Lateral Epicondylitis with Partial Injury of the Lateral Collateral Ligament Complex. *Clin Orthop Surg* 2022; **14**: 434-440 [PMID: 36061854 DOI: 10.4055/cios21220]
- 10 **Shin W**, Kang T, Han J. Cubital tunnel syndrome associated with previous ganglion cyst excision in the elbow: a case report. *Clin Shoulder Elb* 2022 [PMID: 37088883 DOI: 10.5397/cise.2022.01102]
- 11 **Colasanti CA**, Boin M, Hacquebord J, Virk M. Anterior interosseous nerve palsy in the early postoperative period after open capsular release for elbow stiffness. *Clin Shoulder Elb* 2022 [PMID: 37088884 DOI: 10.5397/cise.2022.00899]
- 12 **Childress HM**. Recurrent ulnar-nerve dislocation at the elbow. *Clin Orthop Relat Res* 1975; 168-173 [PMID: 1139823 DOI: 10.1097/00003086-197505000-00027]
- 13 **Bjerre JJ**, Johannsen FE, Rathcke M, Krogsgaard MR. Snapping elbow-A guide to diagnosis and treatment. *World J Orthop* 2018; **9**: 65-71 [PMID: 29686971 DOI: 10.5312/wjo.v9.i4.65]
- 14 **Pfister G**, Barbier O, Ollat D. "Snapping triceps": A rare and misleading condition - a clinical case report. *Hand Surg Rehabil* 2018; **37**: 121-123 [PMID: 29396151 DOI: 10.1016/j.hansur.2017.12.002]
- 15 **Fabrizio PA**, Clemente FR. Variation in the triceps brachii muscle: a fourth muscular head. *Clin Anat* 1997; **10**: 259-263 [PMID: 9213044 DOI: 10.1002/(SICI)1098-2353(1997)10:4<259::AID-CA8>3.0.CO;2-N]
- 16 **Satteson ES**, Li Z. Anteriorly positioned ulnar nerve at the elbow: a rare anatomical event: case report. *J Hand Surg Am* 2015; **40**: 984-986 [PMID: 25817750 DOI: 10.1016/j.jhsa.2015.02.006]
- 17 **Spinner RJ**, Goldner RD. Snapping of the medial head of the triceps and recurrent dislocation of the ulnar nerve. Anatomical and dynamic factors. *J Bone Joint Surg Am* 1998; **80**: 239-247 [PMID: 9486730 DOI: 10.2106/00004623-199802000-00011]
- 18 **Imao K**, Miwa H, Tsubokawa N, Maki Y, Endo N. Dislocation of the Medial Head of the Triceps With Ulnar Nerve Location Anterior to the Medial Epicondyle. *J Hand Surg Am* 2020; **45**: 72.e1-72.e4 [PMID: 31085093 DOI: 10.1016/j.jhsa.2019.03.005]
- 19 **Spinner RJ**, O'Driscoll SW, Jupiter JB, Goldner RD. Unrecognized dislocation of the medial portion of the triceps: another cause of failed ulnar nerve transposition. *J Neurosurg* 2000; **92**: 52-57 [PMID: 10616082 DOI: 10.3171/jns.2000.92.1.0052]



Published by **Baishideng Publishing Group Inc**  
7041 Koll Center Parkway, Suite 160, Pleasanton, CA 94566, USA  
**Telephone:** +1-925-3991568  
**E-mail:** [bpgoffice@wjgnet.com](mailto:bpgoffice@wjgnet.com)  
**Help Desk:** <https://www.f6publishing.com/helpdesk>  
<https://www.wjgnet.com>

