

Successful ablation of non-pulmonary vein triggers of atrial fibrillation using the new cycle length coloring algorithm



Tae-Wan Chung, MD, Minsu Jung, MD, Jongmin Hwang, MD, Seongwook Han, MD, Hyoung-Seob Park, MD

From the Division of Cardiology, Department of Internal Medicine, Keimyung University Dongsan Hospital, Keimyung University School of Medicine, Daegu, Republic of Korea.

Introduction

Even though global efforts to treat atrial fibrillation (AF) are ongoing, there is still no definitive strategy for its treatment. Pulmonary vein (PV) isolation via catheter ablation has become the cornerstone strategy for patients with drug-refractory AF.^{1,2} However, there are many cases of recurrence after a PV isolation, so the selection of an additional ablation lesion set beyond the PV isolation is the main concern in AF ablation. Non-PV triggers are important in the pathogenesis of AF,^{3–6} and the existence of non-PV triggers is one of the main causes of AF recurrence and a worsening of AF from paroxysmal AF to persistent AF.^{7,8} Atrial substrate-targeting strategies, such as ablation of complex fractionated atrial electrograms (CFAE), have been introduced to improve therapeutic outcomes in recurrent/intractable cases.^{9–11}

A novel unipolar-based algorithm, the CARTOFINDER (Biosense Webster, Inc, Irvine, CA), has become available to detect localized sources of AF. This module provides detection techniques for focal activity and rotational activity, and recent studies have shown that these algorithms effectively identify localized abnormal activity during AF mapping.¹¹ Recently, a new module of the CARTOFINDER with the OCTARAY (Biosense Webster, Inc) mapping catheter was introduced, which provides cycle length (CL) color mapping. This map displays the dominant CL calculated for each channel at each CARTOFINDER mapping site.

In this report, we demonstrate a successful non-PV trigger ablation with AF termination, achieved by adding the CARTOFINDER CL color mapping. This incorporation provided

KEY TEACHING POINTS

- We present non-pulmonary vein (PV) trigger ablation with new technology (cycle length [CL] mapping) for recurrent atrial fibrillation (AF) after PV isolation.
- The recent CARTOFINDER module (Biosense Webster, Inc, Irvine, CA) has a new feature enabling it to map the CL, which is called “color CL mapping,” to help identify sites with the shortest CL, indicative of rapid firing and potential tachycardia triggers.
- The integration of the CARTOFINDER CL coloring, voltage, and complex fractionated atrial electrogram maps could represent a significant advancement in the treatment of sustained AF, particularly in cases refractory to conventional PV isolation approaches.
- This case highlights the potential of advanced mapping techniques in AF ablation, particularly for additional ablation following a PV isolation.

the guidance needed to identify more critical signals among the CFAE signals suspected of triggering and sustaining AF.

Case report

A 29-year-old man was admitted owing to recurrent palpitations. A 12-lead electrocardiogram confirmed the recurrence of AF even though he had been taking bisoprolol and propafenone. The patient was scheduled for a radiofrequency catheter ablation of AF. He had a normal left ventricular systolic function with a mild left atrial enlargement (left atrial volume 66.7 mL) on echocardiography.

Upon the patient's arrival in the electrophysiology lab in sinus rhythm, AF was induced with an isoproterenol infusion

KEYWORDS Atrial fibrillation; Radiofrequency catheter ablation; 3D mapping system; Non-pulmonary vein triggers; Complex fractionated atrial electrograms; Cycle length color mapping (Heart Rhythm Case Reports 2024;10:498–501)

Address reprint requests and correspondence: Dr Hyoung-Seob Park, Division of Cardiology, Department of Internal Medicine, Keimyung University Dongsan Hospital, Keimyung University School of Medicine, Daegu, Republic of Korea. E-mail address: drparkgyver@gmail.com.

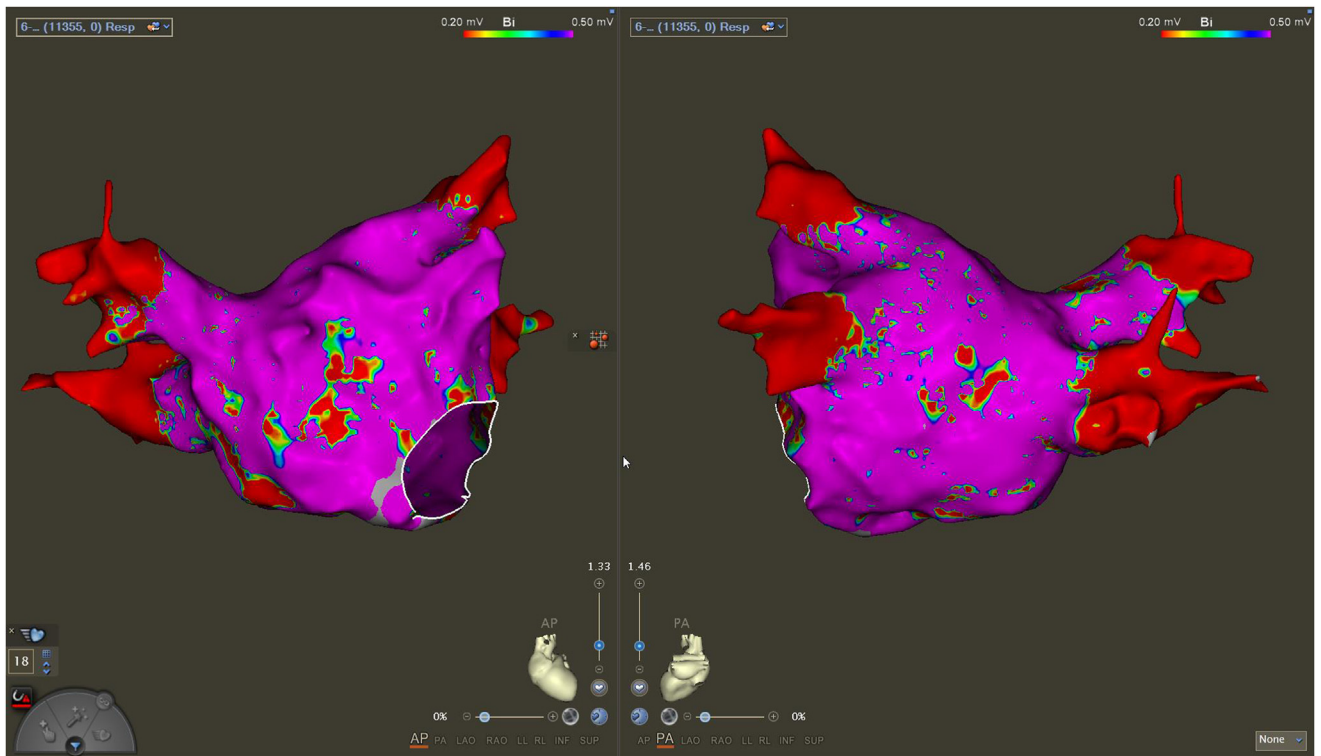


Figure 1 Left atrial voltage map in this case during sustained atrial fibrillation, revealing that the majority of the left atrial signals were normal, and displaying only limited low-voltage areas.

at 20 micrograms per minute. We initially created a left atrial voltage map using an OCTARAY catheter during sustained AF, which revealed that there were only limited low-voltage areas (Figure 1).

We performed a circumferential PV isolation, during which the AF terminated. However, AF was consistently induced with the infusion of isoproterenol at 20 micrograms per minute even though an isolation of all 4 PVs had been

adequately performed. We had positioned the decapolar catheter to detect non-PV triggers from the right side, and we identified repeated non-PV triggers inducing AF from the right free wall of the right atrium (RA), near the right crista (Figure 2). This led us to plan a subsequent examination of the RA to identify the trigger focus.

We performed RA voltage and CFAE mapping using an OCTARAY catheter during sustained AF, followed by CL

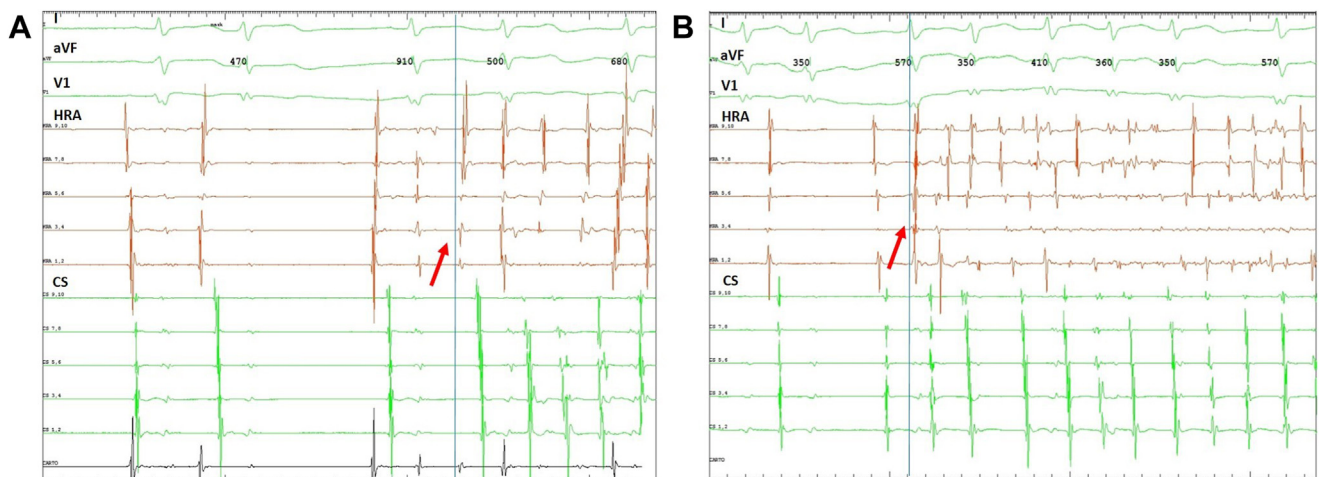


Figure 2 Triggering of sustained atrial fibrillation (AF) near the right free wall. The patient entered the lab in sinus rhythm. **A:** At the procedure’s onset, AF was induced during an isoproterenol infusion at 20 micrograms per minute, as indicated by the red arrow with a blue guiding line. **B:** Spontaneous AF arose from the right free wall with the infusion of isoproterenol following the pulmonary vein isolation, exhibiting a sequence similar to the initial trigger (indicated by the red arrow with a blue guiding line).

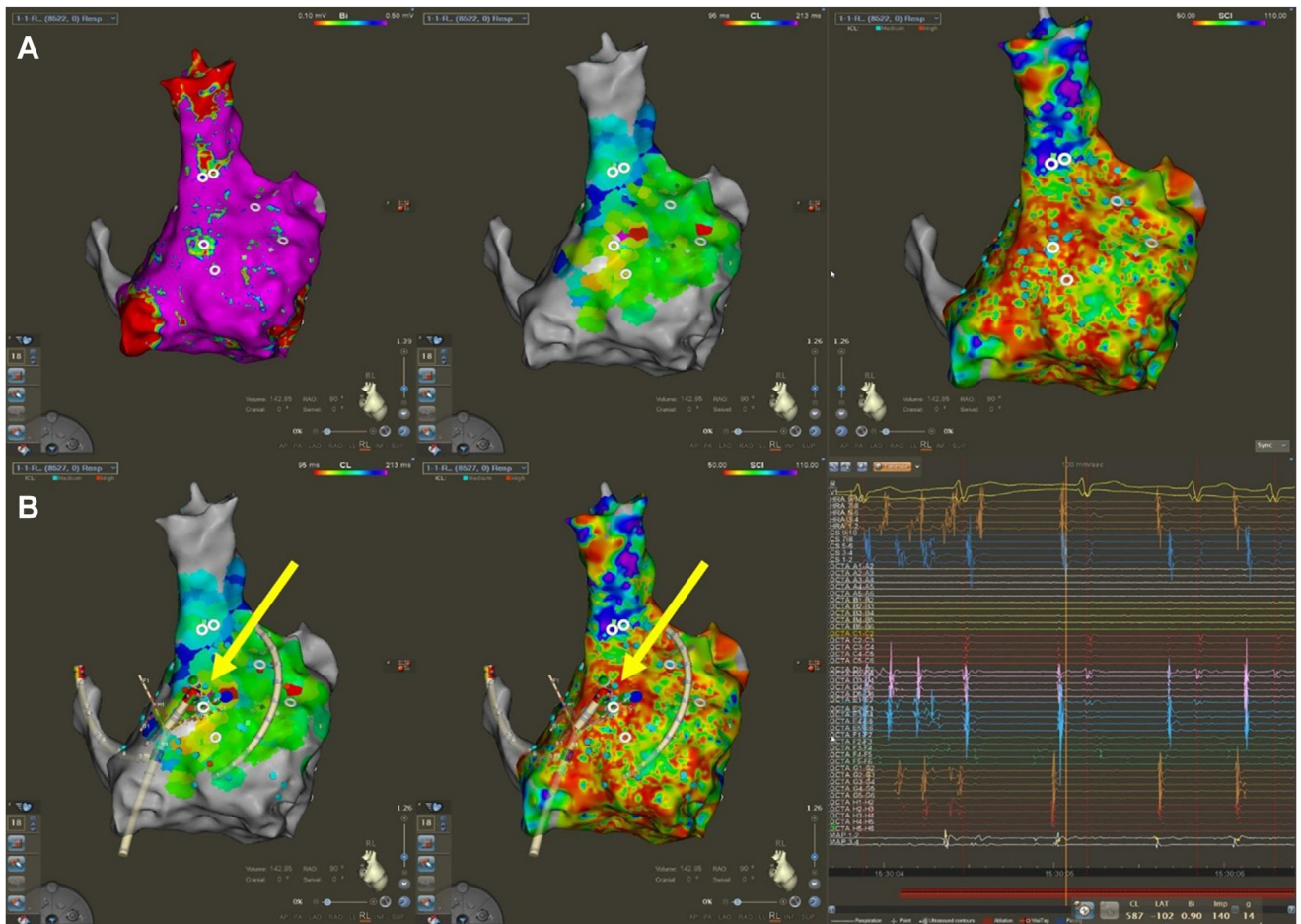


Figure 3 A 3D map using the CARTOFINDER module (Biosense Webster, Inc, Irvine, CA) and presenting the sites of atrial fibrillation (AF) termination. **A:** Comparing the voltage map (Left), cycle length (CL) color map (Middle), and complex fractionated atrial electrogram (CFAE) map (Right) in the right lateral view; the middle area of the right lateral crista (which was suspected as the AF trigger site in the electrophysiology study) shows the relationships among those maps. **B:** We ablated those sites (green dots with yellow arrows) that were matched on the CL color map (Left) and CFAE map (Middle), and the AF terminated during the ablation (Right).

color mapping (Figure 3A). We analyzed the shortest CL sites in the CL color map at the low-voltage sites and CFAE areas. A low-voltage area (<0.10 mV) was observed in the voltage map at the site showing the shortest CL, which corresponded to the CFAE area (indicated by a green dot with a yellow arrow in Figure 3B). Before ablation, we performed high-output pacing at the ablation target site to ensure that there was no phrenic nerve capture. The AF terminated during ablation using 35 watts of power at that site, and we confirmed the absence of any further inducibility after the ablation. The patient has had no episodes of arrhythmias detected during electrocardiograms or Holter monitoring conducted over a span of 6 months.

Discussion

As previously mentioned, there is still no definitive strategy beyond the PV isolation. This is why additional lesion sets for addressing AF are a primary concern in AF abla-

tion, encompassing not only persistent AF but also cases of recurrent paroxysmal AF following a PV isolation. Ablation targeting non-PV triggers of AF is recognized as a strategy beyond a circumferential PV isolation; however, there is no standard for the induction protocol, and it remains elusive, and numerous limitations exist in ablating these sites.¹² Previous studies have shown that CFAE areas can indicate non-PV trigger sites.¹³ The CARTOFINDER system can identify focal activity, and there have been instances where AF termination was achieved through a focal driver ablation using the CARTOFINDER with CFAE mapping.^{14,15} The recent CARTOFINDER module has a new feature, enabling it to map the CL, which is called “color CL mapping,” to help identify sites with the shortest CL, indicative of rapid firing and potential tachycardia triggers. It is expected that, by using this tool in conjunction with existing methods such as low-voltage mapping and CFAE mapping, we can identify suspected points that trigger and sustain AF by analyzing the correlations among them.

In this case, AF was consistently induced even though a PV isolation had been adequately performed. We identified repeated non-PV triggers inducing AF from the right free wall of the RA, near the right crista. Subsequently, we conducted voltage, CFAE mapping, and CARTOFINDER CL color mapping with an OCTARAY catheter while AF was sustained, leading us to a site that exhibited all 3 characteristics: a low voltage, CFAEs, and a shortest CL. The AF terminated during ablation at that site, and we confirmed the absence of any further inducibility after the ablation. This case highlighted the potential of advanced mapping techniques in AF ablation, particularly for additional ablation following a PV isolation.

Conclusion

To our knowledge, this is the first report of successfully ablating a non-PV trigger using the CL color mapping feature of CARTOFINDER, specifically targeting the area with the shortest CL around critical sites. We employed a combination of voltage mapping, CFAE mapping, and CL color mapping to identify the non-PV trigger point of AF, and there was a definite correlation among those maps that terminated the sustained AF. From this perspective, our approach may provide an answer to the unresolved question of managing sustained AF, including persistent AF that goes beyond the conventional strategy of a circumferential PV isolation, which has been the cornerstone of AF ablation until now. However, further cases and studies are essential to validate this method.

Acknowledgments

We thank Mr John Martin for his linguistic assistance, and Hyo-jung Han for her assistance with the CARTO mapping and reviewing.

Funding Sources: This research did not receive any specific grant from funding agencies in the public, commercial, or not-for-profit sectors.

Disclosures: No conflict of interest for all authors above.

References

1. Kirchhof P, Benussi S, Kotecha D, et al. 2016 ESC guidelines for the management of atrial fibrillation developed in collaboration with EACTS. *Eur Heart J* 2016; 37:2893–2962.
2. Calkins H, Hindricks G, Cappato R, et al. 2017 HRS/EHRA/ECAS/APHRS/SOLAECE expert consensus statement on catheter and surgical ablation of atrial fibrillation. *Heart Rhythm* 2017;14:e275–e444.
3. Lin WS, Tai CT, Hsieh MH, et al. Catheter ablation of paroxysmal atrial fibrillation initiated by non-pulmonary vein ectopy. *Circulation* 2003;107:3176–3183.
4. Lee SH, Tai CT, Hsieh MH, et al. Predictors of non-pulmonary vein ectopic beats initiating paroxysmal atrial fibrillation. *J Am Coll Cardiol* 2005;46:1054–1059.
5. Hayashi K, An Y, Nagashima M, et al. Importance of nonpulmonary vein foci in catheter ablation for paroxysmal atrial fibrillation. *Heart Rhythm* 2015;12:1918–1924.
6. Zhao Y, Di Biase L, Trivedi C, et al. Importance of non-pulmonary vein triggers ablation to achieve long-term freedom from paroxysmal atrial fibrillation in patients with low ejection fraction. *Heart Rhythm* 2016;13:141–149.
7. Shah D, Haissaguerre M, Jais P, Hocini M. Nonpulmonary vein foci: do they exist? *Pacing Clin Electrophysiol* 2003;26:1631–1635.
8. Takigawa M, Takahashi A, Kuwahara T, et al. Impact of non-pulmonary vein foci on the outcome of the second session of catheter ablation for paroxysmal atrial fibrillation. *J Cardiovasc Electrophysiol* 2015;26:739–746.
9. Verma A, Mantovan R, Macle L, et al. Substrate and trigger ablation for reduction of atrial fibrillation (STAR AF): a randomized, multicenter, international trial. *Eur Heart J* 2010;31:1344–1356.
10. Jongmin H, Hyoung-Seob P, Seongwook H, et al. Ablation of persistent atrial fibrillation based on high density voltage mapping and complex fractionated atrial electrograms, randomized controlled trial. *Medicine* 2021;100:31.
11. Honarbakhsh S, Schilling RJ, Dhillon G, et al. A novel mapping system for panoramic mapping of the left atrium: application to detect and characterize localized sources maintaining atrial fibrillation. *JACC Clin Electrophysiol* 2018;4:124–134.
12. Santangeli P, Marchlinski FE. Techniques for the provocation, localization, and ablation of non-pulmonary vein triggers for atrial fibrillation. *Heart Rhythm* 2017;14:1087–1096.
13. Lo LW, Lin YJ, Tsao HM, et al. Characteristics of complex fractionated electrograms in nonpulmonary vein ectopy initiating atrial fibrillation/atrial tachycardia. *J Cardiovasc Electrophysiol* 2009;20:1305–1312.
14. Hasebe H, Furuyashiki Y. Potential focal drivers of atrial fibrillation at the left atrial roof vein. *HeartRhythm Case Rep* 2022;8:5–8.
15. Verma A, Sanders P, Champagne J, et al. Selective complex fractionated atrial electrograms targeting for atrial fibrillation study (SELECT AF): a multicenter, randomized trial. *Circ Arrhythm Electrophysiol* 2014;7:55–62.