



Case Report

pISSN 2092-8335 • eISSN 2733-5380
Keimyung Med J 2024;43(2):141-145
<https://doi.org/10.46308/kmj.2024.00080>

Received: May 8, 2024

Revised: July 1, 2024

Accepted: July 8, 2024

Corresponding Author:

Sang Taek Heo, MD

Division of Infectious Disease, Department
of Internal Medicine, College of Medicine,
Jeju National University, 15 Aran 13-gil,
Jeju 63241, Korea

E-mail: neosangtaek@naver.com

© 2024 Keimyung University School of Medicine

© This is an Open Access article distributed under the terms of the Creative Commons Attribution Non-Commercial License (<https://creativecommons.org/licenses/by-nc/4.0/>) which permits unrestricted non-commercial use, distribution, and reproduction in any medium, provided the original work is properly cited.

Tocilizumab as a Potential Treatment Option for Severe Fever with Thrombocytopenia Syndrome

Misun Kim¹, Jeong Rae Yoo¹, Young Ree Kim², Sang Taek Heo¹

¹Department of Internal Medicine, College of Medicine, Jeju National University, Jeju, Korea

²Department of Laboratory Medicine, College of Medicine, Jeju National University, Jeju, Korea

Severe fever with thrombocytopenia syndrome (SFTS) is a viral hemorrhagic disease prevalent in Asian countries with a fatality rate of approximately 10% to 30%. However, there are currently no definitive treatments for reducing mortality. Variable management strategies have been attempted to reduce the mortality rate associated with SFTS. Tocilizumab is an inhibitor of interleukin-6 and is used to treat rheumatologic and viral infectious diseases. This article presents two cases of SFTS in older patients with neurological symptoms and explores the potential use of tocilizumab, as a treatment option. The patient showed improved consciousness and clinical outcomes after tocilizumab administration. This report describes this condition and reviews related literature.

Keywords: Severe fever with thrombocytopenia syndrome, Tocilizumab, Neurologic manifestations, Therapeutics

Introduction

Severe fever with thrombocytopenia syndrome (SFTS) has a variable clinical course ranging from mild to fatal. Initially reported in China, SFTS has now been documented in various countries, particularly in Asia, and specifically in Korea, Japan, and Vietnam [1]. The disease has a high mortality rate, and no specific treatment is currently available. Supportive care remains the primary management approach, although experimental treatments, such as convalescent plasma, monoclonal antibodies, and antiviral drugs, are being investigated [1,2]. However, additional studies are required to assess the safety and efficacy of these treatments.

Interleukin-6 (IL-6) plays a crucial role in immune defense and immune-mediated diseases. Tocilizumab (Actemra; Hoffmann-La Roche) is a monoclonal antibody that targets the IL-6 receptor (IL-6R). It has been used to treat various inflammatory and autoimmune conditions, including rheumatoid arthritis, giant cell arteritis, systemic juvenile idiopathic arthritis, and severe coronavirus disease 2019 (COVID-19) [3-5].

Elevated IL-6 levels have been observed in patients with SFTS, with fatal outcomes in the disease's early stages [6]. Mental status changes have been identified as a risk factor for mortality in patients with SFTS. Herein, we present two cases in which tocilizumab was administered at the onset of changes in mental status.

Case report

Case 1

A 63-year-old male farmer presented to our hospital with a sudden decrease in neurological response on August 12, 2021. The patient had been working in a tangerine field for nine days before the visit. In addition to hypertension, the patient had no underlying medical conditions. He had experienced generalized muscle pain and chills for one week before seeking medical attention. Four days before his hospital visit, he visited a local clinic and received antibiotics and antipyretics. However, his symptoms worsened, and two days before the visit, he experienced inappropriate responses and mobility difficulties, leading to his visit to the emergency room (ER).

Upon arrival at the ER, the patient appeared irritable, and further examination revealed sweating and general weakness. His consciousness level gradually decreased, although he remained responsive to the questions without exceeding the two-step response. According to his family, even when he responded, his behavior appeared strange and was characterized by slow speech and unusual answers. Brain magnetic resonance imaging conducted in the ER revealed no abnormalities and cerebrospinal fluid analysis revealed a white blood cell count of zero. The patient had scattered petechial lesions

on both lower extremities but could not recall being bitten by a tick. His initial platelet count was 80,000/ μL (Table 1). Considering the patient's outdoor activities, symptoms, and thrombocytopenia, as well as the fact that SFTS is endemic to Jeju Island, an SFTS test was performed. Two days later, the diagnosis was confirmed, and the patient continued to sag without significant changes in consciousness. A single dose of tocilizumab (480 mg at 8 mg/kg of body weight) was administered as an intravenous infusion over one hour, slightly improving the patient's consciousness. After two days of treatment, the patient exhibited nearly normal levels of consciousness and appropriate responses. The patient was discharged on the sixth day and closely followed up as an outpatient. No post-discharge after-effects were observed (Fig. 1A).

Case 2

A 62-year-old male patient presented to the ER with a three-day history of fever. The patient had no underlying diseases other than hypertension. The patient resided in Gujwa-eup, worked in a garden in front of his house, and indicated that he did not have any tick bites. At the time of hospitalization, the patient had a platelet count of 41,000/ μL and a white blood cell count of 800/ μL . SFTS test results were positive, confirming the diagnosis. Subsequently, his platelet

Table 1. The serial laboratory results of two cases

	Case 1			Case 2			Normal range
	Admission	Discharge	After one month	Admission	Discharge	After one month	
WBC ($/\mu\text{L}$)	2,900	4,300	6,700	800	1,600	4,100	4,000–10,000
ANC ($/\mu\text{L}$)	832	779	3,850	529	209	1,846	
Hb (g/dL)	16.4	14.4	13.3	14.3	15.1	12.6	13–17
PLT ($\times 10^3/\mu\text{L}$)	80	156	304	41	52	196	150–450
ALB (g/dL)	3.6	3.0	4.0	4.1	3.3	4.3	3.8–5.3
ALP (U/L)	387	289	203	125	202	175	104–338
AST (IU/L)	431	88	20	93	413	34	8–38
ALT (IU/L)	315	111	18	58	199	39	4–44
BUN (mg/dL)	25.7	16.6	13.2	30.2	5.5	16.1	8.0–20.0
Cr (mg/dL)	1.02	0.68	0.70	1.16	0.54	0.63	0.80–1.30
CRP (mg/dL)	0.12	0.20		0.38		0.04	0.00–0.30
ESR (mm/h)	19			9			0–9
Ferritin (ng/mL)	> 1,675.56		205.38	> 1,675.56		290.03	21.81–274.66
IL-6 (pg/mL)	13.80		8.75	58.1		< 1.50	≤ 7.0
aPTT (sec)	40			40			20.0–36.0
LDH (U/L)	790			489	1,280		106–211
CPK (U/L)	143			293			56–244

WBC, white blood cell; ANC, absolute neutrophil count; Hb, hemoglobin; PLT, platelet; ALB, albumin; ALP, alkaline phosphatase; AST, aspartate aminotransferase; ALT, alanine transferase; BUN, blood urea nitrogen; Cr, creatinine; CRP, C-reactive protein; ESR, erythrocyte sedimentation rate; IL, interleukin; aPTT, activated partial thromboplastin time; LDH, lactate dehydrogenase; CPK, creatine phosphokinase.

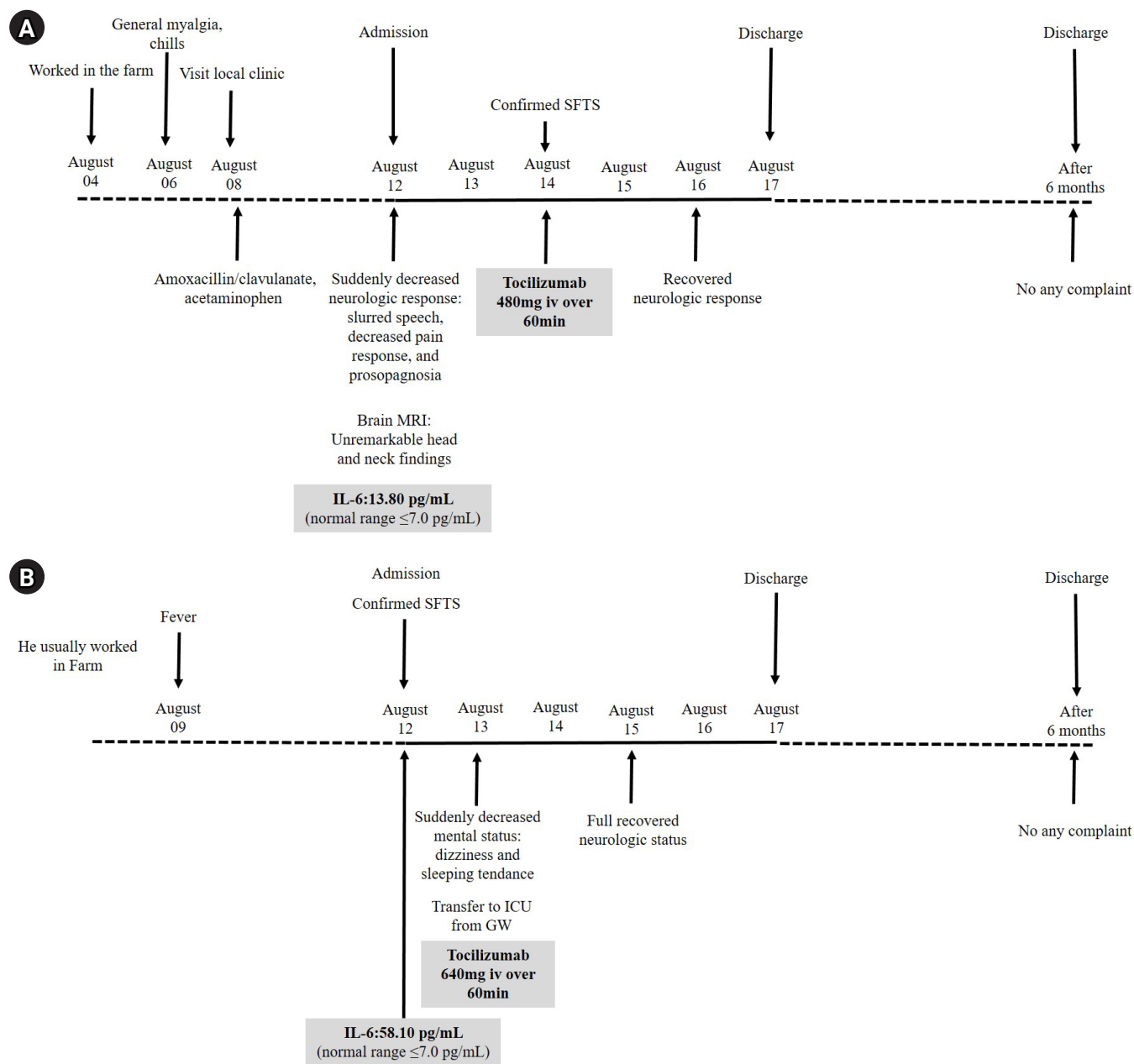


Fig. 1. The timelines of the clinical course following tocilizumab administration in the two patients (Case 1 [A] and Case 2 [B]) with SFTS. SFTS, severe fever with thrombocytopenia syndrome; IL, interleukin.

count further declined to 23,000/ μ L, and the white blood cell count dropped to 700/ μ L (Table 1). The patient presented with dizziness and excessive sleep, necessitating a transfer to the intensive care unit for close monitoring. A single dose of tocilizumab (640 mg, 8 mg/kg of body weight) was administered as an intravenous infusion over one hour in the intensive care unit. By the third day of hospitalization, the patient's consciousness had improved, and blood parameters gradually recovered. The patient was discharged on the sixth day of

hospitalization. Follow-up appointments were scheduled at an outpatient clinic to monitor patient progress. No significant adverse effects or complications were observed after discharge (Fig. 1B).

Discussion

SFTS is a tick-borne zoonotic disease with mortality rates ranging from 12% to 30% in certain areas [1]. Advanced age,

thrombocytopenia, and central nervous system involvement are the major risk factors for mortality in patients with SFTS [7]. Therefore, close monitoring and prompt support are recommended to improve the survival rates. Several studies have identified neurological manifestations such as apathy, lethargy, muscular tremors, delirium, convulsions, seizures, high Glasgow Coma Scale scores, coma, and alterations in consciousness as risk factors for the disease and increased mortality [7]. In South Korea, advanced age and neurological manifestations, particularly decreased consciousness and slurred speech, within the first week of disease onset are strongly associated with death [8]. Both cases involved patients aged > 60 years who exhibited neurological symptoms, including decreased consciousness and slurred speech (Fig. 1).

Currently, there are no established treatment options for patients with SFTS, prompting ongoing research and exploration of various treatment modalities [1]. Some studies have shown that fatal SFTS correlates with elevated IL-6 levels and high viral loads [6]. Tocilizumab's efficacy in treating patients with severe or intubated patients with COVID-19 has been investigated [9,10]. The tocilizumab dose used in our study was based on that administered to patients with COVID-19.

Cytokine storms are associated with several severe viral infections including SFTS and COVID-19. Clinical studies have indicated that certain cytokines, such as IL-6, and TNF- α , were produced at high concentrations in the blood of patients with these conditions [11,12]. A complete understanding of the exact mechanism of IL-6 in the exacerbation of SFTS is still limited; therefore, the authors investigated the role of IL-6 in viral infection and its potential in the treatment of patients with COVID-19. A hypothesis regarding tocilizumab's mechanism of action has been proposed. After severe acute respiratory syndrome coronavirus 2 (SARS-CoV-2) infection, immune cells release cytokines, including IL-6. IL-6 can either attach to its respective cell receptor (IL-6R) or soluble receptor (SIL-6R), activating both the NF- κ B and Janus kinase/signal transducers and activators of transcription (JAK/STAT) pathways that can induce cytokine storm [6]. Tocilizumab can bind to IL-6R and SIL-6R to prevent signal transduction and reduce the risk of cytokine storms [13,14].

In conclusion, SFTS is a severe hemorrhagic viral disease for which several treatment approaches have been attempted. Our observations of two older patients presenting with decreased consciousness who demonstrated improvement following tocilizumab treatment, suggest the potential use of tocilizumab for SFTS. To our knowledge, this is the only published case of SFTS treated with tocilizumab [15]. To evaluate

tocilizumab's effectiveness and safety, further studies in larger patient populations are needed.

Acknowledgements

None.

Ethics approval

This study was approved by the Institutional Review Board (IRB) of the Jeju National University Hospital (IRB file no. 2021-09-010-001). The patients provided written informed consent before enrollment in this study.

Conflict of interest

The authors have nothing to disclose.

Funding

This work was supported by the 2024 Education, Research and Student Guidance Grant funded by Jeju National University.

ORCID

Misun Kim, <https://orcid.org/0000-0003-3771-6101>

Jeong Rae Yoo, <https://orcid.org/0000-0002-5488-7925>

Young Ree Kim, <https://orcid.org/0000-0003-2454-8815>

Sang Taek Heo, <https://orcid.org/0000-0001-8947-5069>

References

1. Seo JW, Kim D, Yun N, Kim DM. Clinical update of severe fever with thrombocytopenia syndrome. *Viruses*. 2021;13:1213.
2. Oh WS, Yoo JR, Kwon KT, Kim HI, Lee SJ, Jun JB, et al. Effect of early plasma exchange on survival in patients with severe fever with thrombocytopenia syndrome: a multicenter study. *Yonsei Med J*. 2017;58:867–71.
3. Wei Q, Lin H, Wei RG, Chen N, He F, Zou DH, et al. Tocilizumab treatment for COVID-19 patients: a systematic review and meta-analysis. *Infect Dis Poverty*. 2021;10:71.
4. Scott LJ. Tocilizumab: a review in rheumatoid arthritis. *Drugs*. 2017;77:1865–79.
5. Stone JH, Tuckwell K, Dimonaco S, Klearman M, Aringer M, Blockmans D, et al. Trial of Tocilizumab in giant-cell arteritis. *N Engl J Med*. 2017;377:317–28.

6. Yoo JR, Kim TJ, Heo ST, Hwang KA, Oh H, Ha T, et al. IL-6 and IL-10 levels, rather than viral load and neutralizing antibody titers, determine the fate of patients with severe fever with thrombocytopenia syndrome virus infection in South Korea. *Front Immunol.* 2021;12:711847.
7. Jie SH, Zhou Y, Sun LP, Liang KW, Yi XL, Li HY. Close correlation between development of MODS during the initial 72 h of hospitalization and hospital mortality in severe fever with thrombocytopenia syndrome. *J Huazhong Univ Sci Technolog Med Sci.* 2013;33:81–5.
8. Shin J, Kwon D, Youn SK, Park JH. Characteristics and factors associated with death among patients hospitalized for severe fever with thrombocytopenia syndrome, South Korea, 2013. *Emerg Infect Dis.* 2015;21:1704–10.
9. Gupta S, Wang W, Hayek SS, Chan L, Mathews KS, Melamed ML, et al. Association between early treatment with Tocilizumab and mortality among critically ill patients With COVID-19. *JAMA Intern Med.* 2021;181:41–51.
10. Somers EC, Eschenauer GA, Troost JP, Golob JL, Gandhi TN, Wang L, et al. Tocilizumab for treatment of mechanically ventilated patients with COVID-19. *Clin Infect Dis.* 2021;73:e445–54.
11. Nakamura S, Iwanaga N, Hara S, Shimada S, Kashima Y, Haya-saka D, et al. Viral load and inflammatory cytokine dynamics associated with the prognosis of severe fever with thrombocytopenia syndrome virus infection: an autopsy case. *J Infect Chemother.* 2019;25:480–4.
12. Coomes EA, Haghbayan H. Interleukin-6 in Covid-19: a systematic review and meta-analysis. *Rev Med Virol.* 2020;30:1–9.
13. Zhang C, Wu Z, Li JW, Zhao H, Wang GQ. Cytokine release syndrome in severe COVID-19: interleukin-6 receptor antagonist Tocilizumab may be the key to reduce mortality. *Int J Antimicrob Agents.* 2020;55:105954.
14. Kaye AG, Siegel R. The efficacy of IL-6 inhibitor Tocilizumab in reducing severe COVID-19 mortality: a systematic review. *PeerJ.* 2020;8:e10322.
15. Yoo JR, Lee KH, Kim M, Oh HJ, Heo ST. Tocilizumab therapy for IL-6 increment in a patient with non-fatal severe fever with thrombocytopenia syndrome. *Int J Infect Dis.* 2022;122:656–8.