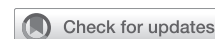

# Robotic repair of atrial septal defect: Pre-groove vertical right atriotomy approach



Kitae Kim, MD,<sup>a</sup> Yun Seok Kim, MD,<sup>b</sup> Hong Rae Kim, MD, PhD,<sup>a</sup> Ho Jin Kim, MD, PhD,<sup>a</sup> Jae Suk Yoo, MD, PhD,<sup>a</sup> Joon Bum Kim, MD, PhD,<sup>a</sup> Sung-Ho Jung, MD, PhD,<sup>a</sup> and Jae Won Lee, MD, PhD<sup>c</sup>

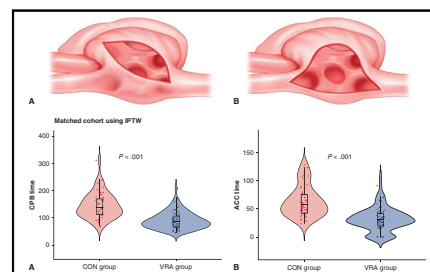
## ABSTRACT

**Objective:** Minimally invasive repair using robotic systems has been accepted as an attractive alternative in the surgical repair of atrial septal defects (ASDs). Clear exposure of the entire rim of the ASD is often hindered during a robotic approach. Here, we describe an approach using vertical right atriotomy along the interatrial groove that may enhance the exposure of the ASD.

**Methods:** Patients who underwent ASD closure using the da Vinci Si surgical system (Intuitive Surgical) from 2007 to 2021 were included. During ASD closure procedures, right atriotomy was performed either conventionally in an oblique manner or parallel to the interatrial groove. A comparative analysis was performed in terms of all-cause mortality, complications, and durations of cardiopulmonary bypass, aortic crossclamp, intensive care unit stay, and hospital stay. The inverse probability of treatment weighting was utilized to balance baseline characteristics across different surgical approaches.

**Results:** A total of 114 consecutive patients (mean age,  $38.7 \pm 12.8$  years) constituted the study cohort. There were no cases of mortality or surgical complications in either group. After adjusting for potential covariates, the cardiopulmonary bypass ( $92.8 \pm 31.5$  minutes vs  $143.1 \pm 40.7$  minutes) and aortic crossclamp ( $30.7 \pm 21.3$  minutes vs  $60.8 \pm 23.5$  minutes) times were significantly shorter in the group using vertical right atriotomy than in the group using conventional approach ( $P < .001$  for both).

**Conclusions:** Performing vertical right atriotomy adjacent to the interatrial groove optimized ASD exposure compared with the conventional approach during robotic ASD repair, leading to reduced cardiopulmonary bypass and aortic crossclamp times. (JTCVS Techniques 2024;28:73-81)



Surgical view and CPB/ACC time according to right atrium incision in the setting of ASD closure.

## CENTRAL MESSAGE

During the robotic repair of ASD, performing VRA adjacent to the interatrial groove improved exposure of the ASD compared with the conventional approach, resulting in reduced CPB and ACC times.

## PERSPECTIVE

Robotic-assisted minimally invasive repair is an appealing option for ASD surgery; however, obtaining clear exposure of the entire ASD rim can be challenging with a totally endoscopic approach. The present study may offer insights into assessing the necessity of vertical right atriotomy by evaluating its effectiveness in the context of robotic ASD repair.

Atrial septal defect (ASD) is a common form of congenital heart defect, accounting for approximately 7.5% to 15% of all cases of congenital cardiac diseases.<sup>1-3</sup> ASDs diagnosed

in infancy or early adulthood with small diameters tend to close spontaneously. However, if moderate or large ASDs are left uncorrected, they can lead to left-to-right shunting,

From the <sup>a</sup>Department of Thoracic and Cardiovascular Surgery, Asan Medical Center, University of Ulsan College of Medicine, Seoul, South Korea; <sup>b</sup>Department of Thoracic and Cardiovascular Surgery, Keimyung Medical Center, University of Keimyung College of Medicine, Daegu, South Korea; and <sup>c</sup>Department of Thoracic and Cardiovascular Surgery, Sejong General Hospital, Bucheon-si, Gyeonggi-do, South Korea.

Institutional Review Board approval: #2022-0220.

Received for publication March 21, 2024; revisions received May 6, 2024; accepted for publication May 19, 2024; available ahead of print June 10, 2024.

Address for reprints: Jae Won Lee, MD, PhD, Department of Thoracic and Cardiovascular Surgery, Sejong General Hospital, 28, Hohyeon-ro 489beon-gil, Sosa-gu, Bucheon, 14754, South Korea (E-mail: [jwlee@amc.seoul.kr](mailto:jwlee@amc.seoul.kr)).

2666-2507

Copyright © 2024 The Authors. Published by Elsevier Inc. on behalf of The American Association for Thoracic Surgery. This is an open access article under the CC BY-NC-ND license (<http://creativecommons.org/licenses/by-nc-nd/4.0/>). <https://doi.org/10.1016/j.xjtc.2024.05.022>

**Abbreviations and Acronyms**

ACC	= aortic crossclamp
ASD	= atrial septal defect
CON	= conventional
CPB	= cardiopulmonary bypass
ePTFE	= expanded polytetrafluoroethylene
IPTW	= inverse probability of treatment weighting
IVC	= inferior vena cava
SMD	= standardized mean difference
SVC	= superior vena cava
TEE	= transesophageal echocardiography
TR	= tricuspid regurgitation
VRA	= vertical right atriotomy

resulting in volume overload, heart failure, atrial arrhythmia, and pulmonary hypertension, typically between the third and fourth decades of life.<sup>4</sup>

Minimally invasive repair using a robotic system has been accepted as an attractive alternative for the surgical repair of ASD.<sup>5-9</sup> It can minimize the incision size and overall operative trauma, leading to better postoperative recovery and an improved quality of life compared to the mini-thoracotomy and median sternotomy approach.<sup>6</sup>

Nevertheless, achieving clear exposure of the entire rim of the ASD under a totally endoscopic robotic approach might be challenging. During robotic ASD closure, we utilize both a 30° and a 0° scope to assess the ASD (Figure 1). However, the standard oblique right atriotomy may impede the view of the ASD due to the free wall of the right atrium (Figures 2 and 3). We hypothesized that performing vertical right atriotomy (VRA) parallel to the interatrial groove would provide better exposure of the entire interatrial septum compared with performing a conventional oblique incision in the right atrium (CON). In the current study, we evaluated the postoperative outcomes of a novel approach using robotic-assisted VRA parallel to the interatrial groove for ASD.

**METHODS****Study Design and Population**

With approval from the Institutional Review Board of Asan Medical Center (Study No: 2022-0220; February 18, 2022), we retrospectively reviewed patients' medical records. Informed consent was waived due to retrospective nature using anonymous data. We identified all patients at Asan Medical Center who underwent ASD closure using the da Vinci Si surgical system (Intuitive Surgical) from 2007 to 2021 (N = 156), excluding patients who underwent concomitant mitral valve surgery (n = 22), from electronic medical records to focus on evaluating the effectiveness of the right atriotomy incision. Patients were categorized into either the CON group or the VRA group based on the technique of right atriotomy.

**Data Acquisition and End Points**

We compared all-cause mortality, postoperative complications, duration of cardiopulmonary bypass (CPB) and aortic crossclamping (ACC),

intensive care unit stay, and hospital stay between the CON (n = 54) and VRA (n = 80) groups. Postoperative complications included reoperation for bleeding, complete atrioventricular block, cerebrovascular accident, wound infection, pneumonia, and remnant interatrial shunt.

**Echocardiographic Evaluations**

All patients underwent a transthoracic method to measure Doppler color flow and intra-cardiac 2-dimensional images within 2 months before the surgery. The addition of transesophageal echocardiography (TEE) was decided by the attending physicians. The degree of tricuspid regurgitation (TR) was classified as mild, moderate, or severe based on the distal jet area, vena contracta width, proximal convergence analysis, and volumetric quantitation following the American Society of Echocardiography guidelines.<sup>10-12</sup> The TR velocity and amounts were measured using the continuous-wave Doppler method in the apical 4-chamber view, and the TR peak pressure gradient was calculated using the simplified Bernoulli equation ( $4 \times [\text{velocity}^2]$ ). Postoperative echocardiography was typically performed 3 days after surgery. Follow-up echocardiography was typically conducted at 6 months postoperatively; thereafter, echocardiographic tests were performed annually or biennially. Qp/Qs was calculated in patients with significant pulmonary hypertension before surgery using cardiac flow assessment.

**Surgical Indication**

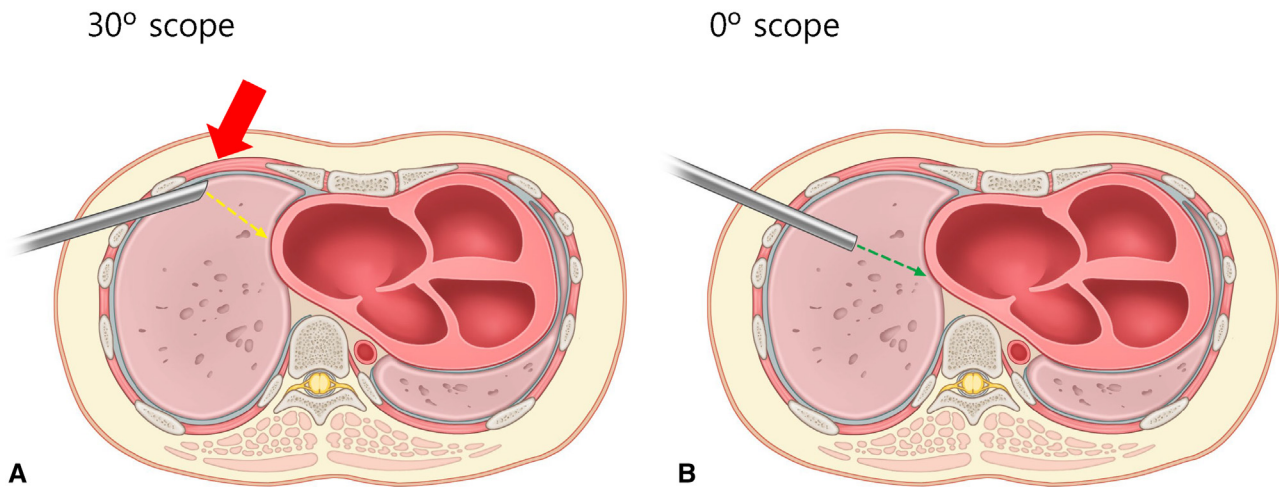
Surgical indication is based on the 2018 the American College of Cardiology and the American Heart Association Guideline for the Management of Adults with Congenital Heart Disease.<sup>13</sup> An ASD observed on echocardiography with a left-to-right shunt requires surgical or interventional procedures. In cases of right ventricle volume overflow or paradoxical embolism, aggressive surgical or interventional procedures are planned. Furthermore, Qp/Qs is calculated by cardiac flow evaluation in cases of significant pulmonary hypertension to ascertain whether the degree of shunt causes physiological consequences.

Available percutaneously deployed ASD closure devices have been authorized for the closure of secundum type defects. Primum, sinus venosus, and coronary sinus ASDs should be closed surgically due to the lack of sufficient rims for percutaneous device implantation and the proximity to the atrioventricular valves and conduction system to the closure device. If concurrent surgical ablation or valve surgery is required due to accompanying diseases, or if the defect is numerous or has an aneurysmal change, surgery assumes priority over procedures in secundum type of ASD.

If a preoperative assessment indicates pulmonary vascular hypertension more than one-third of systemic vascular resistance and/or pulmonary artery systolic pressure >50% of systemic pressure, a consultation with a respiratory physician is sought to decide the treatment approach. If Eisenmenger syndrome has been identified, medical treatment is preferred over surgery.

**Surgical Procedures**

We have previously outlined the standard operative procedure for robotic-assisted cardiac surgery in our previous studies.<sup>14-16</sup> During general anesthesia, patients are intubated with a double-lumen endotracheal tube to facilitate left-sided single-lung ventilation. External defibrillator patches (Quik-Combo; Physio-Control Co) were used for defibrillation. A TEE probe, a radial arterial pressure monitoring line, and a central venous catheter were inserted. A 17 to 21 Fr DLP femoral arterial cannula (Medtronic) was percutaneously inserted into the right internal jugular vein after heparinization (30 IU/kg). Patients were positioned in the left semilateral decubitus posture with the right arm secured to the table. Before 2016, femoral artery and vein cannulation were performed through a 3- to 4-cm inguinal groin incision. Since 2016, we have utilized the percutaneous Seldinger approach with the Perclose ProGlide suture-mediated closure device for femoral vessel cannulation (Abbott Vascular).



**FIGURE 1.** Comparison between the da Vinci 30° scope (Intuitive Surgical) (A) and 0° scope (B).

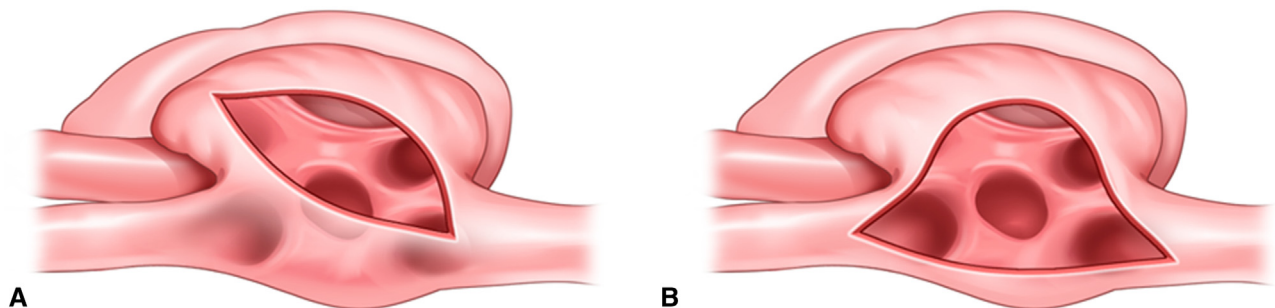
The thoracoscopic port incision was made in the fourth intercostal space, anterior to the anterior axillary line. Two additional port incisions were made in the third intercostal space (just anterior to the anterior axillary line) and in the sixth intercostal space (posterior to the anterior axillary line) for the left and right robotic arms, respectively. A working port was placed in the fourth intercostal space at the anterior axillary line, near the center of the triangle formed by the 3 ports for the left and right robotic arms and scope. The fifth port for the atrial retractor was positioned in the fourth or fifth intercostal space at the midclavicular line. After docking the da Vinci Si surgical system, a 0° scope was inserted through the thoracoscopic port. A Chitwood clamp (Scanlan International Inc) was inserted through the third intercostal space as posterior as possible to the midaxillary line to prevent interference between instruments. After initiating CPB, a pericardiotomy was performed, and pericardial stay sutures were placed. A root cannula was inserted after applying 4-0 double-armed pledgeted sutures to the ascending aorta. During the reduction of perfusion pressure, aortic crossclamping was performed. In some cases, the Glauber aortic clamp (Sorin Group) was applied without additional incisions.<sup>14</sup> Cardioplegic solution (2000 mL custodiol histidine-tryptophan-ketoglutarate solution; Odyssey Pharmaceuticals) was administered through the aortic root cannula.<sup>14</sup>

The superior vena cava (SVC) was clamped using a bulldog clamp. In the CON group ( $n = 54$ ), the right atrium was opened obliquely toward the inferior vena cava (IVC) (Figure 2, A, Figure 3, A, and Figure E1). In the VRA approach group ( $n = 80$ ), the fat tissue over the interatrial groove was dissected, and the right atrium was opened along the interatrial groove from the IVC side to the SVC side (Figure 2, B, Figure 3, B, and Figure E1). To protect the sinoarterial node, a careful incision is performed around the

lower part of the SVC where it meets the right atrium after properly elevating the right atrium. To avoid SVC stenosis, the incision is often limited to the junction of the SVC and the right atrium. Negative pressure ( $-50$  to  $-60$  mm Hg) was applied to the IVC to drain venous blood. The ASD was repaired using either the primary suture technique (4-0 expanded polytetrafluoroethylene [ePTFE] suture) or the patch technique (0.5 mm ePTFE patch with 4-0 ePTFE running suture) after elevating the right atrium-free wall with a retractor. When patch repair was needed, the patch was anchored to the anteroinferior rim of the ASD (2 o'clock from the surgeon's view) using double-arm 4-0 ePTFE, and a continuous running suture then proceeded to the anterior and superior rim first with an arm of the 4-0 ePTFE. Then, using the other arm of the 4-0 ePTFE, continuous running sutures were placed along the inferior and posterior rim. The left atrium was de-aired by inflating the left lung, the suture was tied, and the aorta was unclamped. The right atriotomy was closed using a double-layer 4-0 polypropylene running suture, and the patient was successfully weaned off CPB. The repaired interatrial septum was reviewed using TEE, and protamine was administered. Concurrent tricuspid valve repair techniques were primarily selected based on the surgeon's preference.

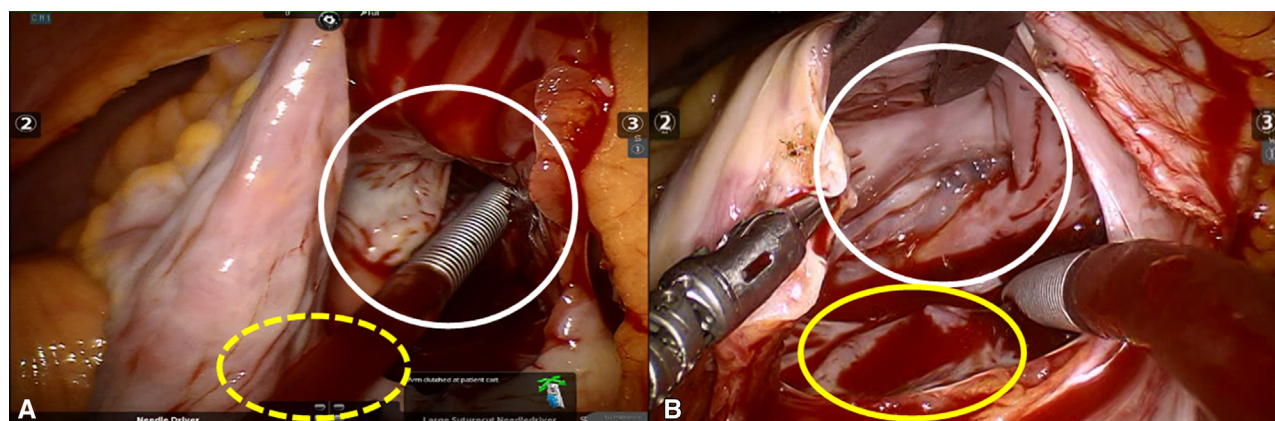
### Statistical Analysis

Continuous variables are presented as mean  $\pm$  SD, and nonnormally distributed variables, as determined by the Shapiro-Wilk normality test, are presented as medians with interquartile range (IQR). Categorical variables are presented as frequencies and percentages. Continuous variables were compared using Student  $t$  test or Mann-Whitney  $U$  test, whereas categorical variables were compared using  $\chi^2$  and Fisher exact tests.



**FIGURE 2.** Surgical view with conventional oblique atriotomy (A) and vertical right atriotomy (B).





**FIGURE 3.** Intraoperative image with conventional oblique atriotomy (A) and vertical right atriotomy (B). The *white circle* represents the position of the tricuspid valve, and the *yellow circle* represents the location of the atrial septal defect.

A propensity score methodology with inverse probability of treatment weighting (IPTW) was performed to minimize selection bias and balance baseline characteristics.<sup>17</sup> The propensity score was defined as the probability of a patient undergoing ASD closure using the da Vinci Si surgical system conditional on baseline and operative profiles, and it was estimated using multiple logistic regression analysis. Covariates for adjustment included age, sex, body mass index, hemoglobin level, albumin level, diabetes mellitus, hypertension, cerebrovascular accident, estimated glomerular filtration rate, chronic kidney disease, preoperative atrial fibrillation, Hallor index, left atrium size, ejection fraction, tricuspid regurgitation grade, tricuspid regurgitation pressure gradient, sinus venosus ASD, multiple ASD, patch closure, tricuspid ring annuloplasty, tricuspid valvuloplasty using De Vega technique, and operation period. The Haller index was calculated by dividing the transverse diameter of the chest by the anterior-posterior distance on computed tomography of the chest on the axial slice that had the smallest distance between the anterior surface of the vertebral body and the posterior surface of the sternum.<sup>18,19</sup>

After conducting IPTW-based trimming to stabilize weights, the balance of all covariates was assessed using the standardized mean difference (SMD), with SMDs <20% deemed indicative of adequate balance.<sup>20</sup> Violin plots were utilized to provide a detailed understanding of CPB and ACC times. All analyses were performed using R software, version 4.2.1 (R Foundation for Statistical Computing).

## RESULTS

### Baseline Characteristics and Surgical Procedures

A total of 134 patients were analyzed in this study. Based on the technique of right atriotomy, 54 (40.3%) patients were classified as the CON group, and 80 (59.7%) patients were classified as the VRA group. The clinical characteristics of both groups before and after IPTW weighting are presented in Table 1. The characteristics of the two groups were well balanced after IPTW weighting. All covariates used in the IPTW model yielded acceptable balance after adjustment (SMD < 0.2).

### Clinical Outcomes According to Right Atriotomy Incision

During a median follow-up of 2.75 years (IQR, 1.05-5.99 years); 2.81 years (IQR, 1.21-5.40 years) in the VRA group and 2.14 (IQR, 0.87-7.15 years) in the CON group,

there were no adverse events, including all-cause death and complications (eg, reoperation for bleeding, complete atrioventricular block, cerebrovascular accident, wound infection, and pneumonia), except for postoperative remnant ASD (Table 2). Postoperative remnant interatrial shunt, which was assessed after a median of 3 days (range, 2-10 days), was significantly lower in the VRA group (2.0% vs 11.2%;  $P = .017$ ) although the amount of shunt flow was trivial. On the final echocardiography, at a median of 454 days (IQR, 183-826 days), only 1 patient had remnant interatrial shunt with trivial flow in CON group (0.0% vs 1.4%;  $P = .23$ ) and there was no patient with significant interatrial shunt (Table 2). There were no cases of SVC constriction observed in the VRA group.

Before and after IPTW adjustment, the CPB and ACC times were considerably shorter in the VRA group (Figure 4). In contrast, there were no significant differences in the durations of intensive care unit or hospital stay before or after IPTW adjustment (Table 2).

## DISCUSSION

The present study compared the surgical outcomes of the conventional oblique and VRA approaches for robotic repair of ASD. Although both surgical approaches demonstrated excellent clinical outcomes without any complications or deaths, the VRA approach was superior in terms of the reduction in CPB and ACC times compared with the conventional oblique right atriotomy approach (Figure 5).

Robotic surgical techniques allow surgeons to close ASDs in a completely endoscopic manner with a high success rate and low complication rate.<sup>21</sup> This approach has increased patient satisfaction due to minimal incisions and enhanced quality of life.<sup>6</sup> In addition, the use of a 3-dimensional endoscopic camera during robotic surgery provides precise depth perception and optimal visibility of intracardiac structures, leading to reduced operation time and improved surgical outcomes.<sup>9,22-24</sup> However,

TABLE 1. Baseline characteristics of patients according to right atriotomy incision

Variable	Before adjustment				After adjustment			
	CON group (n = 54)	VRA group (n = 80)	P value	SMD	CON group (n = 54)	VRA group (n = 80)	P value	SMD
<b>Baseline profiles</b>								
Age (y)	36.3 ± 13.5	40.4 ± 12.2	.074	0.314	37.1 ± 14.3	39.1 ± 11.9	.496	0.156
Female sex	40 (74.1)	63 (78.8)	.674	0.11	40.5 (74.9)	61.1 (76.4)	.88	0.033
BMI	22.45 ± 3.30	22.88 ± 3.75	.494	0.122	22.60 ± 3.41	22.58 ± 3.61	.979	0.005
Hb (g/dL)	13.58 ± 1.29	13.16 ± 1.82	.148	0.265	13.41 ± 1.39	13.33 ± 1.78	.817	0.05
Albumin (g/dL)	4.17 ± 0.30	4.06 ± 0.28	.032	0.38	4.09 ± 0.27	4.09 ± 0.28	.925	0.018
DM	1 (1.9)	2 (2.5)	>.99	0.044	1.5 (2.7)	2.0 (2.5)	.953	0.012
HTN	2 (3.7)	4 (5.0)	>.99	0.064	3.0 (5.6)	4.0 (5.0)	.892	0.029
CVA	0 (0)	0 (0)	>.99	<0.001	0 (0)	0 (0)	>.99	<0.001
eGFR	86.19 ± 6.78	83.92 ± 8.86	.115	0.286	85.08 ± 7.74	84.95 ± 8.20	.94	0.016
CKD	0 (0)	0 (0)	>.99	<0.001	0 (0)	0 (0)	>.99	<0.001
Preoperative AF	0 (0)	0 (0)	>.99	<0.001	0 (0)	0 (0)	>.99	<0.001
Haller index	2.52 ± 0.43	2.51 ± 0.39	.804	0.043	2.55 ± 0.41	2.52 ± 0.39	.691	0.079
<b>Echocardiographic data</b>								
LA (mean (SD)), mm	36.04 ± 6.25	35.90 ± 4.23	.88	0.026	35.72 ± 5.70	35.83 ± 4.05	.905	0.022
EF (%)	61.96 ± 5.81	62.76 ± 3.82	.338	0.163	62.21 ± 5.53	62.66 ± 3.85	.642	0.094
TR grade			.312	0.342			.996	0.05
None to trivial	8 (14.8)	22 (27.5)			12.3 (22.8)	18.6 (23.2)		
Mild	26 (48.1)	37 (46.2)			25.6 (47.3)	39.3 (49.1)		
Moderate	19 (35.2)	20 (25.0)			15.2 (28.2)	20.8 (26.1)		
TR pressure gradient	1 (1.9)	1 (1.2)			0.9 (1.7)	1.3 (1.6)		
Significant pulmonary HTN	7 (13.0)	8 (10.0)	.799	0.093	5.6 (10.4)	6.6 (8.2)	.662	0.075
Systemic flow ratio (Qp/Qs)*	2.56 (0.38)	2.44 (0.40)	.559	0.311	2.58 (0.36)	2.43 (0.37)	.394	0.408
ASD diameter†	26.28 (12.69)	27.02 (9.71)	.70	0.066	27.61 (15.48)	26.30 (9.64)	.672	0.102
<b>Operative profiles</b>								
Sinus venous ASD	3 (5.6)	2 (2.5)	.652	0.156	2.0 (3.6)	2.1 (2.7)	.74	0.055
Multiple ASD	10 (18.5)	17 (21.2)	.867	0.068	13.6 (25.2)	16.3 (20.4)	.614	0.114
Patch closure	45 (83.3)	72 (90.0)	.383	0.197	46.0 (85.2)	66.6 (83.3)	.817	0.052
Tricuspid valvuloplasty								
Ring annuloplasty	1 (1.9)	3 (3.8)	.908	0.115	3.2 (5.8)	2.7 (3.4)	.637	0.115
De Vega technique	8 (14.8)	8 (10.0)	.568	0.146	6.1 (11.3)	8.6 (10.7)	.922	0.018
Operation period			<.001	0.933			.951	0.014
2008-2015	45 (83.3)	34 (42.5)			31.9 (59.1)	46.7 (58.4)		
2016-2021	9 (16.7)	46 (57.5)			22.1 (41.0)	33.3 (41.7)		

Values are presented as n (%) or mean ± SD. CON, Conventional approach; VRA, vertical right atriotomy; SMD, standardized mean difference; BMI, body mass index; Hb, hemoglobin; DM, diabetes mellitus; HTN, hypertension; CVA, cerebrovascular accident; eGFR, estimated glomerular filtration rate; CKD, chronic kidney disease; AF, atrial fibrillation; LA, left atrium; EF, ejection fraction; TR, tricuspid regurgitation; ASD, atrial septal defect. \*Qp/Qs was calculated in patients with significant pulmonary hypertension before surgery (n = 15). †The ASD diameter of the patient with multiple ASDs was calculated as the sum of the diameters.

achieving optimal exposure of the ASD under a completely endoscopic robotic approach may present challenges. Conventionally, a 30° downward scope was used to maximize ASD visualization, but it can be obstructed by the anterior chest wall, especially in patients with small thoracic cages (Figure 1, A). In those cases, a 0° scope can be used to avoid colliding with the anterior chest wall; however, it has a limitation in visualizing the posterior rim of the ASD (Figure 1, B, Figure 2, A, and Figure 3, A). To overcome this issue, the VRA along the interatrial groove was performed (Figure 2, B and Figure 3, B), which can be applied to all types of ASD to optimize defect exposure. For instance, the sinus venous type of ASD

can be exposed by extending the incision to the SVC or IVC side, as needed.

In this study, the VRA approach was associated with a shorter surgery time. Specifically, good visualization facilitated beating heart surgery in 13 patients from the VRA group, contributing to a reduction in surgical time. In previous studies, beating heart surgery has shown faster recovery, myocardial protection, and shorter CPB and total operation times in robotic ASD closure surgery.<sup>9,25</sup> However, we did not find significant differences in all-cause mortality, post-operative complications, and intensive care unit or hospital stay between the CON group and VRA group, likely due to the excellent outcomes of robotic ASD repair surgery.<sup>6,7,9</sup>

TABLE 2. Comparison of clinical outcomes according to right atriotomy incision in patients using inverse probability of treatment weighting

Variable	Before adjustment			After adjustment		
	CON group (n = 54)	VRA group (n = 80)	P value	CON group (n = 54)	VRA group (n = 80)	P value
Cardiopulmonary bypass time (min)	145.5 ± 47.4	91.5 ± 31.8	<.001	143.1 ± 40.7	92.8 ± 31.5	<.001
Aortic crossclamp time (min)	63.5 ± 27.1	31.5 ± 21.5	<.001	60.8 ± 23.5	30.7 ± 21.3	<.001
ICU stay (d)	1.02 ± 0.14	1.05 ± 0.45	.617	1.02 ± 0.13	1.06 ± 0.50	.485
Hospital stay (d)	4.78 ± 2.13	4.91 ± 1.88	.701	4.96 ± 2.02	4.77 ± 1.93	.594
Early mortality	0 (0)	0 (0)	>.99	0 (0)	0 (0)	>.99
Late mortality per year	0 (0)	0 (0)	>.99	0 (0)	0 (0)	>.99
Early complication	0 (0)	0 (0)	>.99	0 (0)	0 (0)	>.99
Late complication per year	0 (0)	0 (0)	>.99	0 (0)	0 (0)	>.99
Remnant shunt*						
Postoperative shunt	7 (13.0)	2 (2.5)	.043	6.0 (11.2)	1.6 (2.0)	.017
Last follow-up shunt	1 (1.9)	0 (0.0)	.843	0.8 (1.4)	0.0 (0.0)	.232

Values are presented as n (%) or mean ± SD unless indicated otherwise. CON, Conventional approach; VRA, vertical right-atriotomy approach; ICU, intensive care unit.

\*Remnant shunt was observed in 9 patients with trivial shunt flow.

TR is a common pathophysiologic condition in adult patients with ASD due to tricuspid annulus dilation and right ventricle remodeling secondary to long-standing right heart volume overload and left-to-right shunting.<sup>26,27</sup> Approximately 30% of patients in this study demonstrated significant TR, which is consistent with a prior study conducted in Korea.<sup>28</sup> In the group of 20 patients who underwent both ASD repair surgery and tricuspid valvuloplasty, the VRA incision also resulted in a shorter ACC time ( $58.6 \pm 29.2$  minutes vs  $82.6 \pm 27.0$  minutes) and CPB time ( $135.4 \pm 35.6$  minutes vs  $161.9 \pm 35.3$  minutes) than the CON incision, although the difference was marginally significant ( $P = .11$  and  $P = .07$ , respectively) due to the small sample size. With the rise of device closure,

surgery for adult ASD is decreasing in volume; however, the number of significant TR cases is increasing.<sup>29</sup> The VRA incision may be beneficial for concomitant tricuspid valve intervention by providing optimal exposure of both ASD and the tricuspid valve.

This study has several limitations. First, because this study was conducted retrospectively at a single tertiary center, potential selection bias might have influenced our results. The results might also have been influenced by interobserver variation in the determination of ASD and the degree of TR severity, as is always the case in this field. In addition, as this study focused on patients who received surgical treatment from a single surgeon over a 14-year period, unmeasured confounders such as

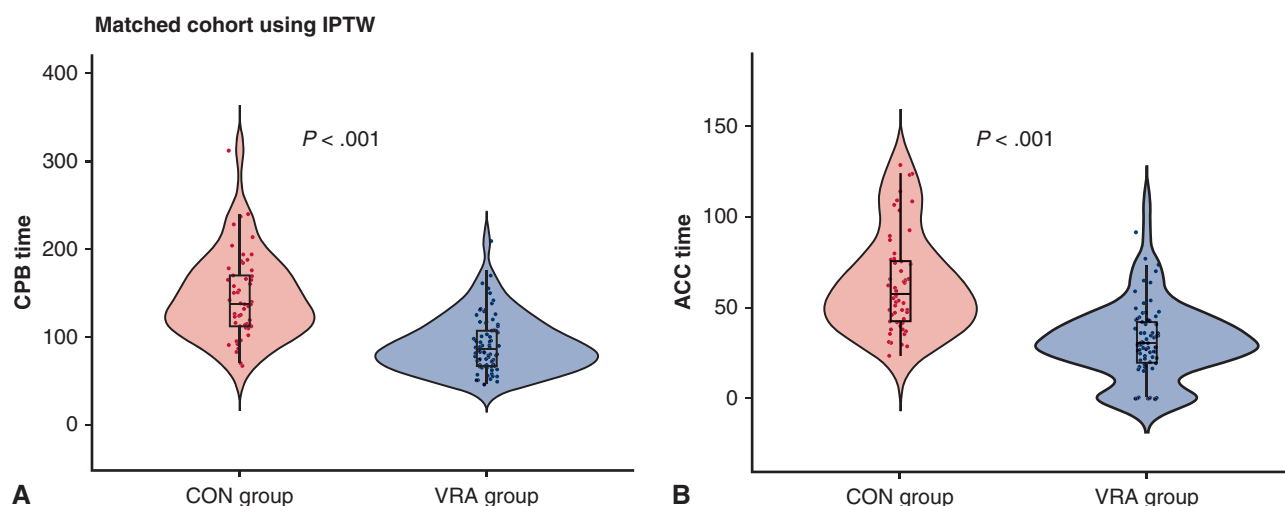
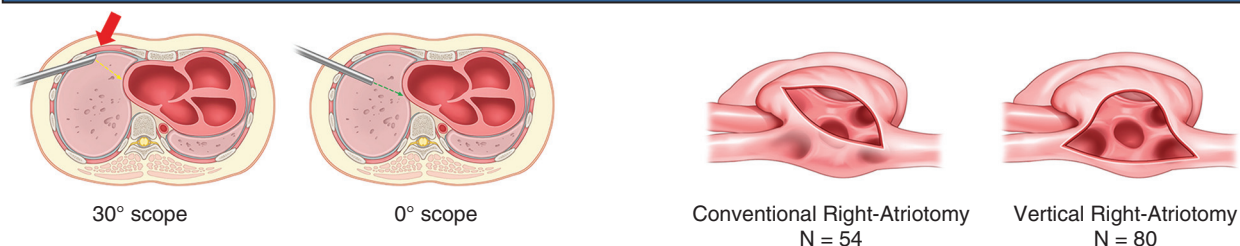


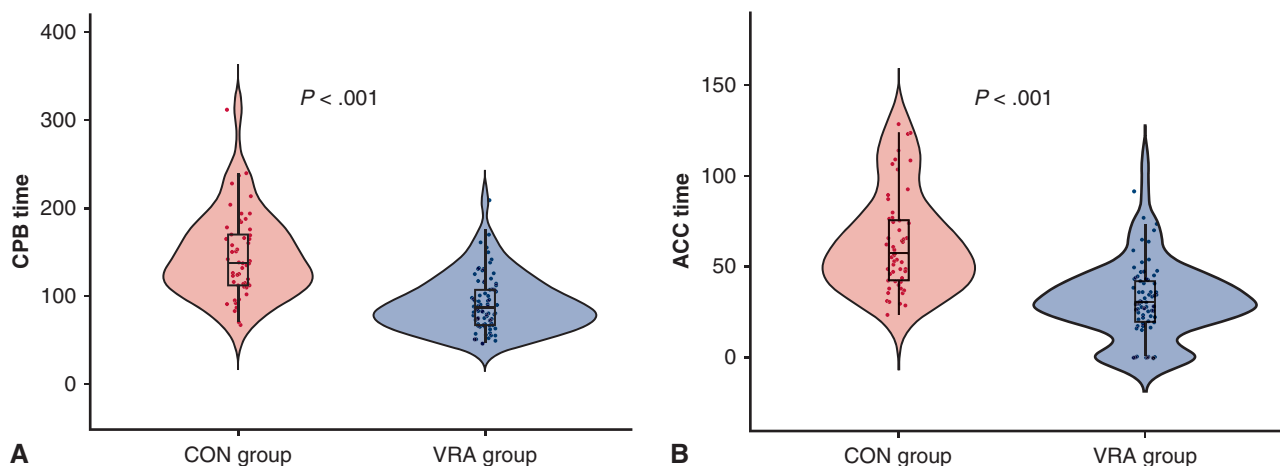
FIGURE 4. Violin plot comparing the cardiopulmonary bypass (CPB) and aortic crossclamp (ACC) times between the oblique right atriotomy group (CON) and the vertical right atriotomy group (VRA). IPTW, Inverse probability of treatment weighting.

### Robotic Repair of Atrial Septal Defect: Pre-Groove Vertical Right-Atriotomy Approach



Adult patient who underwent ASD closure using the Da Vinci Si® surgical system (Jan/2007-Dec/2021)  
N = 134

#### Matched cohort using IPTW



VRA adjacent the interatrial groove optimized ASD exposure compared to the conventional approach during the robotic repair of ASD, resulting in reduced CPB and ACC time.

**FIGURE 5.** Overview of the study on robotic repair of atrial septal defect: pre-groove vertical right-atriotomy approach.

surgical expertise, learning curves, and advancements in medical devices may not have been fully considered. Particularly, although we weighted VRA group and CON group using IPTW, there was also a learning curve or accumulation of experience, which may have an influence on ACC and CPB times. Notably, the potential risk associated with VRA incision, such as overly deep cuts extending into the left atrium or risk of sinoarterial node injury, could have been minimized in this study with the expertise of the surgeon. Moreover, the number of patients included in this study was not sufficiently large to provide a robust conclusion; therefore, the results should be interpreted as hypothesis-generating.

### CONCLUSIONS

Performing VRA adjacent to the interatrial groove optimized ASD exposure compared with the conventional approach during robotic repair of ASD, resulting in reduced CPB and ACC times.

### Conflict of Interest Statement

The authors reported no conflicts of interest.

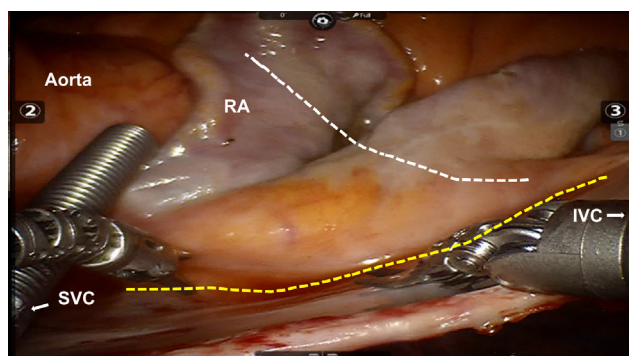
The *Journal* policy requires editors and reviewers to disclose conflicts of interest and to decline handling or reviewing manuscripts for which they may have a conflict of interest. The editors and reviewers of this article have no conflicts of interest.

## References

- van der Linde D, Konings EE, Slager MA, et al. Birth prevalence of congenital heart disease worldwide: a systematic review and meta-analysis. *J Am Coll Cardiol*. 2011;58:2241-2247.
- Thompson E. Atrial septal defect. *JAAPA*. 2013;26(6):53-54.
- Yoo BA, Kwon SJ, Im Y-M, et al. Characteristics of patients with surgical closure of an atrial septal defect during infancy. *J Chest Surg*. 2023;56:155-161.
- Webb G, Gatzoulis MA. Atrial septal defects in the adult. *Circulation*. 2006;114:1645-1653.
- Argenziano M, Oz MC, Kohmoto T, et al. Totally endoscopic atrial septal defect repair with robotic assistance. *Circulation*. 2003;108(Suppl 1):Ii191-Ii194.
- Morgan JA, Peacock JC, Kohmoto T, et al. Robotic techniques improve quality of life in patients undergoing atrial septal defect repair. *Ann Thorac Surg*. 2004;77:1328-1333.
- Bonaros N, Schachner T, Oehlinger A, et al. Robotically assisted totally endoscopic atrial septal defect repair: insights from operative times, learning curves, and clinical outcome. *Ann Thorac Surg*. 2006;82:687-693.
- Gao C, Yang M, Wang G, Wang J. Totally robotic resection of myxoma and atrial septal defect repair. *Interact Cardiovasc Thorac Surg*. 2008;7:947-950.
- Xiao C, Gao C, Yang M, et al. Totally robotic atrial septal defect closure: 7-year single-institution experience and follow-up. *Interact Cardiovasc Thorac Surg*. 2014;19:933-937.
- Mitchell C, Rahko PS, Blauwet LA, et al. Guidelines for performing a comprehensive transthoracic echocardiographic examination in adults: recommendations from the American Society of Echocardiography. *J Am Soc Echocardiogr*. 2019;32:1-64.
- Hahn RT, Abraham T, Adams MS, et al. Guidelines for performing a comprehensive transthoracic echocardiographic examination: recommendations from the American Society of Echocardiography and the Society of Cardiovascular Anesthesiologists. *Anesth Analg*. 2014;118:21-68.
- Gonzalez-Vilchez F, Zarauza J, Vazquez de Prada JA, et al. Assessment of tricuspid regurgitation by Doppler color flow imaging: angiographic correlation. *Int J Cardiol*. 1994;44:275-283.
- Stout KK, Daniels CJ, Aboulhosn JA, et al. 2018 AHA/ACC guideline for the management of adults with congenital heart disease: a report of the American College of Cardiology/American Heart Association Task Force on Clinical Practice Guidelines. *Circulation*. 2019;139:e698-e800.
- Yoo JS, Kim JB, Jung S-H, et al. Mitral durability after robotic mitral valve repair: analysis of 200 consecutive mitral regurgitation repairs. *J Thorac Cardiovasc Surg*. 2014;148:2773-2779.
- Kim HJ, Kim JB, Jung SH, Lee JW. Clinical outcomes of robotic mitral valve repair: a single-center experience in Korea. *Ann Cardiothorac Surg*. 2017;6:9-16.
- Ju MH, Huh JH, Lee CH, et al. Robotic-assisted surgical ablation of atrial fibrillation combined with mitral valve surgery. *Ann Thorac Surg*. 2019;107:762-768.
- Austin PC. The performance of different propensity score methods for estimating marginal odds ratios. *Stat Med*. 2007;26:3078-3094.
- van der Merwe J, Casselman F, Stockman B, Vermeulen Y, Degrieck I, Van Praet F. Endoscopic atrioventricular valve surgery in adults with difficult-to-access uncorrected congenital chest wall deformities. *Interact Cardiovasc Thorac Surg*. 2016;23:851-855.
- Haller JA Jr, Kramer SS, Lietman SA. Use of CT scans in selection of patients for pectus excavatum surgery: a preliminary report. *J Pediatr Surg*. 1987;22:904-906.
- Stuart EA. Matching methods for causal inference: a review and a look forward. *Stat Sci*. 2010;25:1-21.
- Yao DK, Chen H, Ma LL, Ma ZS, Wang LX. Totally endoscopic atrial septal repair with or without robotic assistance: a systematic review and meta-analysis of case series. *Heart Lung Circ*. 2013;22:433-440.
- Ma ZS, Dong MF, Yin QY, Feng ZY, Wang LX. Totally thoracoscopic repair of atrial septal defect without robotic assistance: a single-center experience. *J Thorac Cardiovasc Surg*. 2011;141:1380-1383.
- Torracca L, Ismeno G, Alfieri O. Totally endoscopic computer-enhanced atrial septal defect closure in six patients. *Ann Thorac Surg*. 2001;72:1354-1357.
- Wimmer-Greinecker G, Dogan S, Aybek T, et al. Totally endoscopic atrial septal repair in adults with computer-enhanced telemanipulation. *J Thorac Cardiovasc Surg*. 2003;126:465-468.
- Yun T, Kim H, Sohn B, Chang HW, Lim C, Park KH. Robot-assisted repair of atrial septal defect: a comparison of beating and non-beating heart surgery. *J Chest Surg*. 2022;55:55-60.
- Geva T, Martins JD, Wald RM. Atrial septal defects. *Lancet*. 2014;383:1921-1932.
- Kim HR, Jung S-H, Park JJ, et al. Risk analysis of the long-term outcomes of the surgical closure of secundum atrial septal defects. *J Chest Surg*. 2017;50:78-85.
- Lee SH, Shin YR, Kim DY, et al. Clinical significance of right ventricular-pulmonary arterial coupling in patients with tricuspid regurgitation before closure of atrial septal defect. *Front Cardiovasc Med*. 2022;9:896711.
- Iosifescu AG, Popescu A, Iosifescu TA, Timişescu AT, Maximeasa S, Iliescu VA. Surgery for functional tricuspid regurgitation in adult atrial septal defect - an increasing subject in a decreasing matter. *Braz J Cardiovasc Surg*. 2022;37:306-314.

**Key Words:** atrial septal defect, robotic surgery, right atriotomy, interatrial groove





**FIGURE E1.** Intraoperative image with right atriotomy incision lines. The *white dashed line* represents the conventional oblique incision, and the *yellow dashed line* represents the vertical right atriotomy group incision. RA, Right atrium; IVC, inferior vena cava; SVC, superior vena cava.